

## 默克尔细胞在多物种中的组织分布

刘霞<sup>1,2</sup>, 汪思怡<sup>3</sup>, 芮晨<sup>3</sup>, 朱丽霖<sup>1</sup>, 陆恒磊<sup>1</sup>, 乔俊文<sup>1</sup>, 盛焯<sup>1</sup>, 孙煦晔<sup>1</sup>,  
姜爱莉<sup>2</sup>, 任进<sup>1</sup>, 肖瑛<sup>3\*</sup>

(1. 中国科学院上海药物研究所 药物安全评价研究中心, 中国上海 201203; 2. 烟台大学 生命科学学院, 中国山东 烟台 264005; 3. 浙江大学医学院附属邵逸夫医院 生物医学研究中心, 中国浙江 杭州 310020)

**摘要:** 环境刺激在野生动物的生存和进化中起了关键作用, 协助感知触觉、温度等的细胞感受器也因此体现了生物多样性。默克尔细胞(Merkel cell, MC)是脊椎动物触觉敏感区重要的感觉细胞。本文采用文献调研和数据统计的方法, 借助 PubMed、ScienceDirect 和中国知网等数据库对默克尔细胞的分布进行了调研。结果显示, 默克尔细胞分布于动物界哺乳纲、两栖纲、鸟纲、爬行纲、圆口纲和辐鳍鱼纲 6 个纲 77 个物种。其中, 默克尔细胞的组织病理研究主要集中在哺乳纲动物, 占比达到 50%, 主要分布在人、猴、大鼠、小鼠、犬、猫、猪以及兔等物种; 其次集中在两栖纲和辐鳍鱼纲动物。在组织脏器官上, 默克尔细胞在 33 个物种的鼻/触须中有分布, 占比达到 40%, 提示鼻和触须是动物尤其是野生动物感知外界机械力刺激的重要部位; 其次, 腭、口周、手脚指掌、唇、舌、背皮、牙龈、四肢、腹皮、眼睛、颊和腮等触觉敏感部位的默克尔细胞在较多种属中有研究。系统地汇总已知物种中触觉敏感细胞默克尔细胞的分布, 研究默克尔细胞在不同物种中的分布规律, 有助于了解环境多样性在生物多样性中的作用。

**关键词:** 生物多样性; 机械力刺激; 默克尔细胞; 组织分布; 表皮

中图分类号: Q952

文献标志码: A

文章编号: 1007-7847(2023)03-0253-14

## Tissue Distribution of Merkel Cells in Various Species

LIU Xia<sup>1,2</sup>, WANG Siyi<sup>3</sup>, RUI Chen<sup>3</sup>, ZHU Lilin<sup>1</sup>, LU Henglei<sup>1</sup>, QIAO Junwen<sup>1</sup>,  
SHENG Hua<sup>1</sup>, SUN Xuye<sup>1</sup>, JIANG Aili<sup>2</sup>, REN Jin<sup>1</sup>, XIAO Ying<sup>3\*</sup>

(1. Centre for Drug Safety Evaluation and Research, Shanghai Institute of Materia Medica, Chinese Academy of Sciences, Shanghai 201203, China; 2. College of Life Sciences, Yantai University, Yantai 264005, Shandong, China; 3. Biomedical Research Center, Sir Run Run Shaw Hospital, School of Medicine, Zhejiang University, Hangzhou 310020, Zhejiang, China)

**Abstract:** Environmental stimuli play a key role in the survival and evolution of wild animals. Cell receptors that assist in perception, including touch and temperature, reflect biodiversity. Merkel cells (MCs) are important sensory cells in touch-sensitive areas of vertebrates. Herein, literature research and data statistics were used to investigate the distribution of MCs with the help of PubMed, ScienceDirect and China National Knowledge Infrastructure (CNKI). The results showed that MCs had been observed in 77 species within 6 animal classes including Mammalia, Amphibia, Aves, Reptilia, Cyclostomata and Actinopteri. The histopathological studies of MCs mainly focused on Mammalia, which accounted for 50% and mainly included human, monkey, rat, mouse, dog, cat, pig and rabbit, then followed by Amphibia and Actinopteri. In tissues and organs, MCs were found to be distributed in nose/vibrissae in 33 species, which accounted for 40%, suggesting that the nose and vibrissae are important parts for animals, especially wild animals, to perceive external mecha-

收稿日期: 2022-06-24; 修回日期: 2022-09-23; 网络首发日期: 2023-05-18

基金项目: 国家自然科学基金资助项目(32070816)

作者简介: 刘霞(1992—), 女, 山东淄博人, 硕士研究生, 主要从事生物与医药研究; \*通信作者: 肖瑛(1981—), 女, 湖南沅江人, 特聘研究员, 主要从事干细胞命运决定机制研究, Tel: 0571-86006336, E-mail: xiaoying.srr@zju.edu.cn。

nical stimuli. MCs were also studied in palate, perioral area, fingers/palms of hands/feet, lip, tongue, dorsal skin, gingiva, limbs, abdomen skin, eyes, cheeks, gills and other touch-sensitive sites of many species. Systematically summarizing the distribution of MCs found in known species and studying the distribution of MCs in different species would be helpful to understand the role of environmental diversity in biodiversity.

**Key words:** biodiversity; mechanical stimulation; Merkel cell; tissue distribution; epidermis

(*Life Science Research*, 2023, 27(3): 253–266)

机械感觉,如嗅觉、味觉、听觉、视觉、触觉,对野生动物的生存至关重要,这些感觉系统在进食、交流和定向方面起着重要作用<sup>[1]</sup>。触觉在野生动物生存中起到的作用虽然研究较少,但不可忽视。在个别种属中,一些特殊的触觉感受器可能和其生存环境有密切联系。例如:哺乳动物单孔目鸭嘴兽和针鼹喙上有一种独特类型的推杆机械感受器(push-rod mechanoreceptor),其对动物在浑浊的水中或土壤根系中寻找食物具有重要作用<sup>[2-3]</sup>;爬行类动物鳄鱼可以在夜间有效地捕猎,这主要依赖于其皮肤上圆顶状结构——表皮感觉器官(integumentary sensory organ, ISO),该结构在捕获猎物的过程中起到检测水的振动,以及分析被捕猎物的作用<sup>[4]</sup>。此外,鸟类的喙在精密的触觉辨别等方面发挥重要作用。这些均表明触觉在野生动物的生存过程中起到不可或缺的作用。

现有文献报道,大多数脊椎动物皮肤的表皮中存在默克尔细胞(Merkel cell, MC)-神经复合物,其主要分布在触须或触觉敏感区域,包括有毛和无毛区,主要发挥感知触觉的作用<sup>[5]</sup>。默克尔细胞在脊椎动物中广泛存在,可能是野生动物为了在竞争激烈的食物链中生存而做出的进化上的选择。不同物种进化形成的不同的特殊触觉感受器,与生物在进化过程中呈现的生物多样性特点相契合。

默克尔细胞是一种具有神经内分泌特征的轻触觉细胞,其主要功能是在受到外界机械力刺激后释放各种神经递质,并将机械力刺激转化为电化学信号,从而介导敏感的触觉<sup>[6-7]</sup>。默克尔细胞在电子显微镜下呈椭圆形,有致密的核心颗粒、质膜棘突和树突以及松散排列的细胞骨架,通过桥粒或半桥粒和周围的角质形成细胞相连接,形成一个独立于其他皮肤角质形成细胞的触觉穹窿(touch dome, TD)的皮肤结构<sup>[8-9]</sup>。1995年, Moll 团队在人类、猪和小鼠的皮肤中发现,细胞角蛋白 20 (cytokeratin 20, CK20)可作为一种默克尔细胞特殊的分子标记<sup>[10]</sup>,并于 1996 年使用细胞角蛋白

8 (cytokeratin 8, CK8)、细胞角蛋白 18 (cytokeratin 18, CK18)和细胞角蛋白 20 在小鼠胡须须垫、背部和足垫皮肤中均检测到了该细胞<sup>[11]</sup>。由此可见,动物机体接受机械力感知触觉信号的区域往往存在一定密度的默克尔细胞。目前,针对默克尔细胞的分布研究发现,其主要以不同密度分布于各种无毛和有毛皮肤<sup>[12-13]</sup>。尽管有大量的文献分别报道了其在不同种群中的分布情况,然而系统性地分析默克尔细胞在不同物种不同组织器官中的分布研究尚未见报道,本文对默克尔细胞在多物种的组织分布特征进行综述,并对其分布特征与物种环境生存压力之间的关系进行探讨。

## 1 默克尔细胞在动物组织上的分布

### 1.1 默克尔细胞在哺乳纲动物组织上的分布

哺乳纲(Mammalia)中,默克尔细胞广泛分布于啮齿目(Rodentia)、灵长目(Primates)、食肉目(Carnivora)、翼手目(Chiroptera)、偶蹄目(Artiodactyla)、奇蹄目(Perissodactyla)、负鼠目(Didelphimorphia)、真盲缺目(Eulipotyphla)、兔形目(Lagomorpha)、双门齿目(Diprotodontia)、袋狸目(Peramelemorphia)、袋鼬目(Dasyuromorphia)和单孔目(Monotremata)动物。

啮齿目中,小鼠(*Mus musculus*)头部触须、鼻、腭、唇和颊部,躯干上的背皮和腹皮,后肢/小腿和脚垫均存在默克尔细胞,其主要分布在毛囊外根鞘、表皮基底层、表皮嵴(epithelial ridge)、表皮钉(epithelial peg)或触觉穹窿处。对于小鼠触须,默克尔细胞首次出现在胚胎期 12 天(E12),在 E12~E17,其主要分布在毛囊外根鞘或表皮基底层<sup>[14-17]</sup>。新生和成年小鼠触须的默克尔细胞有相似的分布<sup>[11, 16, 18-19]</sup>。小鼠鼻、唇、颊部和小腿中的默克尔细胞存在于毛囊<sup>[11, 20-21]</sup>。在口腔部位,默克尔细胞主要存在于腭皱襞表皮嵴/表皮钉,且不同部位密度不同:前四皱襞顶部的默克尔细胞丰富,后四皱襞中则较少且主要位于皱襞基底部<sup>[22-24]</sup>。在背皮,人们在 E15 时期首次检测到受神经支配的默克尔细胞,其分布在毛发形成处;在 E16~E17,默克

尔细胞分布在表皮基层;到了 E17~E19,默克尔细胞开始作为构成触觉穹窿的一部分逐渐发育成熟<sup>[14, 16, 25]</sup>。在出生后第1天(P1)、P22~P25 幼年和成年小鼠背皮中,人们均可检测到默克尔细胞,其中,新生和成年小鼠背皮上的默克尔细胞分布在表皮基层<sup>[11, 16, 26]</sup>。此外,成年小鼠腹皮的表皮基层和后肢皮肤的触觉穹窿处也均有默克尔细胞的分布<sup>[11, 27]</sup>。至于脚垫,默克尔细胞首次被检测到的时间为 E15.5; E17 胚鼠和 P1 小鼠脚垫的表皮基层存在默克尔细胞;在成年小鼠中,默克尔细胞分布于表皮嵴顶端<sup>[11, 16, 28]</sup>。

与小鼠相比,大鼠(*Rattus norvegicus* f. *domestica*)中的默克尔细胞还分布在眼睑、耳、牙龈、颈部、尾和趾垫,且其分布特征与小鼠类似。大鼠胡须中的默克尔细胞首次出现在 E15,新生和成年大鼠须部也存在默克尔细胞,其主要分布在毛囊外根鞘<sup>[29-32]</sup>。在 P7 新生大鼠眼睑和耳部表皮中,默克尔细胞呈环簇状分布<sup>[33]</sup>。新生和成年大鼠的鼻部表皮以及 E15 胚鼠的牙龈表皮均有默克尔细胞的分布<sup>[33-35]</sup>。对于口腔部位,人们在 E16 时可检测到腭皱襞分布有少量的默克尔细胞,到 E20 时组织嵴变得突出,在顶端可见更多的默克尔细胞;在新生大鼠中,默克尔细胞分布于腭皱襞表皮基层;在成年大鼠中,默克尔细胞复合体成簇分布在表皮乳头深层部位<sup>[36-37]</sup>。此外,唇和颊部表皮、颈窝毛囊和尾巴毛囊隆起区域也均有默克尔细胞的分布<sup>[36, 38-40]</sup>。在背皮中,默克尔细胞首次出现在 E18;新生和成年大鼠的背皮和腹皮的触觉穹窿部位均存在默克尔细胞;同时,默克尔细胞也分布在 E20~E21 胚鼠腹皮的触觉穹窿处<sup>[33, 41-43]</sup>。在大鼠后肢、脚垫和趾垫,人们均检测到了默克尔细胞,且其主要分布在大鼠脚垫以及 E20 胚鼠、P2~P14 新生和成年大鼠趾垫的表皮基层<sup>[44-46]</sup>。

默克尔细胞除了分布于小鼠和大鼠,也分布于啮齿目其他物种。沙鼠(*Gerbillinae*)触须窦毛囊、2~12 月龄长爪沙鼠(*Meriones unguiculatus*)和成年沙鼠硬腭皱襞表皮嵴/表皮钉等部位均存在默克尔细胞,且 4~12 月龄长爪沙鼠腭的前后皱襞的默克尔细胞密度不同,后皱襞有更多的默克尔细胞,这一结果与小鼠中的情况相反<sup>[47-50]</sup>。成年仓鼠(*Cricetidae*)触须环状窦毛囊和仓鼠腭表皮均分布有默克尔细胞;8 周叙利亚仓鼠(*Mesocricetus auratus*)腭表皮基层也存在默克尔细胞,且其集中分布在褶皱顶部<sup>[39, 48, 51]</sup>。此外, P15~P21 新生、成

年叙利亚仓鼠的颊黏膜处也存在默克尔细胞,且其主要分布于触觉穹窿处<sup>[51-52]</sup>。豚鼠(*Cavia porcellus*)触须毛囊隆起区域存在丰富的默克尔细胞,但在其口周、背皮和腹皮的毛囊中,默克尔细胞较少存在或不存在。此外,豚鼠的乳头表皮下有大量的默克尔细胞;在肛门周围,默克尔细胞仅分布于距肛门 1 cm 内的毛囊隆起区域,且距离肛门越远,数量越少;豚鼠脚垫部位也存在大量的默克尔细胞,且其分布于小汗腺部位<sup>[38]</sup>。

与啮齿目类似,默克尔细胞也分布在灵长目动物全身多个组织,其主要分布在毛囊或表皮,尤其在表皮嵴/表皮钉有分布。默克尔细胞在恒河猴(*Macaca mulatta*)、食蟹猕猴(*Macaca fascicularis*)和日本猕猴(*Macaca fuscata*)中均有分布。在恒河猴眼睑中,默克尔细胞分布于表皮钉基层或毛囊外根鞘<sup>[5, 53]</sup>。在食蟹猕猴眼睑中,人们仅在表皮嵴底部发现了默克尔细胞。在恒河猴和食蟹猕猴睫毛上,默克尔细胞分布于粗毛毛囊处;同时,其鼻、上下唇和前腿窦毛囊处也存在默克尔细胞<sup>[54]</sup>。在恒河猴和食蟹猕猴牙龈黏膜上,单个或成簇的默克尔细胞分布于表皮嵴底部<sup>[55]</sup>。另外,恒河猴齿乳头黏膜和手指垫表皮基层分布有默克尔细胞<sup>[5, 56]</sup>;恒河猴腭、日本猕猴和食蟹猕猴舌的表皮钉底部均存在默克尔细胞<sup>[57-58]</sup>;恒河猴唇表皮嵴以及猕猴(*Macaca*)的唇和颊表皮处也存在默克尔细胞<sup>[21, 59]</sup>。相关文献报道,在食蟹猕猴手指垫上,默克尔细胞分布在表皮嵴,且其分布存在个体和组织区域多样性,例如:小指上的默克尔细胞平均密度最小(61.2 个/mm<sup>2</sup>),中指上的密度最大(103.5 个/mm<sup>2</sup>)<sup>[60]</sup>。此外,在成年松鼠猴(*Saimiri sciureus*)腭中,默克尔细胞成簇分布于表皮钉基层底部<sup>[61]</sup>;绒毛猴(*Lagothrix*)尾巴表皮处也存在默克尔细胞<sup>[62]</sup>。

食肉目中,默克尔细胞同样分布于全身组织。在犬(*Canis lupus familiaris*)的有毛皮肤中,包括须部、前额、上下眼睑、鼻口、耳廓内外表面、颈背侧和腹侧、体侧皮肤以及背皮和腹皮,默克尔细胞主要分布于表皮和毛囊;而在无毛皮肤部位,比如鼻垫、人中、脚垫和趾垫、鼻前庭、牙龈、舌、唇、颊黏膜,以及阴道、阴茎包皮、肛门黏膜的表皮嵴/表皮钉或基层,默克尔细胞均有分布<sup>[63]</sup>。在藏狼(*Canis lupus* var. *chanco*)和赤狐(*Vulpes vulpes*)的鼻口部位,默克尔细胞主要分布于窦毛囊外根鞘<sup>[64]</sup>。成年猫(*Felis catus*)眼眶下的窦毛囊、触须

的毛囊外根鞘或表皮嵴基层均存在默克尔细胞<sup>[65-67]</sup>。猫鼻部的默克尔细胞分布于表皮基层、窦毛囊或真皮层<sup>[5, 68-69]</sup>。猫牙龈和腭表皮钉的基底部以及颊黏膜、唇无毛皮肤的表皮钉和触觉穹窿处均分布有默克尔细胞<sup>[65, 70-71]</sup>。在猫肩部、大腿以及爪的有毛和无毛区域,默克尔细胞均分布于触觉穹窿处<sup>[72-75]</sup>。此外,人们发现,在新生和成年雪貂(*Mustela putorius furo*)以及加州海狮(*Zalophus californianus*)的触须外根鞘处,默克尔细胞也有分布<sup>[76-77]</sup>;浣熊(*Procyon lotor*)趾背和趾垫的表皮嵴/表皮钉处分布有大量的默克尔细胞<sup>[78-79]</sup>。

与啮齿目、灵长目和食肉目类似,翼手目中,默克尔细胞也广泛分布在全身组织。比如:巴西犬吻蝠(*Tadarida brasiliensis*)的鼻口毛囊外根鞘处存在默克尔细胞<sup>[64]</sup>;成年大足鼠耳蝠(*Myotis riccetti*)的背皮、腹皮、脚垫和腿间膜的表皮基层部与毛囊上均存在默克尔细胞,翼膜触觉穹窿处也存在该细胞<sup>[80]</sup>。此外,大棕蝠(*Eptesicus serotinus*)的翼前缘以及趾骨和趾膜的有毛皮肤部位也均分布有默克尔细胞<sup>[81]</sup>。

偶蹄目中,默克尔细胞分布在头部或躯干。猪(*Suidae*)触须外根鞘处存在默克尔细胞;对于眼睑,默克尔细胞成簇分布于猪胚胎表皮基层;在成年猪睫毛上,少量的默克尔细胞聚集在毛囊处<sup>[82]</sup>。在胚胎期和成年猪的鼻中,默克尔细胞分布于表皮锥(epidermal cone)底部或毛囊外根鞘<sup>[82-83]</sup>。成年猪牙龈、新生和成年猪腭黏膜以及成年猪颊黏膜处也有默克尔细胞的分布<sup>[71, 73]</sup>。另外,默克尔细胞也分布于猪的唇表皮嵴<sup>[73]</sup>。牛(*Bovidae*)的腭黏膜中也存在默克尔细胞<sup>[50]</sup>。家山羊(*Capra aegagrus var. hircus*)腭部切牙乳头中的默克尔细胞成簇分布于表皮钉基层<sup>[84]</sup>。绵羊(*Ovis aries*)唇中的默克尔细胞出现在表皮基层部,偶尔出现在真皮层,并且 E57~E144 的绵羊身体侧中段区域的表皮基层部也有默克尔细胞的分布<sup>[85-86]</sup>。此外,在成年条纹原海豚(*Stenella coeruleoalba*)背皮中,成簇的默克尔细胞分布于表皮嵴底部<sup>[87]</sup>。

奇蹄目中,默克尔细胞分布在 4~7 龄家马(*Equus ferus caballus*)前足上的表皮和真皮交界处<sup>[88]</sup>。

负鼠目的头部和爪部存在默克尔细胞。在成年短尾负鼠(*Monodelphis domestica*)的耳前庭、牙龈以及成年北美负鼠(*Didelphis virginiana*)的鼻无毛区域,默克尔细胞均分布于各组织的表皮钉底

部<sup>[89-90]</sup>。此外,负鼠(*Didelphidae*)鼻窦毛囊上部的外根鞘以及幼年北美负鼠前爪掌的表皮也存在默克尔细胞<sup>[69, 91]</sup>。

真盲缺目、兔形目和双门齿目中,默克尔细胞均在头部组织被检测到。在真盲缺目中,长爪鼯鼠(*Sorex unguiculatus*)的鼻窦毛囊外根鞘、成年臭鼯(*Suncus murinus*)的牙龈黏膜上缘和牙间乳头以及臭鼯的腭表皮钉部位均有默克尔细胞的分布<sup>[23, 92-93]</sup>;美洲鼯(*Scalopus aquaticus*)、星鼻鼯(*Condylura cristata*)和毛尾鼯(*Parascalops breweri*)鼻部的默克尔细胞分布于其特有的艾默氏器(Eimer's organ)的表皮基层部<sup>[94]</sup>。在兔(*Leporidae*)触须上,默克尔细胞分布于环状窦毛囊;而在腭上,默克尔细胞则成簇分布于表皮钉基层;幼年和成年兔唇的表皮嵴处也存在默克尔细胞<sup>[48, 95-96]</sup>。在双门齿目帚尾袋貂(*Trichosurus vulpecula*)的触须中,表皮外根鞘基层的每个窦毛囊存在 800~1 200 个默克尔细胞<sup>[97]</sup>。新生帚尾袋貂的口部表皮以及袋鼠(*Macropus*)的腭表皮也均存在默克尔细胞<sup>[98-99]</sup>。此外,宽脸长鼻袋狸(*Potorous platypus*)唇部的默克尔细胞分布于粗毛外根鞘基层<sup>[97]</sup>。

袋狸目、袋鼯目和单孔目中,默克尔细胞集中分布在鼻口部位。袋狸目成年短鼻袋狸(*Isoodon macrourus*)鼻部无毛区域的表皮钉基层部、新生北部棕色袋狸的口表皮以及袋鼯目成年鬃尾袋鼯(*Dasyuroides byrnei*)口鼻区的毛囊部位均存在默克尔细胞<sup>[54, 89, 98]</sup>。另外,在单孔目澳洲针鼯(*Tachyglossus aculeatus*)的鼻和喙部,以及鸭嘴兽(*Ornithorhynchus anatinus*)上下喙中,默克尔细胞分布于推杆机械感受器<sup>[81, 100-101]</sup>。

## 1.2 默克尔细胞在两栖纲动物组织上的分布

默克尔细胞分布于两栖纲(*Amphibia*)的有尾目(*Urodela*)和无尾目(*Anura*)。与哺乳纲类似,其在全身各组织均有分布。

无尾目中,默克尔细胞主要分布于表皮、味觉器官基部或腺体附近。非洲爪蟾(*Xenopus laevis*)幼体蝌蚪触须中的默克尔细胞分布于表皮浅层或浅层和基层之间<sup>[102-103]</sup>。同时,非洲爪蟾的尾巴、幼体蝌蚪的足表皮、成年非洲爪蟾的后肢皮肤以及幼体背皮、脚趾腺体附近均存在默克尔细胞<sup>[104-107]</sup>。美国牛蛙[*Rana (Lithobates) catesbeiana*]、林蛙(*Rana temporaria*)和黑斑侧褶蛙(*Pelodytes nigromaculatus*)的味觉器官基层部均有默克尔细胞的分布<sup>[108-110]</sup>。黑斑侧褶蛙幼体蝌蚪牙齿的

角质齿嵴处也存在默克尔细胞<sup>[39]</sup>。日本林蛙(*Rana japonica*)胚胎和幼体唇中的表皮嵴底部存在默克尔细胞<sup>[111-112]</sup>。美国牛蛙和林蛙的背皮以及豹蛙 [*Rana (Pantherana) pipiens*] 的背皮和腹皮也均有默克尔细胞的分布<sup>[106, 113-114]</sup>。在有疣美国牛蛙后肢皮肤上, 默克尔细胞沿着腺管和疣子分布<sup>[115]</sup>。此外, 成年欧洲树蛙(*Hyla arborea*)背皮和腹皮的表皮以及大蟾蜍(*Bufo bufo*)腹皮的表皮基底层上层均存在默克尔细胞<sup>[116-117]</sup>; 默克尔细胞也存在于无尾目蝌蚪的唇表皮嵴<sup>[50]</sup>。

有尾目中, 斑泥鳅(*Necturus maculosus*)舌的味蕾基底部存在默克尔细胞<sup>[118]</sup>; 美西鳅(*Ambystoma mexicanum*)幼体舌的表皮以及成年虎纹钝口鳅(*Ambystoma tigrinum*)后肢背皮的表皮基底层有默克尔细胞的分布<sup>[33, 119]</sup>。斑点钝口鳅(*Ambystoma maculatum*)幼体前肢趾中的默克尔细胞孤立存在, 且在表皮分布非常稀疏<sup>[120]</sup>。

### 1.3 默克尔细胞在鸟纲动物组织上的分布

鸟纲(Aves)的鸡形目(Galliformes)、雀形目(Passeriformes)和雁形目(Anseriformes)动物存在默克尔细胞, 其主要分布在头部或四肢皮肤的真皮层、表皮下或表皮内。

鸡形目中, 鸡(*Gallus gallus domesticus*)髯部真皮层、表皮下或表皮内均存在默克尔细胞, 其中, 多达 30 个默克尔细胞小体排布在真皮层, 单个的默克尔细胞分布于默克尔细胞小体和表皮基底层之间<sup>[121-122]</sup>。在成年日本鹌鹑(*Coturnix japonica*)喙中, 成簇的默克尔细胞分布于真皮层, 其中表皮锥之间或下面区域的真皮层存在多达 50 个默克尔细胞<sup>[123]</sup>。人们在成年日本鹌鹑舌的背表皮下检测到默克尔细胞小体呈单个或成簇分布在结缔组织, 默克尔细胞小体位于靠近乳头状突起的顶端, 且舌侧缘区域存在大量的默克尔细胞小体, 每个默克尔细胞小体由 4~8 个默克尔细胞组成<sup>[124]</sup>。成年日本鹌鹑跗跖皮肤的默克尔细胞成簇分布于组织的真皮层浅层<sup>[125]</sup>。

另外, 成年雀形目家麻雀(*Passer domesticus*)和成年雁形目鸭(Anatidae)的默克尔细胞分布于舌背表皮下的结缔组织<sup>[126-127]</sup>。

### 1.4 默克尔细胞在爬行纲动物组织上的分布

默克尔细胞存在于爬行纲(Reptilia)鳄目(Crocodylia)、龟鳖目(Testudines)和有鳞目(Squamata)动物全身的大部分组织。在鳄目中, 幼年美国短吻鳄(*Alligator mississippiensis*)的颅骨区(包括眼睛下

区域、鼻孔周围、上颌骨和下颌)、口腔(包括牙齿周围、牙龈和上腭), 以及幼年尼罗鳄(*Crocodylus niloticus*)的颅骨区(包括鼻孔周围、上颌骨和下颌)、口腔(包括牙齿周围)、鳄鱼皮(包括身体表面鳞片和头部鳞片表皮感觉器官的真皮层)等部位均存在默克尔细胞复合体<sup>[4]</sup>。另外, 在眼镜凯门鳄(*Caiman crocodilus*)中, 默克尔细胞分布于含味蕾结构的舌表皮下结缔组织<sup>[128]</sup>。在龟鳖目中, 日本拟水龟(*Clemmys japonica*)含味蕾结构的舌部位同样存在默克尔细胞, 其仅分布于靠近味蕾处的表皮基底部<sup>[129]</sup>。在有鳞目胎生蜥蜴(*Lacerta vivipara*)的唇中, 2~4 个默克尔细胞经常成簇出现在表皮钉基底部<sup>[130]</sup>。

### 1.5 默克尔细胞在圆口纲动物组织上的分布

默克尔细胞在圆口纲(Cyclostomata)两个物种上被检测到, 其分布在成年欧洲七鳃鳗(*Lampetra fluviatilis*)和泼氏七鳃鳗(*Lampetra planeri*)的背腹侧头部、鼻孔附近、口盘边缘、侧身体皮肤、背鳍和尾鳍, 以及泼氏七鳃鳗幼体口盘边缘、腮和鳍处不同层次的表皮中, 且从基底层细胞(虽然不与基膜接触)到表皮第 2 层细胞均存在默克尔细胞<sup>[131]</sup>。

### 1.6 默克尔细胞在辐鳍鱼纲动物组织上的分布

辐鳍鱼纲(Actinopteri)的鲇形目(Siluriformes)、鲤形目(Cypriniformes)、鳗鲡目(Anguilliformes)、骨舌鱼目(Osteoglossiformes)、鲑形目(Gadiformes)和鲈形目(Carangiformes)动物均存在默克尔细胞, 其主要分布于头部或躯干皮肤的表皮、味蕾基底部或推杆机械感受器。

在鲇形目中, 黑鲶(*Ameiurus melas*)的触须、身体侧面皮肤的表皮, 以及印度囊鳃鲇(*Heteropneustes fossilis*)的头部皮肤均有默克尔细胞的分布<sup>[106, 132]</sup>。在鲤形目中, 鲤鱼(*Cyprinus rubrofasciatus*)的触须、金鱼(*Carassius auratus auratus*)的头部皮肤、斑马鱼(*Danio rerio*)的触须背腹侧、真鲷(*Phoxinus phoxinus*)唇和腮瓣的表皮均存在默克尔细胞<sup>[50, 106, 133-134]</sup>。在口咽部, 默克尔细胞分布于鲤鱼味蕾基底部, 在斑马鱼幼体腮中也可见, 其广泛分布于口咽表皮, 并从口腔延伸至鳃弓和鳃耙; 成年斑马鱼腮的味蕾基底层存在默克尔细胞, 1 个味蕾分布有许多的默克尔细胞和味觉受体细胞<sup>[132, 134]</sup>。此外, 鳗鲡目欧洲鳗鲡(*Anguilla anguilla*)的鼻部和康吉鳗(*Conger*)的唇及背皮、骨舌鱼目弓背鱼(*Notopterus notopterus*)的腮部、鲑形目鼬五须岩鲑(*Ciliata mustela*)鳍的表皮, 均有默克尔细胞的分布<sup>[132-133, 135]</sup>。鲈

形目鮟(Echeneis naucrates)和短鮟(Remora remora)吸盘中的默克尔细胞成簇分布于推杆机械感受器的底部<sup>[136]</sup>。

## 2 默克尔细胞在人组织上的分布

灵长目(Primates)人(*Homo sapiens*)的头部皮肤(包括口腔内黏膜层)是默克尔细胞分布丰富的区域。在早期胎儿头皮毛囊中,默克尔细胞仅存在于发育中的漏斗部(infundibulum),而未出现在更深的毛囊区域,随着胎儿年龄增长,其出现在峡部和隆起部位,而未在发育的毛囊周围真皮区出现。同时,默克尔细胞也存在于胎儿头皮的小汗腺中<sup>[137]</sup>。成人头皮的表皮基底层存在默克尔细胞,其呈带状分布于毛囊的漏斗深部和峡部。研究者在毛囊的球部和真皮层未观察到默克尔细胞<sup>[138-139]</sup>。成人眼睑皮肤中的默克尔细胞以穿过神经髓鞘延伸到真皮的形式存在,老年人眼睑中的默克尔细胞总体出现率较低,其主要分布于中央纤毛的外根鞘<sup>[5, 140]</sup>。口腔中的默克尔细胞主要见于唇黏膜、舌下黏膜、牙龈、硬腭、颊黏膜的表皮基底层,形态主要为椭圆形或树突状,呈单层或簇状分布,穿插于角质形成细胞间<sup>[13, 141-142]</sup>。据统计,牙龈和颊黏膜中的默克尔细胞密度最高,上腭次之,唇黏膜最少<sup>[143]</sup>。面部绒毛毛囊隆起区域的默克尔细胞最丰富,其他部位默克尔细胞较少<sup>[144]</sup>。隆起区存在两种类型的默克尔细胞:一种是与神经末梢无接触的默克尔细胞,可能处于未分化(未成熟)的阶段;另一种是与神经纤维相连接的默克尔细胞,可能是已分化(成熟)的状态<sup>[145]</sup>。除了毛囊,脸颊的表皮基底层也有默克尔细胞的分布<sup>[141]</sup>。人们还发现,默克尔细胞在额头、鼻子、耳朵、颈部的表皮基底层有分布<sup>[146]</sup>。

躯干和四肢的皮肤也是默克尔细胞集中分布的区域。胎儿和成人乳房的表皮基底层存在默克尔细胞,胎儿中出现的概率大于成人,并随着年龄的增加而减少。在成人阶段,有极少数的默克尔细胞分布于表皮的基底层,呈典型的环状<sup>[147-148]</sup>。成人胸部和背部皮肤的表皮基底层存在默克尔细胞,其呈圆形或椭圆形不规则分布<sup>[149]</sup>。另外,脐带的真皮-表皮交界处有明显的默克尔细胞-神经复合体,每个默克尔细胞的底部都有一个半月板状神经末梢,充满线粒体和糖原<sup>[150]</sup>。作为触觉穹窿组成之一的默克尔细胞,其聚集在手臂和腹部的表皮基底层,其中前臂密度高于腹部,但腹部

单个触觉穹窿的细胞数量比前臂多<sup>[149, 151]</sup>。成人腰部皮肤的基底层也存在很多分布于触觉穹窿的默克尔细胞<sup>[152]</sup>。此外,默克尔细胞也存在于指甲、指腹、掌侧、掌心、手背的表皮基底层。其最早在胎儿7周时的掌侧表皮基底层出现,无明显形态且无规则分布于真表皮;在19周左右呈线性排列,分布于真皮-表皮交界处<sup>[6, 153]</sup>。胎儿9周时,指甲原基部位出现聚集的默克尔细胞;12~15周时,大量的默克尔细胞在指甲原基内可见,尤其是在近端甲褶的表皮以及尖区的背侧和腹侧;相反,腹侧基质近表面部分、新月和甲床的表皮不存在默克尔细胞。从胎儿期发育开始到成年期,指甲中默克尔细胞的数量几乎是持续减少的<sup>[154]</sup>。在足背与足底中,默克尔细胞最早在胎儿第8周出现,位于足底表皮基底层以上,并开始增殖<sup>[155-156]</sup>。在15周时,其散布于基底层,可以到达真皮-表皮交界处,有部分在真皮层<sup>[157-158]</sup>。在19周时,真皮默克尔细胞数量达到峰值<sup>[159]</sup>。23周时,真皮中的默克尔细胞开始消失<sup>[160]</sup>。表皮基底层默克尔细胞的胞体呈圆形或椭圆形,并通常伴有细长、分叉的细胞突起,而真皮默克尔细胞的形状以圆形为主<sup>[157]</sup>。除了上述提及的组织外,默克尔细胞在腋窝、臀部、大腿和膝盖的表皮基底层也有分布,只是数量相对较少<sup>[146]</sup>。

另外,人体内部感受触觉/压力的表皮部分以及生殖器表皮也有默克尔细胞的聚集。人食道中的默克尔细胞首次被发现于1999年,这些细胞在新生儿食道中未被发现,在成人标本中沿着表皮基底层以单个或成簇的方式存在,其中食管中段的默克尔细胞数量较多<sup>[161]</sup>。默克尔细胞在人的阴道中有存在,以单个细胞的状态分布于表皮层,还有少数分布于结缔组织<sup>[12]</sup>。在男性生殖器部位,阴囊、包皮的表皮基底层和阴茎真皮有默克尔细胞的存在<sup>[146, 162-163]</sup>。

## 3 总结和讨论

根据目前已有研究数据统计,默克尔细胞分布于动物界脊索动物门哺乳纲、两栖纲、鸟纲、爬行纲、圆口纲、辐鳍鱼纲6个纲77个物种(表1)。其中,哺乳纲中的动物最多,为42个(图1),占比达到了50%,主要有小鼠、大鼠、恒河猴、食蟹猕猴、人、犬、猫、猪、兔等;其次是两栖纲、辐鳍鱼纲,主要有非洲爪蟾、美国牛蛙、林蛙、黑斑侧褶蛙、斑泥鳅、美西鳅、黑鲟、印度囊鳃鲈、鲤鱼、斑马鱼等;

鸟纲和爬行纲的动物主要有鸡、日本鹌鹑、美国短吻鳄、尼罗鳄、日本拟水龟等。而在圆口纲中,默克尔细胞仅在泼氏七鳃鳗和欧洲七鳃鳗两个物种有分布。以上统计结果显示,当前默克尔细胞研究所用的动物材料来源广泛,遍及脊椎动物多个纲,包括较低等的单孔目针鼹鼠和鸭嘴兽。其中,研究较多的是哺乳纲中的小鼠和大鼠,可能是因为它们属于实验模式动物,且具有易于繁殖、培养成本低等优点。统计结果同时也表明,默克尔

细胞广泛分布于不同种属上,推测默克尔细胞在不同物种中的分布具有一定的共性,其在进化上是保守且广泛分布的。默克尔细胞在哺乳纲动物中分布最多,可能是因为哺乳纲动物作为最常见的实验材料被广泛用于科学研究;而在圆口纲中分布最少,可能是由于当时技术水平受限未被检测到,或者是由于动物组织样本难以获得等外部因素而未被研究。

另外,组织脏器上的对比研究显示,鼻/触须

表1 默克尔细胞在各物种及其全身分布的汇总表  
Table 1 Distribution of MCs in animal species and their whole bodies

Serial No.	Species	Tissue/organ containing MCs
<b>Chordata, Mammalia</b>		
<b>Primates</b>		
1	<i>Homo sapiens</i>	Scalp-forehead-eyelid-nose-ear-gingiva-palate-tongue-lip-face-cheek-neck-swallow-chest/breast-dorsal skin-axillae-upper arm-abdomen skin-umbilical skin-waist-scrotum-foreskin-vagina-penis-buttocks-opisthenar/palm-finger pulp-nail-thigh-knee-instep/pelma
2	<i>Macaca mulatta</i>	Eyelid-eyelash-nose-gingiva-teeth-palate-upper and lower lip-foreleg-finger pad
3	<i>Macaca fascicularis</i>	Eyelid-eyelash-nose-gingiva-tongue-lip-foreleg-finger pad
4	<i>Macaca fuscata</i>	Tongue
5	<i>Saimiri sciureus</i>	Palate
6	<i>Lagothrix</i>	Tail
<b>Rodentia</b>		
7	<i>Mus musculus</i>	Vibrissae-nose-palate-lip-cheek-dorsal skin-abdomen skin-shank-footpad
8	<i>Rattus norvegicus f. domestica</i>	Eyelid-ear-vibrissae-nose-gingiva-palate-lip-cheek-neck-tail-dorsal skin-abdomen skin-hindlimb-footpad-toe
9	<i>Meriones unguiculatus</i>	Palate
10	<i>Mesocricetus auratus</i>	Palate-cheek
11	<i>Cavia porcellus</i>	Vibrissae-perioral-dorsal skin-abdomen skin-nipple-perianus-footpad
<b>Carnivora</b>		
12	<i>Canis lupus familiaris</i>	Forehead-upper/lower eyelid-vibrissae-nose/nasal vestibule/nose pad-muzzle-philtrum-gingiva-palate-tongue-lip-cheek-pinna-neck-flank skin-vagina/prepuce-anal mucosa-dorsal skin-abdomen skin-footpad-digital pad
13	<i>Canis lupus var. chanco</i>	Muzzle
14	<i>Vulpes vulpes</i>	Muzzle
15	<i>Felis catus</i>	Infraorbital site-vibrissae-nose-gingiva-palate-lip-cheek-shoulder-thigh-paw
16	<i>Mustela putorius furo</i>	Vibrissae
17	<i>Zalophus californianus</i>	Vibrissae
18	<i>Procyon lotor</i>	Dorsum of toe-pad of toe
<b>Chiroptera</b>		
19	<i>Tadarida brasiliensis</i>	Muzzle
20	<i>Myotis ricketti</i>	Dorsal skin-wing membrane-abdomen skin-footpad-intercrustral membrane
21	<i>Eptesicus serotinus</i>	Leading edge of wing-phalanx-the hairy skin part of the toe membrane
<b>Artiodactyla</b>		
22	Suidae	Eyelid-eyelash-vibrissae-nose-gingiva-palate-lip-cheek
23	Bovidae	Palate
24	<i>Capra aegagrus var. hircus</i>	Palate with incisiva papilla
25	<i>Ovis aries</i>	Lip-mid lateral region of the body
26	<i>Stenella coeruleoalba</i>	Dorsal skin
<b>Perissodactyla</b>		
27	<i>Equus ferus caballus</i>	Forefoot
<b>Didelphimorphia</b>		
28	<i>Monodelphis domestica</i>	Ear and vestibular site-gingiva
29	<i>Didelphis virginiana</i>	Nose-forepaw
<b>Eulipotyphla</b>		
30	<i>Sorex unguiculatus</i>	Nose

表 1(续)

Serial No.	Species	Tissue/organ containing MCs
31	<i>Suncus murinus</i>	Gingiva-palate-interdental site
32	<i>Scalopus aquaticus</i>	Nose
33	<i>Condylura cristata</i>	Nose
34	<i>Parascalops breweri</i>	Nose
	<b>Lagomorpha</b>	
35	Leporidae	Vibrissae-palate-lip
	<b>Diprotodontia</b>	
36	<i>Trichosurus vulpecula</i>	Vibrissae-mouth
37	<i>Macropus</i>	Palate
38	<i>Potorous platyops</i>	Lip
	<b>Peramelemorphia</b>	
39	<i>Isodon macrourus</i>	Nose
	<b>Dasyuromorphia</b>	
40	<i>Dasyuroides byrnei</i>	Muzzle
	<b>Monotremata</b>	
41	<i>Tachyglossus aculeatus</i>	Nose-beak
42	<i>Ornithorhynchus anatinus</i>	Upper and lower beaks
	<b>Chordata, Amphibia</b>	
	<b>Anura</b>	
43	<i>Xenopus laevis</i>	Vibrissae-tail-dorsal skin-hindlimb-foot-toe
44	<i>Rana (Lithobates) catesbeianus</i>	Tongue-dorsal skin-hindlimb
45	<i>Rana temporaria</i>	Tongue-dorsal skin
46	<i>Pelophylax nigromaculatus</i>	Tongue-teeth
47	<i>Rana japonica</i>	Lip
48	<i>Rana (Pantherana) pipiens</i>	Dorsal skin-abdomen skin
49	<i>Hyla arborea</i>	Dorsal skin-abdomen skin
50	<i>Bufo bufo</i>	Abdomen skin
	<b>Urodela</b>	
51	<i>Necturus maculosus</i>	Tongue
52	<i>Ambystoma mexicanum</i>	Tongue
53	<i>Ambystoma tigrinum</i>	Hindlimb dorsal skin
54	<i>Ambystoma maculatum</i>	Forelimb digits
	<b>Chordata, Aves</b>	
	<b>Galliformes</b>	
55	<i>Gallus gallus domesticus</i>	Palate
56	<i>Coturnix japonica</i>	Beak-tongue-tarsometatarsal skin/toe region
	<b>Passeriformes</b>	
57	<i>Passer domesticus</i>	Tongue
	<b>Anseriformes</b>	
58	Anatidae	Tongue
	<b>Chordata, Reptilia</b>	
	<b>Crocodylia</b>	
59	<i>Alligator mississippiensis</i>	Areas below the eyes, surrounding the nares and around the teeth-maxilla-lower jaw-gingiva-palate
60	<i>Crocodylus niloticus</i>	Areas surrounding the nares and around the teeth-maxilla-lower jaw-scales of the body surface and head
61	<i>Caiman crocodilus</i>	Tongue
	<b>Testudines</b>	
62	<i>Clemmys japonica</i>	Tongue
	<b>Squamata</b>	
63	<i>Lacerta vivipara</i>	Lip
	<b>Chordata, Cyclostomata</b>	
	<b>Petromyzontiformes</b>	
64	<i>Lampetra fluviatilis</i>	Dorsal head-ventral head-near nostril-oral disc-lateral body skin-dorsal fin-caudal fin
65	<i>Lampetra planeri</i>	Dorsal head-ventral head-near nostril-oral disc-gill-lateral body skin-dorsal fin-caudal fin
	<b>Chordata, Actinopteri</b>	
	<b>Siluriformes</b>	
66	<i>Ameiurus melas</i>	Vibrissae-body flank skin
67	<i>Heteropneustes fossilis</i>	Head skin

表 1(续)

Serial No.	Species	Tissue/organ containing MCs
<b>Cypriniformes</b>		
68	<i>Cyprinus rubrofuscus</i>	Vibrissae-oropharyngeal region (gill bars)
69	<i>Carassius auratus auratus</i>	Head skin
70	<i>Danio rerio</i>	Vibrissae-gill
71	<i>Phoxinus phoxinus</i>	Lip-opercular valves
<b>Anguilliformes</b>		
72	<i>Anguilla anguilla</i>	Nose
73	<i>Conger</i>	Lip-dorsal skin
<b>Osteoglossiformes</b>		
74	<i>Notopterus notopterus</i>	Gill
<b>Gadiformes</b>		
75	<i>Ciliata mustela</i>	Fin
<b>Carangiformes</b>		
76	<i>Echeneis naucrates</i>	Adhesive disc
77	<i>Remora remora</i>	Adhesive disc

上有默克尔细胞分布的种属最多, 随后依次为腭、口周、手脚指掌、唇、舌、背皮、牙龈、四肢、腹皮、眼睛、颊和腮等部位(图 2)。

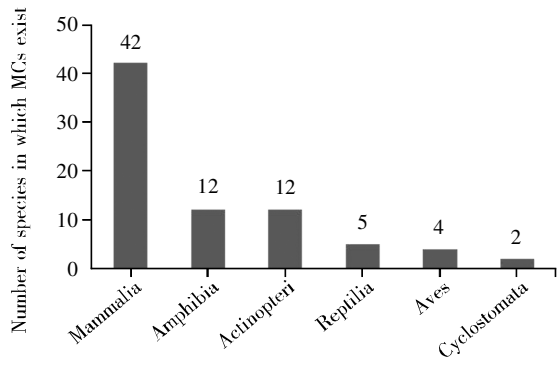


图 1 各类动物中分布有默克尔细胞的物种数量汇总图  
Fig.1 The number of species in which MCs exist in various animals

鼻/触须上的默克尔细胞被研究最多, 其广泛分布于 33 个种属, 物种分布占比达到了 40%, 考

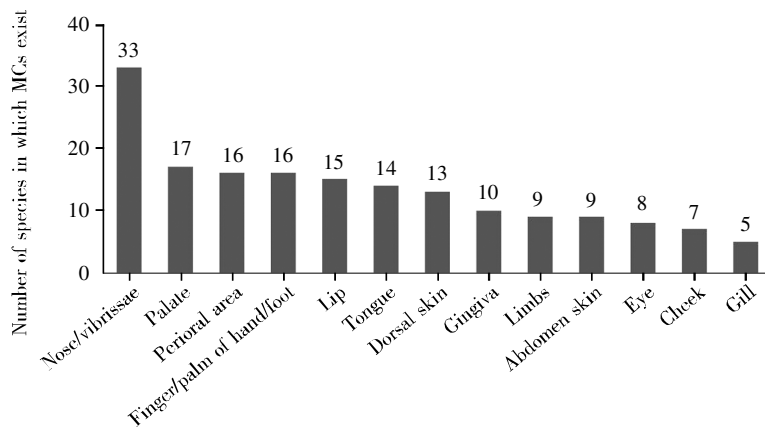


图 2 存在默克尔细胞的脏器组织所在的物种数量汇总图  
Fig.2 The number of species in which MCs exist in various tissues/organs

虑主要有以下两个原因。1) 该部位默克尔细胞分布广泛, 有毛和无毛区域均有分布。其中在有毛区域, 默克尔细胞主要分布在窦毛囊, 且大多分布在隆起区域, 含量较丰富, 该现象目前已在小鼠、大鼠、猫、猪、帚尾袋貂等多个种属中得到证实<sup>[18, 33, 69, 82, 97]</sup>。对于鼻无毛区域, 除了大鼠、猫和猪, 默克尔细胞也在北美负鼠、短鼻袋狸中被检测到<sup>[33, 68, 82, 89]</sup>。鼻部有毛或无毛区域的默克尔细胞广泛地分布在不同种属, 推测在不同种属鼻部存在的默克尔细胞群体可能发挥相同或相似的功能, 它们通过感知外界环境, 对物体、纹理、形状进行判断, 在物种进化上存在一定的共性, 因此, 默克尔细胞也可能存在于未被发现或报道的其他物种的鼻/触须部位。综上所述, 鼻和触须部位是动物尤其是野生动物感知外界机械力刺激的重要部位。另外, 个别研究发现默克尔细胞存在于各发育阶段的动物鼻部, 其在 14 d 胚鼠、1~10 d 新生鼠以及幼年、成年和老年小鼠的鼻窦毛囊处均

有被检测到,而其他组织部位暂没有看到类似的发育学研究<sup>[20]</sup>。这暗示鼻/触须部位可以作为研究默克尔细胞及其相关神经分化、成熟、衰老等工作的首选实验材料。2) 个别物种有包含默克尔细胞的特殊感受器,它们主要或仅存在于鼻部,其中触觉敏感结构艾默氏器仅存在于鼯鼠类动物鼻部<sup>[94]</sup>;推杆机械感受器存在于澳洲针鼹鼻口部位<sup>[101]</sup>。这种鼻部的专一性,增加了种属间鼻部默克尔细胞分布的保守性,也说明了这一部位默克尔细胞存在的必要性。

其他组织部位(包括口腔、背皮/腹皮、四肢/指掌)的默克尔细胞在较多种属中也有研究,这些部位均是触觉敏感部位,与默克尔细胞主要发挥触觉功能保持一致。不过,分布有默克尔细胞的不同部位所涉及物种的数量存在一定的差异。其中,默克尔细胞检测方法的灵敏度是一个不可忽视的影响因素。默克尔细胞作为一种内分泌细胞,其分泌的蛋白质可以作为检测标记物。研究发现,在各年龄段猪口腔中,嗜铬粒蛋白 A (chromogranin A, CG-A)在胚胎和幼年时表达量较高,成年时表达量较少;而降钙素基因相关肽(calcitonin gene-related peptide, CGRP)、P 物质(substance P, SP)、血管活性肠多肽(vasoactive intestinal polypeptide, VIP)和肽组氨酸异亮氨酸(peptide histidine isoleucine, PHI)的表达量正好相反。而且,该研究发现这些分泌蛋白在成年豚鼠中均未表达,而在成年的小鼠、猫中均出现了不同程度的表达。上述结果表明,不同的分泌蛋白在同一物种同一组织不同发育阶段,其表达量不同;而且,同一部位的同一种标记物在不同种属上的表达量也有明显差异<sup>[71]</sup>。另外,即使是同一种属同一组织,取材部位不同,默克尔细胞的数量也会存在明显的差异,例如:在小鼠腭中,前皱襞比后皱襞可检测到更多的默克尔细胞<sup>[22]</sup>。

在物种人中,默克尔细胞分布最多的部位是手,这可能与它在阳光下暴露比较多有关,也有可能与其接收更多的机械刺激有关<sup>[6]</sup>。默克尔细胞在人口腔、躯干、四肢/手足部位也有较多研究,这与动物中的研究结果基本一致,表明了默克尔细胞在不同物种进化上的保守性。另外,在发育过程中,默克尔细胞的数量会从出生后随着年龄的增长而逐渐减少,这表明衰老会影响触觉感知的能力。同时,研究发现,与动物类似,在人同一组织的不同部位,默克尔细胞的密度存在差异,

以人食管为例,其中段的默克尔细胞数目最多<sup>[161]</sup>。这可能与各部位的功能相关。

综上所述,在不同物种中,默克尔细胞有相似分布特征,大多分布在触觉敏感区域,且集中分布在表皮,主要发挥触觉功能。同时,默克尔细胞作为内分泌细胞,也可能行使分泌功能,其分泌的蛋白质不仅是经典意义上的神经递质,而且是生长、发育、分化的基本启动子和调节因子,发挥营养或调控功能<sup>[164]</sup>。因此推测默克尔细胞可能具有不同的群体,它们在特定发育阶段和环境发挥特定的作用,但不同物种是否都存在默克尔细胞的亚群还需要更多研究。总之,本文通过系统地统计分析已报道默克尔细胞的物种及其组织脏器,阐述了默克尔细胞在不同物种和组织脏器的分布特征,总结了默克尔细胞在不同物种中分布的共性和特性,为了解生物多样性提供了更多理论参考。

#### 参考文献(Reference):

- [1] CZECH-DAMAL N U, DEHNHARDT G, MANGER P, *et al.* Passive electroreception in aquatic mammals[J]. *Journal of Comparative Physiology A: Neuroethology, Sensory, Neural, and Behavioral Physiology*, 2013, 199(6): 555-563.
- [2] GREGORY J E, IGGO A, MCINTYRE A K, *et al.* Receptors in the bill of the platypus[J]. *The Journal of Physiology*, 1988, 400(1): 349-366.
- [3] MANGER P R, PETTIGREW J D. Ultrastructure, number, distribution and innervation of electroreceptors and mechanoreceptors in the bill skin of the platypus, *Ornithorhynchus anatinus*[J]. *Brain, Behavior and Evolution*, 1996, 48(1): 27-54.
- [4] LEITCH D B, CATANIA K C. Structure, innervation and response properties of integumentary sensory organs in crocodylians[J]. *Journal of Experimental Biology*, 2012, 215(23): 4217-4230.
- [5] HALATA Z, GRIM M, BAUMAN K I. Friedrich Sigmund Merkel and his "Merkel cell", morphology, development, and physiology: review and new results[J]. *The Anatomical Record*, 2003, 271A(1): 225-239.
- [6] KÜCKEN M, CHAMPOD C. Merkel cells and the individuality of friction ridge skin[J]. *Journal of Theoretical Biology*, 2013, 317: 229-237.
- [7] XIAO Y, WILLIAMS J S, BROWNELL I. Merkel cells and touch domes: more than mechanosensory functions?[J]. *Experimental Dermatology*, 2014, 23(10): 692-695.
- [8] HASHIMOTO K. The ultrastructure of the skin of human embryos. X. Merkel tactile cells in the finger and nail[J]. *Journal of Anatomy*, 1972, 111(Pt 1): 99-120.
- [9] HASHIMOTO K. Fine structure of Merkel cell in human oral mucosa[J]. *Journal of Investigative Dermatology*, 1972, 58(6): 381-387.
- [10] MOLL I, KUHN C, MOLL R. Cytokeratin 20 is a general marker of cutaneous Merkel cells while certain neuronal proteins are absent[J]. *Journal of Investigative Dermatology*, 1995, 104(6): 910-915.
- [11] MOLL I, PAUS R, MOLL R. Merkel cells in mouse skin: intermediate filament pattern, localization, and hair cycle-dependent density[J]. *Journal of Investigative Dermatology*, 1996, 106(2): 281-286.

- [12] POLAKOVIČOVÁ S, CSÖBÖNYEIOVÁ M, FILOVA B, *et al.* Merkel-like cell distribution in the epithelium of the human vagina. An immunohistochemical and TEM study[J]. *European Journal of Histochemistry*, 2018, 62(1): 2836.
- [13] WINKELMANN R K. The Merkel cell system and a comparison between it and the neurosecretory or APUD cell system[J]. *Journal of Investigative Dermatology*, 1977, 69(1): 41-46.
- [14] PASCHE F, MÉROT Y, SAURAT J H. Relationship between Merkel cells and nerve endings during embryogenesis in the mouse epidermis[J]. *Journal of Investigative Dermatology*, 1990, 95(3): 247-251.
- [15] SZEDER V, GRIM M, HALATA Z, *et al.* Neural crest origin of mammalian Merkel cells[J]. *Developmental Biology*, 2003, 253(2): 258-263.
- [16] VAN KEYMEULEN A, MASCRE G, YOUSEFF K K, *et al.* Epidermal progenitors give rise to Merkel cells during embryonic development and adult homeostasis[J]. *The Journal of Cell Biology*, 2009, 187(1): 91-100.
- [17] MÉROT Y, CARRAUX P, SAURAT J H. Merkel cell mitoses in vibrissae: an ultrastructural study[J]. *Journal of Anatomy*, 1987, 153: 241-244.
- [18] HALATA Z, KUCERA J, KUCERA T, *et al.* Apoptosis of Merkel cells in neurotrophin-3 null mice[J]. *Anatomy and Embryology*, 2005, 209(4): 335-340.
- [19] CHENG CHEW S B, LEUNG P Y. Species variability in the expression of met- and leu-enkephalin-like immunoreactivity in mammalian Merkel cell dense-core granules. A light- and electron-microscopic immunohistochemical study[J]. *Cell and Tissue Research*, 1992, 269(2): 347-351.
- [20] CHENG CHEW S B, LEUNG P Y. Ultrastructural study of the Merkel cell and its expression of met-enkephalin immunoreactivity during fetal and postnatal development in mice[J]. *Journal of Anatomy*, 1994, 185(Pt 3): 511-520.
- [21] TACHIBANA T, ISHIZEKI K, SAKAKURA Y, *et al.* Immunohistochemical and cytochemical evidences for a possible localization of leucine aminopeptidase in the Merkel cell granule[J]. *Acta Histochemica*, 1989, 86(1): 79-84.
- [22] ICHIKAWA H, MATSUO S, SILOS-SANTIAGO I, *et al.* Developmental dependency of Merkel endings on trks in the palate[J]. *Molecular Brain Research*, 2001, 88(1/2): 171-175.
- [23] TACHIBANA T, FUJIWARA N, SATO H, *et al.* A comparative electron microscopic analysis of mechanoreceptors in the hard palate of the mouse (*Mus musculus*; Rodentia) and the musk shrew (*Suncus murinus*; insectivora)[J]. *Archives of Oral Biology*, 1990, 35(12): 949-956.
- [24] HAEBERLE H, LUMPKIN E A. Merkel cells in somatosensation[J]. *Chemosensory Perception*, 2008, 1(2): 110-118.
- [25] VIELKIND U, SEBZDA M K, GIBSON I R, *et al.* Dynamics of Merkel cell patterns in developing hair follicles in the dorsal skin of mice, demonstrated by a monoclonal antibody to mouse keratin 8[J]. *Acta Anatomica*, 1995, 152(2): 93-109.
- [26] MORRISON K M, MIESEGAES G R, LUMPKIN E A, *et al.* Mammalian Merkel cells are descended from the epidermal lineage[J]. *Developmental Biology*, 2009, 336(1): 76-83.
- [27] CHEW S B, LEUNG P Y. Immunocytochemical evidence of a met-enkephalin-like substance in the dense-core granules of mouse Merkel cells[J]. *Cell and Tissue Research*, 1991, 265(3): 611-614.
- [28] NGUYEN M B, VALDES V J, COHEN I, *et al.* Dissection of Merkel cell formation in hairy and glabrous skin reveals a common requirement for FGFR2-mediated signalling[J]. *Experimental Dermatology*, 2019, 28(4): 374-382.
- [29] NINDL M, NAKAGAWA H, ISHIBASHI Y. Keratin expression in Merkel cells of fetal rat skin[J]. *Journal of Dermatology*, 1991, 18(12): 720-724.
- [30] HITCHCOCK I S, GENEVER P G, CAHUSAC P M B. Essential components for a glutamatergic synapse between Merkel cell and nerve terminal in rats[J]. *Neuroscience Letters*, 2004, 362(3): 196-199.
- [31] NURSE C A, FARRAWAY L. Characterization of Merkel cells and mechanosensory axons of the rat by styryl pyridinium dyes[J]. *Cell and Tissue Research*, 1989, 255(1): 125-128.
- [32] NURSE C A, FARRAWAY L. Development of Merkel cell populations with contrasting sensitivities to neonatal deafferentation in the rat whisker pad[J]. *Somatosensory & Motor Research*, 1988, 6(2): 141-162.
- [33] NURSE C A, MEAROW K M, HOLMES M, *et al.* Merkel cell distribution in the epidermis as determined by quinacrine fluorescence[J]. *Cell & Tissue Research*, 1983, 228(3): 511-524.
- [34] IRMAK M K, OZTAS E, YAGMURCA M, *et al.* Effects of electromagnetic radiation from a cellular telephone on epidermal Merkel cells[J]. *Journal of Cutaneous Pathology*, 2003, 30(2): 135-138.
- [35] NIKAI H, ROSE G G, CATTONI M. Merkel cell in human and rat gingiva[J]. *Archives of Oral Biology*, 1971, 16(8): 835-843.
- [36] TACHIBANA T, FUJIWARA N, NAWA T. Postnatal differentiation of Merkel cells in the rat palatine mucosa, with special reference to the timing of peripheral nerve development and the potency of cell mitosis[J]. *Anatomy and Embryology*, 2000, 202(5): 359-367.
- [37] YEH Y, BYERS M R. Fine structure and axonal transport labeling of intraepithelial sensory nerve endings in anterior hard palate of the rat[J]. *Somatosensory Research*, 1983, 1(1): 1-19.
- [38] TANAKA T, NARISAWA Y. Three-dimensional comparative study of Merkel cell distribution in various body sites of Guinea pigs and rats[J]. *Archives of Dermatological Research*, 2000, 292(4): 173-179.
- [39] TACHIBANA T, NAWA T. Recent progress in studies on Merkel cell biology[J]. *Anatomical Science International*, 2002, 77(1): 26-33.
- [40] CHEN S Y, GERSON S, MEYER J. The fusion of Merkel cell granules with a synapse-like structure[J]. *Journal of Investigative Dermatology*, 1973, 61(5): 290-292.
- [41] ENGLISH K B, WANG Z Z, STAYNER N, *et al.* Serotonin-like immunoreactivity in Merkel cells and their afferent neurons in touch domes from the hairy skin of rats[J]. *The Anatomical Record*, 1992, 232(1): 112-120.
- [42] ENGLISH K B, BURGESS P R, KAVKA-VAN NORMAN D. Development of rat Merkel cells[J]. *The Journal of Comparative Neurology*, 1980, 194(2): 475-496.
- [43] NAKAFUSA J, NARISAWA Y, SHINOBU T, *et al.* Changes in the number of Merkel cells with the hair cycle in hair discs on rat back skin[J]. *The British Journal of Dermatology*, 2006, 155(5): 883-889.
- [44] YAMASHITA Y, AKAIKE N, WAKAMORI M, *et al.* Voltage-dependent currents in isolated single Merkel cells of rats[J]. *The Journal of Physiology*, 1992, 450(1): 143-162.
- [45] OCHIAI T, SUZUKI H. Fine structural and morphometric studies of the Merkel cell during fetal and postnatal development[J]. *Journal of Investigative Dermatology*, 1981, 77(6): 437-443.
- [46] FINDLATER G S, COOKSEY E J, ANAND A, *et al.* The effects of hypoxia on slowly adapting type I (SAI) cutaneous mechanoreceptors in the cat and rat[J]. *Somatosensory Research*, 1987, 5(1): 1-17.
- [47] TACHIBANA T, FUJIWARA N, NAWA T. Mechanoreceptors of the hard palate of the Mongolian gerbil include special junctions between epithelia and Meissner lamellar cells: a comparison with other rodents[J]. *The Anatomical Record*, 1991, 231(3): 396-403.
- [48] RICE F L, MANCE A, MUNGER B L. A comparative light microscopic analysis of the sensory innervation of the mystacial pad. I. Innervation of vibrissal follicle-sinus complexes[J]. *Journal of Comparative Neurology*, 1986, 252(2): 154-174.
- [49] TACHIBANA T, YAMAMOTO H, TAKAHASHI N, *et al.* Polymorphism of Merkel cells in the rodent palatine mucosa: immunohistochemical and ultrastructural studies[J]. *Archives of Histology and Cytology*, 1997, 60(4): 379-389.
- [50] TACHIBANA T. The Merkel cell: recent findings and unresolved problems[J]. *Archives of Histology and Cytology*, 1995, 58(4): 379-396.
- [51] ISHIZAKI K, SAKURAI K, TAZAKI M, *et al.* Response of Merkel cells in the palatal rugae to the continuous mechanical stimulation by palatal plate[J]. *Somatosensory & Motor Research*, 2006, 23(1/2): 63-72.

- [52] CALDERON-SOLT L, SOLT D B. Touch domes and Merkel cells in hamster cheek pouch epithelium[J]. Archives of Oral Biology, 1984, 29(7): 569-573.
- [53] HALATA Z, MUNGER B L. The sensory innervation of primate eyelid[J]. The Anatomical Record, 1980, 198(4): 657-670.
- [54] HALATA Z. Sensory innervation of the hairy skin (light- and electronmicroscopic study)[J]. Journal of Investigative Dermatology, 1993, 101(1 Suppl.): S75-S81.
- [55] TURNER D F. The morphology and distribution of Merkel cells in primate gingival mucosa[J]. The Anatomical Record, 1983, 205(2): 197-205.
- [56] DELL D A, MUNGER B L. The early embryogenesis of papillary (sweat duct) ridges in primate glabrous skin: the dermatotopic map of cutaneous mechanoreceptors and dermatoglyphics[J]. The Journal of Comparative Neurology, 1986, 244(4): 511-532.
- [57] HALATA Z, BAUMANN K I. Sensory nerve endings in the hard palate and papilla incisiva of the rhesus monkey[J]. Anatomy and Embryology, 1999, 199(5): 427-437.
- [58] TOYOSHIMA K, MIYAMOTO K, ITOH A, et al. Merkel-neurite complexes in the fungiform papillae of two species of monkeys[J]. Cell and Tissue Research, 1987, 250(1): 237-239.
- [59] TACHIBANA T, ENDOH M, NAWA T. Immunohistochemical expression of G protein alpha-subunit isoforms in rat and monkey Merkel cell-neurite complexes[J]. Histochemistry and Cell Biology, 2001, 116(3): 205-213.
- [60] GÜÇLÜ B, MAHONEY G K, PAWSON L J, et al. Localization of Merkel cells in the monkey skin: an anatomical model[J]. Somatosensory & Motor Research, 2008, 25(2): 123-138.
- [61] GARANT P R, FELDMAN J, CHO M I, et al. Ultrastructure of Merkel cells in the hard palate of the squirrel monkey (*Saimiri sciureus*)[J]. The American Journal of Anatomy, 1980, 157(2): 155-167.
- [62] CAUNA N. The mode of termination of the sensory nerves and its significance[J]. The Journal of Comparative Neurology, 1959, 113(2): 169-209.
- [63] RAMÍREZ G A, RODRÍGUEZ F, QUESADA Ó, et al. Anatomical mapping and density of Merkel cells in skin and mucosae of the dog[J]. The Anatomical Record, 2016, 299(9): 1157-1164.
- [64] SHIWA N, MANALO D L, BOLDBAATAR B, et al. Follicle-sinus complexes in muzzle skin of domestic and wild animals as diagnostic material for detection of rabies[J]. The Journal of Veterinary Medical Science, 2020, 82(8): 1204-1208.
- [65] ALVAREZ F J, CERVANTES C, VILLALBA R, et al. Immunocytochemical analysis of calcitonin gene-related peptide and vasoactive intestinal polypeptide in Merkel cells and cutaneous free nerve endings of cats[J]. Cell and Tissue Research, 1988, 254(2): 429-437.
- [66] CHELYSHEV Y A, VINTER R I. Tactile (Merkel's) cells of sinus hairs after colchicine application to a nerve in cats[J]. Neuroscience and Behavioral Physiology, 1984, 14(2): 110-117.
- [67] EBARA S, KUMAMOTO K, MATSUURA T, et al. Similarities and differences in the innervation of mystacial vibrissal follicle-sinus complexes in the rat and cat: a confocal microscopic study[J]. The Journal of Comparative Neurology, 2002, 449(2): 103-119.
- [68] ABRAHAMS V C, HODGINS M, DOWNEY D. Morphology, distribution, and density of sensory receptors in the glabrous skin of the cat rhinarium[J]. Journal of Morphology, 1987, 191(2): 109-114.
- [69] HARTSCHUH W, WEIHE E. Fine structural analysis of the synaptic junction of Merkel cell-axon-complexes[J]. Journal of Investigative Dermatology, 1980, 75(2): 159-165.
- [70] TADOKORO O, MAEDA T, HEYERAAS K J, et al. Merkel-like cells in Malassez epithelium in the periodontal ligament of cats: an immunohistochemical, confocal-laser scanning and immunoelectron-microscopic investigation[J]. Journal of Periodontal Research, 2002, 37(6): 456-463.
- [71] GAUWEILER B, WEIHE E, HARTSCHUH W, et al. Presence and coexistence of chromogranin A and multiple neuropeptides in Merkel cells of mammalian oral mucosa[J]. Neuroscience Letters, 1988, 89(2): 121-126.
- [72] ENGLISH K B. Cell types in cutaneous type I mechanoreceptors (Haarscheiben) and their alterations with injury[J]. The American Journal of Anatomy, 1974, 141(1): 105-126.
- [73] HARTSCHUH W, WEIHE E, YANAIHARA N, et al. Immunohistochemical localization of vasoactive intestinal polypeptide (VIP) in Merkel cells of various mammals: evidence for a neuromodulator function of the Merkel cell[J]. Journal of Investigative Dermatology, 1983, 81(4): 361-364.
- [74] ENGLISH K B. The ultrastructure of cutaneous type I mechanoreceptors (Haarscheiben) in cats following denervation[J]. The Journal of Comparative Neurology, 1977, 172(1): 137-163.
- [75] EBARA S, KUMAMOTO K, BAUMANN K I, et al. Three-dimensional analyses of touch domes in the hairy skin of the cat paw reveal morphological substrates for complex sensory processing[J]. Neuroscience Research, 2008, 61(2): 159-171.
- [76] MOSCONI T M, RICE F L. Sequential differentiation of sensory innervation in the mystacial pad of the ferret[J]. Journal of Comparative Neurology, 1993, 333(3): 309-325.
- [77] STEPHENS R J, BEEBE I J, POULTER T C. Innervation of the vibrissae of the California sea lion, *Zalophus californianus*[J]. The Anatomical Record, 1973, 176(4): 421-441.
- [78] RICE F L, RASMUSSEN D D. Innervation of the digit on the forepaw of the raccoon[J]. The Journal of Comparative Neurology, 2000, 417(4): 467-490.
- [79] MUNGER B L, PUBOLS L M, PUBOLS B H. The Merkel rete papilla: a slowly adapting sensory receptor in mammalian glabrous skin[J]. Brain Research, 1971, 29(1): 47-61.
- [80] YIN J X, WANG H M, RACEY P, et al. Distribution and ultrastructure of Merkel cell of the fishing bat (*Myotis ricketti*)[J]. Science in China Series C: Life Sciences, 2009, 52(9): 802-806.
- [81] SCHNEIDER E R, GRACHEVA E O, BAGRIANTSEV S N. Evolutionary specialization of tactile perception in vertebrates[J]. Physiology, 2016, 31(3): 193-200.
- [82] HARTSCHUH W, WEIHE E, EGNER U. Chromogranin A in the mammalian Merkel cell: cellular and subcellular distribution[J]. Journal of Investigative Dermatology, 1989, 93(5): 641-648.
- [83] WEIHE E, HARTSCHUH W, NOHR D. Light microscopic immunoenzyme and electron microscopic immunogold cytochemistry reveal tachykinin immunoreactivity in Merkel cells of pig skin[J]. Neuroscience Letters, 1991, 124(2): 260-263.
- [84] HALATA Z, COOPER B Y, BAUMANN K I, et al. Sensory nerve endings in the hard palate and papilla incisiva of the goat[J]. Experimental Brain Research, 1999, 129(2): 218-228.
- [85] NAFSTAD P H. Evidence of turnover of mammalian Merkel cells[J]. Journal of Anatomy, 1987, 151: 57-64.
- [86] LYNE A G, HOLLIS D E. Merkel cells in sheep epidermis during fetal development[J]. Journal of Ultrastructure Research, 1971, 34(5): 464-472.
- [87] LAURIANO E R, PERGOLIZZI S, ARAGONA M, et al. Merkel cells immunohistochemical study in striped dolphin (*Stenella coeruleoalba*) skin[J]. Tissue & Cell, 2019, 56: 1-6.
- [88] BOWKER R M, LANCASTER L S, ISBELL D A. Morphological evaluation of Merkel cells and small lamellated sensory receptors in the equine foot[J]. American Journal of Veterinary Research, 2017, 78(6): 659-667.
- [89] LOO S K, HALATA Z. The sensory innervation of the nasal glabrous skin in the short-nosed bandicoot (*Isodon macrourus*) and the opossum (*Didelphis virginiana*)[J]. Journal of Anatomy, 1985, 143: 167-180.
- [90] SCHULZE C, SPAETHE A, HALATA Z. The sensory innervation of the gingiva and mucosa in *Monodelphis domestica*: an ultrastructural study[J]. Acta Anatomica, 1993, 146(1): 36-41.
- [91] BRENOWITZ G L, TWEDDLE C D, JOHNSON J I. The development of receptors in the glabrous forepaw skin of pouch young opossums[J]. Neuroscience, 1980, 5(7): 1303-1310.
- [92] YAMAMOTO T, SAKADA S. Sensory innervation of gingival and alveolar mucosa of the house musk shrew (*Suncus murinus*)[J]. The Tohoku Journal of Experimental Medicine, 1986, 150(3): 327-336.
- [93] YOHRO T. Structure of the sinus hair follicle in the big-clawed shrew, *Sorex unguiculatus*[J]. Journal of Morphology, 1977, 153(2): 333-353.

- [94] CATANIA K C. A comparison of the Eimer's organs of three north American moles: the hairy-tailed mole (*Parascalops breweri*), the star-nosed mole (*Condylura cristata*), and the eastern mole (*Scalopus aquaticus*)[J]. *The Journal of Comparative Neurology*, 1995, 354(1): 150-160.
- [95] TACHIBANA T, NAWA T. Merkel cell differentiation in the labial mucous epithelium of the rabbit[J]. *Journal of Anatomy*, 1980, 131(Pt 1): 145-155.
- [96] TOYOSHIMA K, SETA Y, TAKEDA S, *et al.* Identification of Merkel cells by an antibody to villin[J]. *Journal of Histochemistry & Cytochemistry*, 1998, 46(11): 1329-1334.
- [97] LOO S K, HALATA Z. Innervation of hairs in the facial skin of marsupial mammals[J]. *Journal of Anatomy*, 1991, 174: 207-219.
- [98] GEMMELL R T, PETERS B, NELSON J. Ultrastructural identification of Merkel cells around the mouth of the newborn marsupial[J]. *Anatomy and Embryology*, 1988, 177(5): 403-408.
- [99] WINKELMANN R K, FORTMAN G J. The Merkel cell[J]. *The Japanese Journal of Dermatology. Series B*, 1972, 82(3): 98-105.
- [100] MANGER P R, HUGHES R L. Ultrastructure and distribution of epidermal sensory receptors in the beak of the echidna, *Tachyglossus aculeatus*[J]. *Brain, Behavior and Evolution*, 1992, 40(6): 287-296.
- [101] IGGO A, GREGORY J E, PROSKE U. Studies of mechanoreceptors in skin of the snout of the echidna *Tachyglossus aculeatus*[J]. *Somatosensory & Motor Research*, 1996, 13(2): 129-138.
- [102] EGLMEIER W. The development of the Merkel cells in the tentacles of *Xenopus laevis* larvae[J]. *Anatomy and Embryology*, 1987, 176(4): 493-500.
- [103] OVALLE W K. Neurite complexes with Merkel cells in larval tentacles of *Xenopus laevis*[J]. *Cell and Tissue Research*, 1979, 204(2): 233-241.
- [104] FOX H. The epidermis and its degeneration in the larval tail and adult body of *Rana temporaria* and *Xenopus laevis* (Amphibia: Anura)[J]. *Journal of Zoology*, 1974, 174(2): 217-235.
- [105] MEAROW K M, DIAMOND J. Merkel cells and the mechanosensitivity of normal and regenerating nerves in *Xenopus* skin[J]. *Neuroscience*, 1988, 26(2): 695-708.
- [106] LANE E B, WHITEAR M. On the occurrence of Merkel cells in the epidermis of teleost fishes[J]. *Cell and Tissue Research*, 1977, 182(2): 235-246.
- [107] CROWE R, WHITEAR M. Quinacrine fluorescence of Merkel cells in *Xenopus laevis*[J]. *Cell and Tissue Research*, 1978, 190(2): 273-283.
- [108] DÜRING M V, ANDRES K H. The ultrastructure of taste and touch receptors of the frog's taste organ[J]. *Cell and Tissue Research*, 1976, 165(2): 185-198.
- [109] TOYOSHIMA K, SHIMAMURA A. An immunohistochemical demonstration of neuron-specific enolase in the Merkel cells of the frog taste organ[J]. *Archives of Histology & Cytology*, 1988, 51(3): 295-297.
- [110] TOYOSHIMA K, SETA Y, TOYONO T, *et al.* Merkel cells are responsible for the initiation of taste organ morphogenesis in the frog[J]. *The Journal of Comparative Neurology*, 1999, 406(1): 129-140.
- [111] TACHIBANA T. The Merkel cell in the labial ridge epidermis of the anuran tadpole. II. Electron microscope observations on the appearance and differentiation of the Merkel cell[J]. *Archivum Histologicum Japonicum*, 1979, 42(2): 129-140.
- [112] TACHIBANA T. The Merkel cell in the labial ridge epidermis of anuran tadpole. I. Fine structure, distribution and cytochemical studies[J]. *The Anatomical Record*, 1978, 191(4): 487-501.
- [113] NAFSTAD P H J, BAKER R E. Comparative ultrastructural study of normal and grafted skin in the frog, *Rana pipiens*, with special reference to neuroepithelial connections[J]. *Zeitschrift für Zellforschung und Mikroskopische Anatomie*, 1973, 139(4): 451-462.
- [114] TAKEDA M, NISHIKAWA T, SATO S, *et al.* Effects of gadolinium and tetrodotoxin on the response of slowly adapting type I mechanoreceptors to mechanical stimulation in frog dorsal skin[J]. *Journal of the Peripheral Nervous System*, 2003, 8(4): 271-281.
- [115] YAMASHITA Y, OGAWA H. Slowly adapting cutaneous mechanoreceptor afferent units associated with Merkel cells in frogs and effects of direct currents[J]. *Somatosensory & Motor Research*, 1991, 8(1): 87-95.
- [116] BANI G. Ultrastructure of Merkel cells in the epidermis of *Hyla arborea*[J]. *Bollettino di Zoologia*, 1982, 49(3/4): 257-268.
- [117] BUDTZ P E, ZACCONE G. Ultrastructure and neuron-specific enolase (NSE) immunohistochemistry of Merkel cells in normal toad epidermis, and following ablation of the pars distalis of the pituitary gland[J]. *Acta Histochemica*, 1990, 88(2): 115-124.
- [118] DELAY R J, TAYLOR R, ROPER S D. Merkel-like basal cells in *Necturus* taste buds contain serotonin[J]. *Journal of Comparative Neurology*, 1993, 335(4): 606-613.
- [119] NAGAI T, KOYAMA H. Ultrastructure of Merkel-like cells labeled with carbocyanine dye in the non-taste lingual epithelium of the axolotl[J]. *Neuroscience Letters*, 1994, 178(1): 1-4.
- [120] TWEEDLE C D. Ultrastructure of Merkel cell development in aneurogenic and control amphibian larvae (*Ambystoma*)[J]. *Neuroscience*, 1978, 3(4/5): 481-486.
- [121] SAXOD R. Ultrastructure of Merkel corpuscles and so-called "transitional" cells in the white leghorn chicken[J]. *American Journal of Anatomy*, 1978, 151(4): 453-473.
- [122] NAFSTAD P H. On the avian Merkel cells[J]. *Journal of Anatomy*, 1986, 145: 25-33.
- [123] HALATA Z, GRIM M. Sensory nerve endings in the beak skin of Japanese quail[J]. *Anatomy and Embryology*, 1993, 187(2): 131-138.
- [124] TOYOSHIMA K, SETA Y, SHIMAMURA A. Fine structure of Merkel corpuscles in the lingual mucosa of Japanese quail, *Coturnix coturnix japonica*[J]. *Archives of Oral Biology*, 1993, 38(11): 1009-1012.
- [125] GRIM M, HALATA Z. Developmental origin of avian Merkel cells[J]. *Anatomy and Embryology*, 2000, 202(5): 401-410.
- [126] TOYOSHIMA K. Are Merkel and Grandry cells two varieties of the same cell in birds?[J]. *Archives of Histology and Cytology*, 1993, 56(2): 167-175.
- [127] TOYOSHIMA K, SHIMAMURA A. Uranaffin reaction of Merkel corpuscles in the lingual mucosa of the finch, *Lonchura striata* var. *domestica*[J]. *Journal of Anatomy*, 1991, 179: 197-201.
- [128] YOSHIE S, YOKOSUKA H, KANAZAWA H, *et al.* The existence of Merkel cells in the lingual connective tissue of the Surinam caiman, *Caiman crocodilus crocodilus* (order Crocodylia)[J]. *Archives of Histology and Cytology*, 1999, 62(1): 97-106.
- [129] TOYOSHIMA K, SETA Y, SHIMAMURA A. The occurrence and fine structure of Merkel cells in the lingual epithelium of the turtle, *Clemmys japonica*[J]. *Okajimas Folia Anatomica Japonica*, 1993, 70(2/3): 63-67.
- [130] LANDMANN L, HALATA Z. Merkel cells and nerve endings in the labial epidermis of a lizard[J]. *Cell and Tissue Research*, 1980, 210(2): 353-357.
- [131] WHITEAR M, LANE E B. Fine structure of Merkel cells in lampreys[J]. *Cell and Tissue Research*, 1981, 220(1): 139-151.
- [132] ZACCONE G, FASULO S, AINIS L. Distribution patterns of the paraneuronal endocrine cells in the skin, gills and the airways of fishes as determined by immunohistochemical and histological methods[J]. *The Histochemical Journal*, 1994, 26(8): 609-629.
- [133] WHITEAR M. Merkel cells in lower vertebrates[J]. *Archives of Histology & Cytology*, 1989, 52(Suppl.): 415-422.
- [134] ZACHAR P C, JONZ M G. Confocal imaging of Merkel-like basal cells in the taste buds of zebrafish[J]. *Acta Histochemica*, 2012, 114(2): 101-115.
- [135] ZACCONE G. Neuron-specific enolase and serotonin in the Merkel cells of conger-eel (*Conger conger*) epidermis. An immunohistochemical study[J]. *Histochemistry*, 1986, 85(1): 29-34.
- [136] COHEN K E, FLAMMANG B E, CRAWFORD C H, *et al.* Knowing when to stick: touch receptors found in the remora adhesive disc[J]. *Royal Society Open Science*, 2020, 7(1): 190990.
- [137] NARISAWA Y, HASHIMOTO K, KOHDA H. Merkel cells in human fetal eccrine glands[J]. *British Journal of Dermatology*, 1993, 129(5): 541-546.

- [138] NARISAWA Y, HASHIMOTO K, KOHDA H. Merkel cells of the terminal hair follicle of the adult human scalp[J]. *Journal of Investigative Dermatology*, 1994, 102(4): 506–510.
- [139] MOLL I. Merkel cell distribution in human hair follicles of the fetal and adult scalp[J]. *Cell and Tissue Research*, 1994, 277(1): 131–138.
- [140] MAY C A, OSTERLAND I. Merkel cell distribution in the human eyelid[J]. *European Journal of Histochemistry*, 2013, 57(4): e33.
- [141] RIGHI A, BETTS C M, MARCHETTI C, *et al.* Merkel cells in the oral mucosa[J]. *International Journal of Surgical Pathology*, 2006, 14(3): 206–211.
- [142] KINGSMILL V J, BERKOVITZ B K B, BARRETT A W. An immunohistochemical analysis of human Merkel cell density in gingival epithelium from dentate and edentulous subjects[J]. *Archives of Oral Biology*, 2005, 50(10): 883–887.
- [143] GARCÍA-CABALLERO L, CANEIRO J, GÁNDARA M, *et al.* Merkel cells of human oral mucosa express the pluripotent stem cell transcription factor Sox2[J]. *Histology and Histopathology*, 2020, 35(9): 1007–1012.
- [144] NARISAWA Y, HASHIMOTO K, KOHDA H. Epithelial skirt and bulge of human facial vellus hair follicles and associated Merkel cell–nerve complex[J]. *Archives of Dermatological Research*, 1993, 285(5): 269–277.
- [145] UCHIGASAKI S, SUZUKI H, INOUE K. Merkel cells in the vellus hair follicles of human facial skin: a study using confocal laser microscopy[J]. *Journal of Dermatology*, 2004, 31(3): 218–222.
- [146] LACOUR J P, DUBOIS D, PISANI A, *et al.* Anatomical mapping of Merkel cells in normal human adult epidermis[J]. *British Journal of Dermatology*, 1991, 125(6): 535–542.
- [147] FRADETTE J, LAROUCHE D, FUGÈRE C, *et al.* Normal human Merkel cells are present in epidermal cell populations isolated and cultured from glabrous and hairy skin sites[J]. *Journal of Investigative Dermatology*, 2003, 120(2): 313–317.
- [148] GUTIÉRREZ-VILLANUEVA M, GARCÍA-MESA Y, GARCÍA-PIQUERAS J, *et al.* The sensory innervation of the human nipple[J]. *Annals of Anatomy–Anatomischer Anzeiger*, 2020, 229: 151456.
- [149] WANG L, HILLIGES M, JERNBERG T, *et al.* Protein gene product 9.5–immunoreactive nerve fibres and cells in human skin[J]. *Cell & Tissue Research*, 1990, 261(1): 25–33.
- [150] SAAD EL-DIEN H M, ABDELWAHEB HUSSEIN M R, EL-OTEIFY M. Sensory innervation of the female human umbilical skin: morphological studies[J]. *Ultrastructural Pathology*, 2013, 37(1): 62–69.
- [151] KABATA Y, ORIME M, ABE R, *et al.* The morphology, size and density of the touch dome in human hairy skin by scanning electron microscopy[J]. *Microscopy*, 2019, 68(3): 207–215.
- [152] MOLL I, ZIEGER W, SCHMELZ M. Proliferative Merkel cells were not detected in human skin[J]. *Archives of Dermatological Research*, 1996, 288(4): 184–187.
- [153] KIM D K, HOLBROOK K A. The appearance, density, and distribution of Merkel cells in human embryonic and fetal skin: their relation to sweat gland and hair follicle development[J]. *Journal of Investigative Dermatology*, 1995, 104(3): 411–416.
- [154] MOLL I, MOLL R. Merkel cells in ontogenesis of human nails[J]. *Archives of Dermatological Research*, 1993, 285(6): 366–371.
- [155] MOLL I, MOLL R. Early development of human Merkel cells[J]. *Experimental Dermatology*, 1992, 1(4): 180–184.
- [156] VELA-ROMERA A, CARRIEL V, MARTÍN-PIEDRA M A, *et al.* Characterization of the human ridged and non-ridged skin: a comprehensive histological, histochemical and immunohistochemical analysis[J]. *Histochemistry and Cell Biology*, 2019, 151(1): 57–73.
- [157] NARISAWA Y, HASHIMOTO K. Immunohistochemical demonstration of nerve–Merkel cell complex in fetal human skin[J]. *Journal of Dermatological Science*, 1991, 2(5): 361–370.
- [158] MOLL I, MOLL R, FRANKE W W. Formation of epidermal and dermal Merkel cells during human fetal skin development[J]. *Journal of Investigative Dermatology*, 1986, 87(6): 779–787.
- [159] NARISAWA Y, HASHIMOTO K, BAYLESS T, *et al.* Cytokeratin polypeptide profile of Merkel cells in human fetal and adult skin: difference of expression of cytokeratins in epidermal and dermal Merkel cells[J]. *Journal of Investigative Dermatology*, 1992, 98(2): 171–180.
- [160] NARISAWA Y, HASHIMOTO K, NIHEI Y, *et al.* Biological significance of dermal Merkel cells in development of cutaneous nerves in human fetal skin[J]. *Journal of Histochemistry & Cytochemistry*, 1992, 40(1): 65–71.
- [161] HARMSE J L, CAREY F A, BAIRD A R, *et al.* Merkel cells in the human oesophagus[J]. *The Journal of Pathology*, 1999, 189(2): 176–179.
- [162] BOOT P M, ROWDEN G, WALSH N. The distribution of Merkel cells in human fetal and adult skin[J]. *The American Journal of Dermatopathology*, 1992, 14(5): 391–396.
- [163] HALATA Z, MUNGER B L. The neuroanatomical basis for the protopathic sensibility of the human glans penis[J]. *Brain Research*, 1986, 371(2): 205–230.
- [164] GOULD V E, MOLL R, MOLL I, *et al.* Neuroendocrine (Merkel) cells of the skin: hyperplasias, dysplasias, and neoplasms[J]. *Laboratory Investigation*, 1985, 52(4): 334–353.

## (上接第 252 页)

- [97] 叶如梦, 田镡, 胡海静, 等. 一株枯草芽孢杆菌对香蜂花的促生效果及关键代谢物积累的环境响应[J]. *应用与环境生物学报*(YE Rumeng, TIAN Kai, HU Haijing, *et al.* Prompting effects of an endophytic bacteria, *Bacillus subtilis*, on *Melissa officinalis* L. growth and response of its central secondary metabolic products to culturing conditions[J]. *Chinese Journal of Applied and Environmental Biology*), 2020, 26(5): 1035–1045.
- [98] 赵新林, 赵思峰. 枯草芽孢杆菌对植物病害生物防治的作用机理[J]. *湖北农业科学*(ZHAO Xinlin, ZHAO Sifeng. Research advance in controlling plant diseases by *Bacillus subtilis*[J]. *Hubei Agricultural Sciences*), 2011, 50(15): 3025–3028.
- [99] 赵达, 傅俊范, 裘季燕, 等. 枯草芽孢杆菌在植病生防中的作用机制与应用[J]. *辽宁农业科学*(ZHAO Da, FU Junfan, QIU Jiyan, *et al.* Action mechanisms and application of *Bacillus subtilis* on biocontrol of plant disease[J]. *Liaoning Agricultural Sciences*), 2007(1): 46–48.
- [100] ZABIHULLAH Sherzad, 杨娜, 张静, 等. 棉花内生解淀粉芽孢杆菌 489-2-2 对棉花黄萎病的防效研究[J]. *核农学报*(ZABIHULLAH Sherzad, YANG Na, ZHANG Jing, *et al.* Study on the control effect of endophytic *Bacillus amyloliquefaciens* 489-2-2 on Verticillium wilt of cotton[J]. *Journal of Nuclear Agricultural Sciences*), 2021, 35(1): 41–48.
- [101] 李文鹏, 陶冶, 赵素雅, 等. 芽孢杆菌 HT-7 对棉花黄萎病菌的拮抗作用及拮抗因子初探[J]. *河南农业科学*(LI Wenpeng, TAO Ye, ZHAO Suyu, *et al.* Antagonism of *Bacillus* sp. HT-7 against Verticillium wilt of cotton and exploration of antagonistic factors[J]. *Journal of Henan Agricultural Sciences*), 2020, 49(8): 84–93.
- [102] 戎松浩. 芽孢杆菌 B21 中抗稻瘟病菌物质的分析及防治效果评价[D]. 成都: 四川农业大学(RONG Songhao. Potential and Analysis of the Antifungal Compounds Produced by *Bacillus* sp. B21 as a Biopesticide to Control Rice Blast[D]. Chengdu: Sichuan Agricultural University), 2019.
- [103] 何有为. 芽孢杆菌对油菜根肿病和稻瘟病的生防潜能研究[D]. 武汉: 华中农业大学(HE Youwei. Biocontrol Potential of *Bacillus* Strains Against Canola Clubroot and Rice Blast[D]. Wuhan: Huazhong Agricultural University), 2018.
- [104] 黄国东, 宋清晖, 王晓慧, 等. 含枯草芽孢杆菌肥料对大豆叶片光合作用及土壤酶活性的影响[J]. *土壤与作物*(HUANG Guodong, SONG Qinghui, WANG Xiaohui, *et al.* Effects of fertilizers containing *Bacillus subtilis* on photosynthesis of soybean leaves and soil enzyme activities[J]. *Soils and Crops*), 2021, 10(1): 99–107.