

[文章编号] 1671-587X(2026)01-0236-10

DOI:10.13481/j.1671-587X.20260125

## 单颌拔牙矫治Ⅲ°开殆并发舌体肥大 1 例报告及文献复习

田 磊, 刘宇妍, 王雨晴, 张芷钰, 孙秀梅  
(吉林大学口腔医院正畸科, 吉林 长春 130021)

[摘要] 开殆畸形作为临床常见的错殆畸形, 其治疗过程复杂且复发率高, 是正畸治疗的难点之一, 本文作者报道 1 例青少年Ⅲ°开殆患者的诊疗经过, 旨在为临床医生治疗该类疾病提供参考。患者, 男性, 13 岁, 因“牙不齐, 前牙咬不上”就诊, 寻求矫治以改善咬合功能和面部形态。患者临床表现为前牙Ⅲ°开殆、上颌Ⅲ°拥挤和舌体肥大, 诊断为安氏Ⅱ类错殆畸形、毛氏Ⅳ<sup>2</sup>+Ⅰ<sup>1</sup>+Ⅴ错殆畸形。通过上颌单颌拔牙配合舌栏的矫治方法取得了较为满意的治疗效果。矫治结束后, 患者的开殆得到了明显改善, 上下颌牙齿排列整齐, 达到了尖窝交错的咬合关系。在开殆畸形的治疗中, 应尽早纠正不良习惯, 利用患者生长发育潜力、后牙的楔形效应以及前牙的钟摆效应纠正开殆。

[关键词] 单颌拔牙; 开殆; 舌体肥大; 不良舌习惯; 正畸治疗; 病例报告

[中图分类号] R783.5 [文献标志码] B

## Grade Ⅲ open bite complicated with tongue hypertrophy treated by mandibular incisor extraction: A case report and literature review

TIAN Lei, LIU Yuyan, WANG Yuqing, ZHANG Zhiyu, SUN Xiumei

(Department of Orthodontics, Stomatology Hospital, Jilin University, Changchun 130021, China)

**ABSTRACT** Open bite malocclusion, as a clinically common type of malocclusion, presents complex treatment processes and a high relapse rate, making it one of the challenges in orthodontic treatment. The author of this article reported the diagnosis and treatment process of a teenage patient with a grade Ⅲ open bite to provide reference for the clinicians in managing such conditions. The patient, a 13-year-old male, sought treatment for “misaligned teeth and inability to bite with front teeth” to improve occlusal function and facial appearance. The clinical manifestations included a grade Ⅲ anterior open bite, grade Ⅲ maxillary crowding, and macroglossia. The diagnosis was Angle Class Ⅱ malocclusion and Mao's Class Ⅳ<sup>2</sup>+Ⅰ<sup>1</sup>+Ⅴ malocclusion. A satisfactory treatment outcome was achieved through maxillary single-jaw extraction combined with the use of a lingual arch. After treatment, the patient's open bite was significantly improved, with well-aligned upper and lower teeth and an intercuspal occlusion relationship. In the treatment of open bite malocclusion, it is essential to correct bad habits as early as possible, leveraging the patient's growth potential, the wedge effect of posterior teeth, and the pendulum effect of anterior teeth to correct the open bite.

[收稿日期] 2025-04-08 [录用日期] 2025-05-06

[基金项目] 吉林省科技厅自然科学基金项目 (YDZJ202201ZYTS081)

[作者简介] 田 磊 (1999-), 男, 吉林省长春市人, 在读硕士研究生, 主要从事正畸学基础与临床方面的研究。

[通信作者] 孙秀梅, 副教授, 硕士研究生导师 (E-mail: xmsun@jlu.edu.cn)

©《吉林大学学报 (医学版)》编辑部, 开放获取遵循 CC BY-NC-ND 协议。

© Editorial Board of Journal of Jilin University (Medicine Edition). Open access under CC BY-NC-ND license.

**KEYWORDS** Mandibular incisor extraction; Open bite; Tongue hypertrophy; Tongue thrust habit; Orthodontic treatment; Case report

开牙作为临床常见的错牙畸形, 表现为上下颌牙列在垂直方向上无接触, 前牙区或后牙区无法正常咬合。其病因复杂, 可能涉及遗传因素、口腔不良习惯和颌骨发育异常等<sup>[1-2]</sup>。根据病因学特征可将开牙分为牙性开牙与骨性开牙两类, 对于牙性开牙, 可利用内收前牙产生的钟摆效应、压低后牙产生的楔形效应以及适当的伸长前牙进行矫治; 对于严重的骨性开牙, 可通过正颌手术的方式矫正颌骨异常<sup>[3-5]</sup>, 随着种植钉支抗技术的发展<sup>[6-7]</sup>, 部分病例也可避免手术干预<sup>[8]</sup>。近年来, 隐形矫治器凭借其牙套厚度的优势, 通过压低后牙应用于开牙治疗<sup>[9-10]</sup>。但复发问题难以彻底解决<sup>[11]</sup>, 这可能与舌体异常位置和口周肌功能紊乱等潜在病因的持续密切相关<sup>[12]</sup>。目前, 国内外学者已对开牙的诊断和治疗进行了深入研究, 但高复发率使开牙仍被视为临床上最具有挑战性的错牙畸形之一<sup>[13]</sup>。本研究报告1例青少年Ⅲ°开牙病例, 通过上颌单颌拔牙内收前牙、改良Nance弓辅助压低后牙和佩戴舌栏纠正吐舌习惯的方式进行治疗, 取得了较为满意的治疗效果。本研究通过探讨该病例矫治方案的设计和临床操作要点, 阐明开牙矫治基本策略, 为该类患者的临床治疗提供参考。

## 1 临床资料

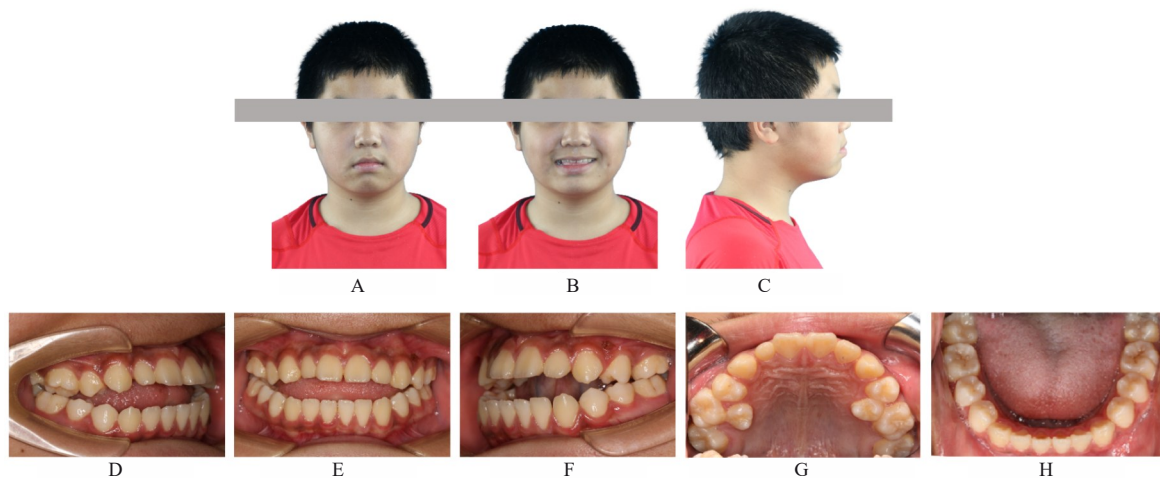
**1.1 一般资料** 患者, 男性, 13岁。患者家属因患儿牙齿不齐和前牙咬不上持续数年, 影响咬合功能和面容美观, 要求矫治, 于2019年7月就诊于本院正畸科。患者否认系统性疾病史和过敏史, 否认家族遗传史, 自述有吐舌习惯。本病例已通过本院伦理审批(伦理审批号: SJDKQ2025054), 并获得患者及其家属知情同意。

**1.2 专科检查和临床诊断** 面部检查: 正面相显示患者面部左右略不对称; 侧貌略突, 下唇前突, 颏部略后缩(图1)。口内检查: 恒牙列, 左侧磨牙为远中尖对尖关系, 右侧磨牙为完全远中关系; 前牙区Ⅲ°开牙, 最大处约为6 mm(图1)。在休息状态下可见舌尖位于上下切牙之间, 患者口齿不清, 舌体肥大, 放松时舌体几乎占据整个下牙弓, 舌侧缘有齿痕(图2)。12过小牙, 15和25舌向异位, 16严重颊侧倾斜、舌尖下垂, 13和23近远中散在间隙。下颌中线较面中线右偏2 mm, 牙龈局

部红肿, 全口卫生状况一般(图1)。模型分析: 上颌拥挤8 mm, 下颌无拥挤, bolton比偏大(前牙比82%, 全牙比93%), Spee曲线正常(图3)。曲面断层片显示患者处于恒牙列期, 下颌体形态欠对称; 正位片显示鼻中隔偏曲, 颏右偏, 双侧下颌升支和下颌体形态欠对称。侧位片测量分析显示骨性I类[上齿槽座点、鼻根点、下齿槽座点交角(A-nasion-B point angle, ANB)=3.4°], 上下前牙唇倾[上颌中切牙牙长轴与蝶鞍中心、鼻根点连线交角(upper incisor to sella-nasion plane angle, U1-SN)=116.9°], 上下中切牙成角102.1°, 偏高角[下颌平面角(mandibular plane to sella-nasion plane angle, MP-SN)=35.2°]; 开牙倾向[覆牙深度指数(overbite depth indicator, ODI)=66.0°]、拔牙指数(extraction index, EI)<150°]; 水平生长型[前后面高比(facial height index, FHI, S-Go/N-Me)=67.0%](图4)。诊断: 骨性I类错牙畸形, 安氏II类错牙畸形, 毛氏IV<sup>2</sup>+I<sup>1</sup>+V错牙畸形。

**1.3 治疗目标和治疗方案** 经过全面的检查以及测量分析后, 确定以下矫治目标: ①矫正开牙, 建立前牙区正常的覆牙覆盖关系; ②解决牙齿排列拥挤; ③纠正下颌中线偏斜; ④破除不良舌习惯; ⑤获得稳定的咬合关系和平衡的面部轮廓, 改善微笑美学。矫治方案: ①改良Nance弓压低伸长的16; ②舌栏破除不良舌习惯; ③减数15、25、38和48, 利用拔牙间隙及散在间隙排齐内收上前牙; ④种植钉支抗远中直立下颌后牙以适当内收下前牙。

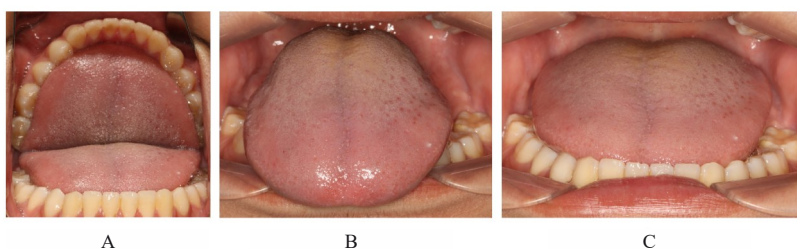
**1.4 治疗过程** 经牙体牙髓科和牙周科全面口腔检查后, 于口腔颌面外科拔除15、25、38和48, 随后佩戴改良Nance弓及上牙列托槽, 排齐上前牙的同时借助Nance弓扭正压低16, 并嘱患者进行舌肌训练, 纠正不良舌习惯(图5)。矫治12个月时, 上颌基本排齐, 16压低效果明显, 16垫玻璃离子牙垫防止复发。因患者自行纠正不良舌习惯的效果较差, 佩戴舌栏纠正患者吐舌习惯, 并粘接下牙列托槽(图6)。摇椅弓配合前牙区垂直牵引, 建立前牙区正常的覆牙覆盖关系, 并通过靴型曲进一步调整上颌磨牙的位置和转矩(图7)。待患者不良舌习惯纠正后去除舌栏。矫治24个月时, 前牙区开牙明显改善, 上下颌中线仍未对齐, 后牙区咬合



A, B: Frontal view; C: Profile view; D: Photograph of right side; E: Photograph of front side; F: Photograph of left side; G: Photograph of maxillary; H: Photograph of mandibular.

图1 Ⅲ°开殆并发舌体肥大患者治疗前面部和口内照片

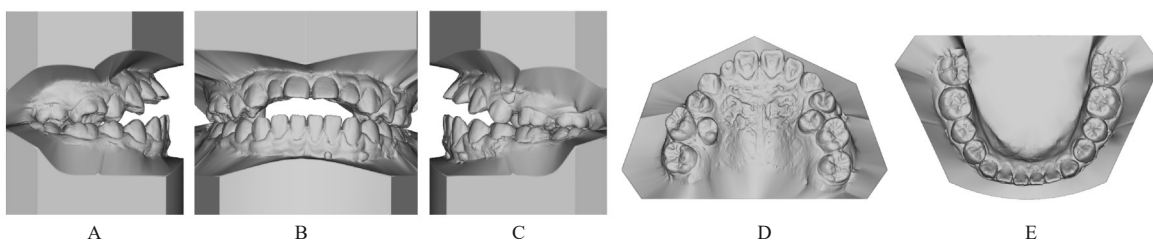
Fig. 1 Pretreatment facial and intraoral photographs of one patient with grade III open bite complicated with tongue hypertrophy



A: Occlusal view; B: Tongue protruded; C: Frontal view.

图2 Ⅲ°开殆并发舌体肥大患者舌体照片

Fig. 2 Photographs of tongue of one patient with grade III open bite complicated with tongue hypertrophy



A: Model of right side; B: Model of front side; C: Model of left side; D: Model of maxillary; E: Model of mandibular.

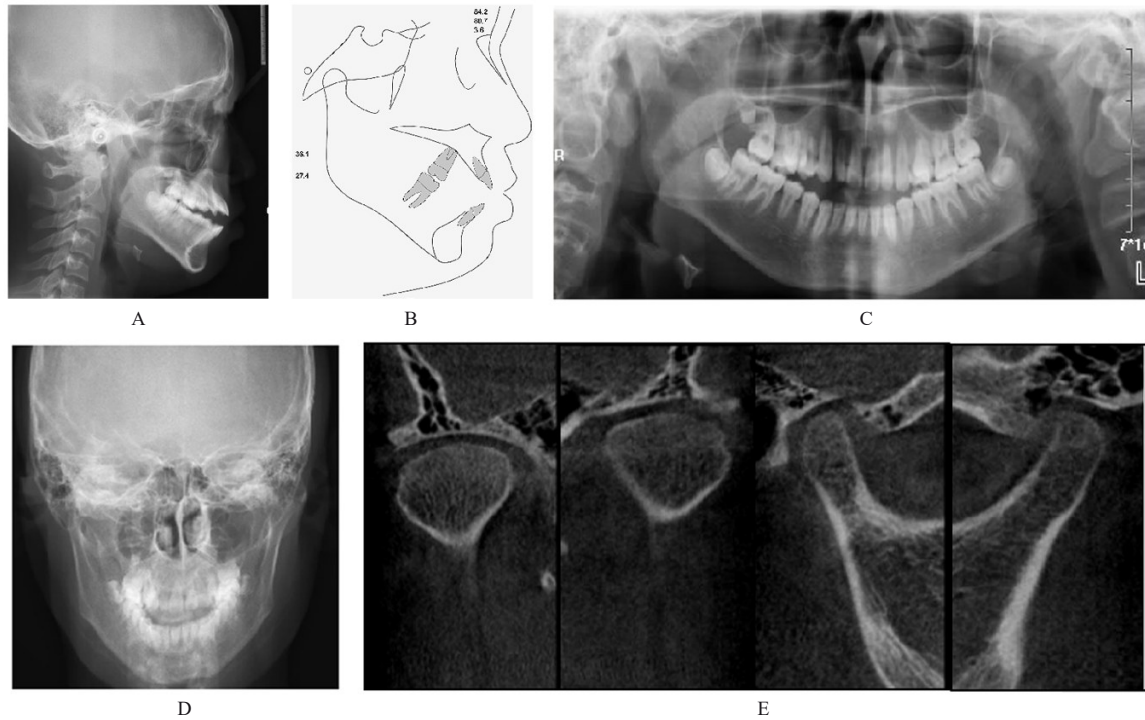
图3 Ⅲ°开殆并发舌体肥大患者治疗前口腔模型

Fig. 3 Pretreatment dental models of one patient with grade III open bite complicated with tongue hypertrophy

关系欠佳, 挂颌间不对称斜形牵引, 调整尖磨牙关系并对齐上下颌中线(图8)。矫治36个月时, 患者上下颌中线基本对正、左侧后牙区咬合仍偏近中关系, 经与患者家属沟通, 于下颌外斜线处植入种植钉, 推左侧磨牙向远中移动以协调上下颌弓形, 建立后牙区尖窝交错的咬合关系(图9)。矫治40个月时, 患者中线对正, 前牙区覆殆覆盖均较浅, 患

者及其家属对治疗效果满意, 要求直接拆除矫治器。嘱患者维持3个月后, 拆除矫治器, 佩戴Hawleys保持器进行长期保持(图10)。

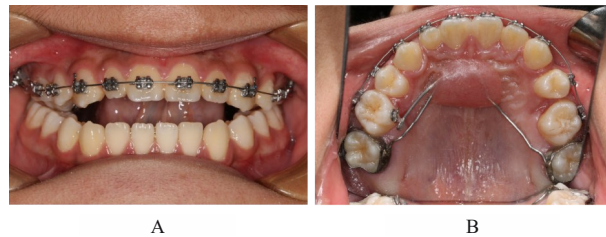**1.5 治疗结果** 本次治疗已基本达到矫治目标。口内相可见前牙区开殆已被解除, 后牙区为完全远中的尖窝交错咬合关系, 上下颌中线与面中线基本对正(图11和12)。治疗后全景片显示牙根平行度



A: Pretreatment cephalogram; B: Pretreatment tracing; C: Pretreatment panoramic radiograph; D: Pretreatment posteroanterior radiography; E: Pretreatment temporomandibular joint.

图4 Ⅲ°开殆并发舌体肥大患者治疗前侧位片、头影测量、全景片、正位片和颞下颌关节

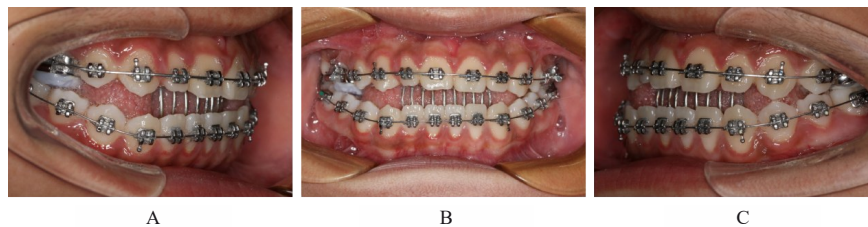
Fig. 4 Pretreatment cephalogram, cephalometric, panoramic radiograph, posteroanterior radiograph and temporomandibular joint of one patient with grade III open bite complicated with tongue hypertrophy



A: Photograph of front side; B: Photograph of maxillary.

图5 Ⅲ°开殆并发舌体肥大患者上颌佩戴的改良Nance弓

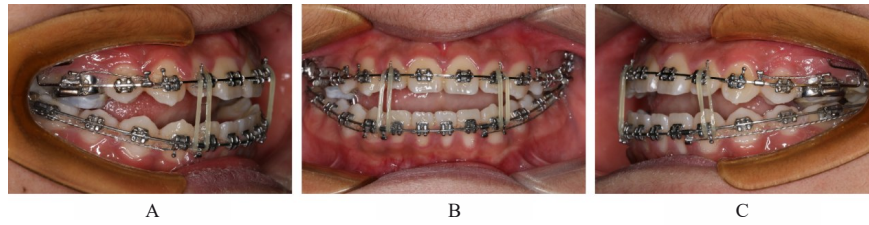
Fig. 5 Modified Nance arches in maxilla worn in one patient with grade III open bite complicated with tongue hypertrophy



A: Photograph of right side; B: Photograph of front side; C: Photograph of left side.

图6 Ⅲ°开殆并发舌体肥大患者佩戴的舌栏

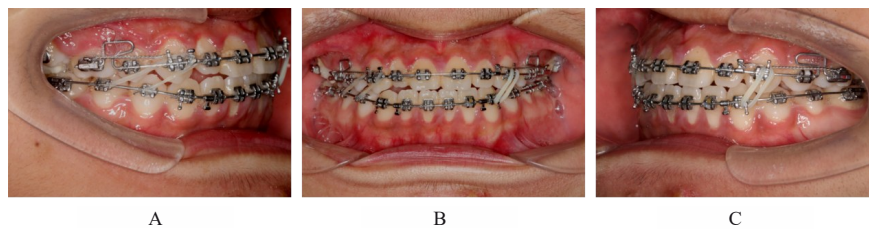
Fig. 6 Tongue bar worn in one patient with grade III open bite complicated with tongue hypertrophy



A: Photograph of right side; B: Photograph of front side; C: Photograph of left side.

图7 Ⅲ°开殆并发舌体肥大患者摇椅弓和垂直牵引的照片

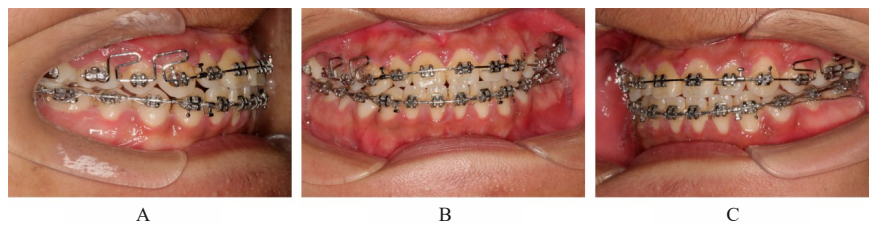
Fig. 7 Photographs of rocking-chair archwire and vertical traction of one patient with grade III open bite complicated with tongue hypertrophy



A: Photograph of right side; B: Photograph of front side; C: Photograph of left side.

图8 Ⅲ°开殆并发舌体肥大患者颌间斜行牵引的照片

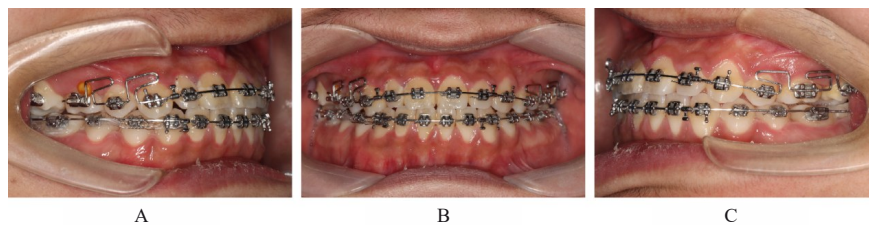
Fig. 8 Photographs of intermaxillary oblique traction of one patient with grade III open bite complicated with tongue hypertrophy



A: Photograph of right side; B: Photograph of front side; C: Photograph of left side.

图9 Ⅲ°开殆并发舌体肥大患者下颌植入种植钉的照片

Fig. 9 Photographs of mandibular implant nails of one patient with grade III open bite complicated with tongue hypertrophy



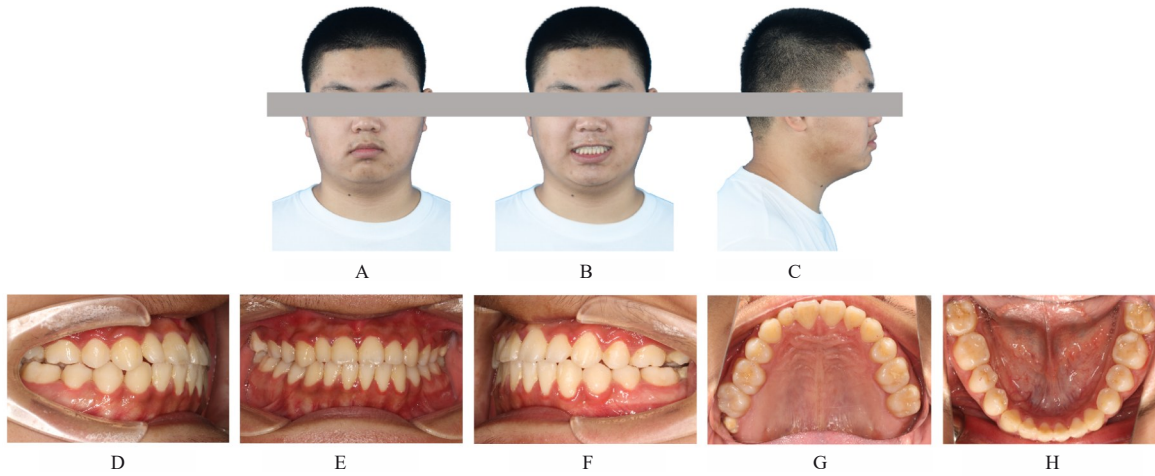
A: Photograph of right side; B: Photograph of front side; C: Photograph of left side.

图10 Ⅲ°开殆并发舌体肥大患者治疗结束时口内照片

Fig. 10 Intraoral photographs of one patient with grade III open bite complicated with tongue hypertrophy at treatment completion

较好, 无明显的牙根吸收, 正位片显示患者下颌位置基本正常, 左右基本对称(图13)。治疗后侧位片头影测量分析和重叠图显示: 下颌骨少量逆旋,

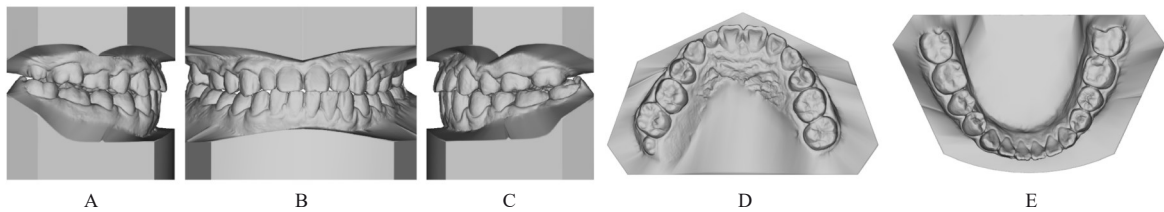
下颌平面角减少 $2.8^{\circ}$ 。上下颌切牙均有一定程度的内收, 上下切牙间角度恢复正常, 上颌磨牙有一定程度压低, ODI恢复至正常值范围内(图13、图14



A, B: Frontal view; C: Profile view; D: Photograph of right side; E: Photograph of front side; F: Photograph of left side; G: Photograph of maxillary; H: Photograph of mandibular.

图 11 Ⅲ°开殆并发舌体肥大患者治疗结束后面部和口内照片

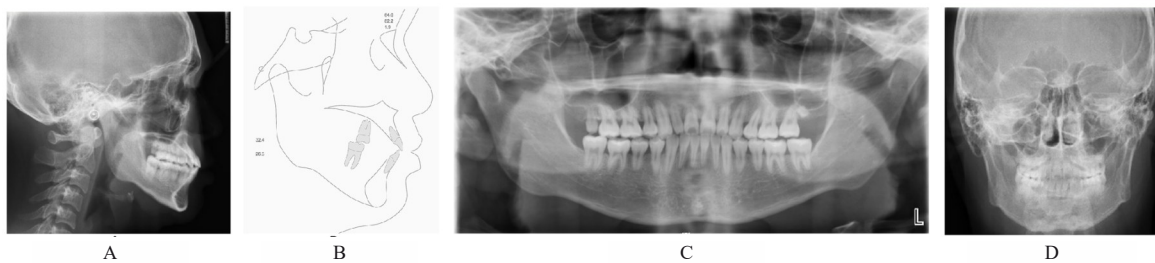
Fig. 11 Facial and intraoral photographs of one patient with grade III open bite complicated with tongue hypertrophy after completion of treatment



A: Model of right side; B: Model of front side; C: Model of left side; D: Model of maxillary; E: Model of mandibular.

图 12 Ⅲ°开殆并发舌体肥大患者治疗结束后口腔模型

Fig. 12 Dental models of one patient with grade III open bite complicated with tongue hypertrophy after completion of treatment



A: Posttreatment cephalogram; B: Posttreatment tracing; C: Posttreatment panoramic radiograph; D: Posttreatment posteroanterior radiograph.

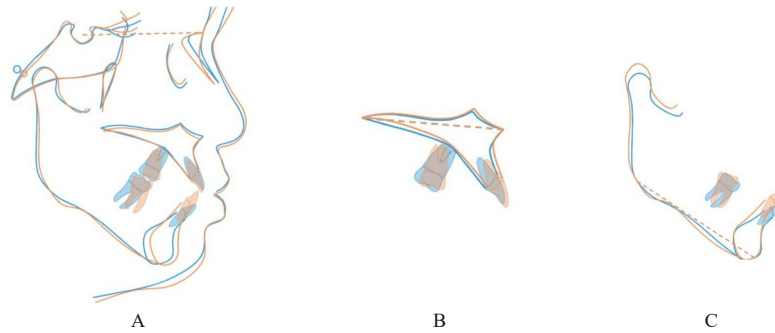
图 13 Ⅲ°开殆并发舌体肥大患者治疗结束后侧位片、头影测量、全景片和正位片

Fig. 13 Cephalogram, cephalometric, panoramic radiograph and posteroanterior radiograph of one patient with grade III open bite complicated with tongue hypertrophy after completion of treatment

和表1)。患者的1年随访结果显示：患者有一定复发倾向，前牙覆殆较矫治结束时略变浅，这可能是由患者舌头过大和不良习惯所导致，但咬合关系良好，矫治效果基本稳定（图15）。

## 2 讨论

开殆作为临床常见的错殆畸形，其病因复杂，常涉及牙性、骨性和不良习惯等多种因素，可通过多种手段进行治疗<sup>[4, 14]</sup>。在本病例中，由于患者



A: Overall superimposition; B: Maxillary regional superimposition; C: Mandibular regional superimposition. Blue: Superimposition at pretreatment; Orange: Posttreatment.

图14 Ⅲ°开殆并发舌体肥大患者治疗后头影测量重叠图

Fig. 14 Posttreatment cephalometric superimpositions of one patient with grade III open bite complicated with tongue hypertrophy

表1 Ⅲ°开殆并发舌体肥大患者治疗前后头影测量分析

Tab. 1 Cephalometric detection analysis of patient with grade III open bite complicated with tongue hypertrophy before and after treatment

Measurement	Normal ( $\bar{x} \pm s$ )	Pretreatment	Posttreatment
SNA (°)	82.8±4.0	84.1	83.8
SNB (°)	80.1±3.9	80.7	82.2
ANB (°)	2.7±2.0	3.4	1.6
MP-SN (°)	32.5±5.2	35.2	32.4
U1-SN (°)	105.7±6.3	116.9	111.8
U1-NA (mm)	5.1±2.4	6.7	6.6
U1-NA (°)	22.8±5.7	32.8	28.1
L1-MP (°)	92.6±7.0	105.7	93.4
L1-NB (mm)	6.7±2.1	8.7	6.8
L1-NB (°)	30.3±5.8	41.6	28.0
U1-L1 (°)	125.4±7.9	102.1	122.4
Wits (mm)	-1.1±2.0	-2.4	-2.0
APDI (°)	86.0±4.0	80.8	85.5
ODI (°)	73.3±5.9	66.0	68.0
S-Go (mm)	80.0±4.0	79.7	82.1
N-Me (mm)	112.0±7.0	118.9	119.5
S-Go/N-Me (%)	63.0±2.0	67.0	68.7

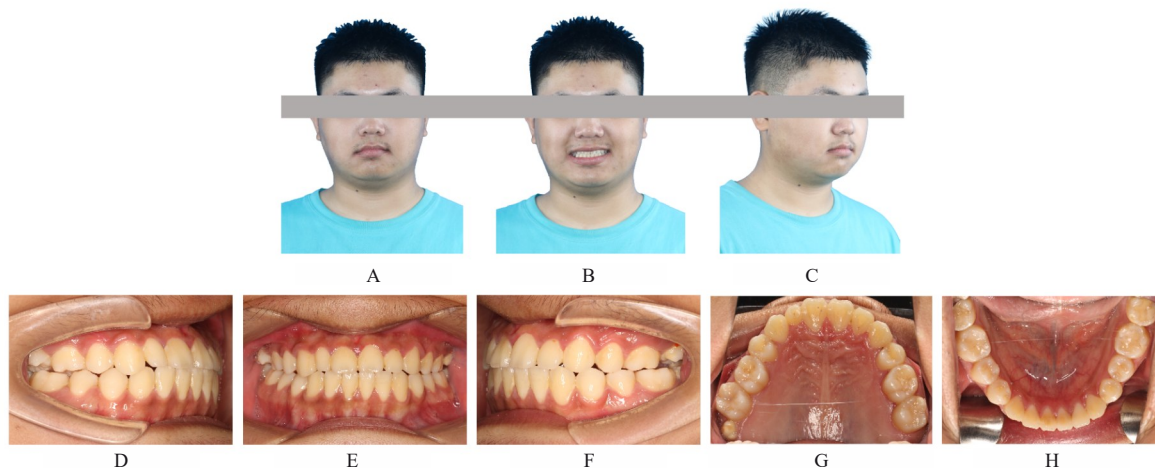
APDI: Anteroposterior dysplasia indicator.

Ⅲ°开殆且上颌Ⅲ°拥挤，上下颌前牙唇倾 [上颌中切牙牙长轴与蝶鞍中心、鼻根点连线交角 (angle between the long axis of the maxillary central incisor and the line connecting sella turcica and nasion, U1-SN): 116.9°; 上颌中切牙牙长轴与鼻根点、上齿槽座点连线交角 (angle between the long axis of the maxillary central incisor and the line connecting

nasion and subspinale, U1-NA): 32.8°; 下颌中切牙牙长轴下颌平面交角 (angle between the long axis of the mandibular central incisor and the mandibular plane, L1-MP): 105.7°; 下颌中切牙牙长轴与鼻根点、下齿槽座点连线交角 (angle between the long axis of the mandibular central incisor and the line connecting nasion and supramentale, L1-NB): 41.6°], EI<150°支持拔牙，因此考虑拔牙矫治，利用内收前牙产生的钟摆效应及少量的前牙伸长纠正开殆。由于患者舌体肥大，若拔牙矫治后牙弓变小的情况难以避免，过大的舌体易导致矫治效果不稳定，甚至拔牙间隙可能无法完全关闭。右侧第一磨牙为完全远中的咬合关系，若下颌双侧拔牙，该侧后牙前移量过大；若仅单侧拔牙，会导致下颌牙弓形态不对称和中线偏斜<sup>[15]</sup>。基于以上考虑，本文作者决定仅上颌拔牙，下颌不拔牙，通过左下颌植入种植钉远移磨牙，建立后牙区完全远中的咬合关系。而16的扭转及伸长是开殆的另一诱因，因此考虑利用改良Nance弓压低16以降低后牙支点。通过佩戴舌栏纠正不良习惯，利用后牙压低产生的楔形效应、前牙内收产生的钟摆效应以及前牙的绝对伸长纠正开殆。

不良舌习惯是开殆的常见病因之一<sup>[16]</sup>，不良舌习惯会引起开殆，同样开殆也会诱发不良舌习惯进一步加重开殆<sup>[17]</sup>。因此，在矫治过程和矫治后的保持过程中，纠正不良舌习惯非常重要<sup>[18]</sup>。该患者在矫治初期改正不良习惯效果不佳，因此在矫治中期给患者佩戴舌栏，辅助患者纠正不良舌习惯。

对于压低后牙的楔形效应，可通过弓丝、垫后



A, B: Frontal view; C: Profile view; D: Photograph of right side; E: Photograph of front side; F: Photograph of left side; G: Photograph of maxillary; H: Photograph of mandibular.

图 15 Ⅲ°开殆并发舌体肥大患者治疗结束1年后随访时面部和口内照片

Fig. 15 Facial and intraoral photographs of one patient with grade III open bite complicated with tongue hypertrophy at 1 year follow-up after completion of treatment

牙殆垫、种植支抗<sup>[19-20]</sup>以及其他多种方式实现<sup>[21-22]</sup>。在本病例中, 16严重扭转且颊向倾斜, 腭尖明显下垂, 导致后牙支点升高, 因此本文作者制作改良Nance弓, 在压低16腭尖的同时纠正该牙的扭转, 随后配合殆垫和靴形曲对压低效果进行维持; 通过摇椅弓配合前牙区垂直牵引远中直立和压低处理下颌后牙。头影测量重叠图结果显示: 矫治结束后上颌后牙有一定程度的压低、下颌磨牙实现了远中直立, 这使得后牙支点降低, 下颌骨实现了一定程度的逆旋。

内收前牙产生的钟摆效应使前牙相对伸长, 覆殆加深, 从而有利于开殆的治疗<sup>[23]</sup>。因此拔牙矫治有利于充分利用钟摆效应<sup>[23-24]</sup>, 但对于开殆病例的治疗是否需要拔牙, 目前尚存在争议<sup>[25-26]</sup>, 有学者<sup>[27]</sup>认为拔牙治疗比非拔牙治疗具有更好的稳定性, 但也有学者<sup>[28]</sup>认为拔牙后牙弓变小, 减少舌体的空间, 造成矫治效果的不稳定。而研究<sup>[29]</sup>显示: 当拥挤不严重或骨骼变化不是主要治疗目标时, 不拔牙矫治也可获得长期稳定性, 但前提是改变不良习惯以及矫治后良好的保持。本例患者上颌Ⅲ°拥挤, 拔牙后用于前牙内收的间隙有限, 因此上颌可以利用的钟摆效应较少; 患者舌体肥大, 且下颌无明显拥挤, 因此下牙列选择非拔牙的矫正方式, 通过推磨牙向后获得间隙, 调整中线的同时内收下前牙, 利用钟摆效应减轻开殆, 这在头影测量重叠图中也得到了充分印证。

前牙伸长虽可解决开殆, 但牙齿伸长移动后, 受牙周膜纤维牵拉的影响, 其保持相对困难<sup>[30-31]</sup>, 因此在开殆的矫治中正畸医生通常少用或不用该治疗方法。然而在本病例中, 由于患者Ⅲ°开殆, 并且楔形效应和钟摆效应的利用相对有限, 因此考虑适量伸长前牙, 从而彻底解除患者前牙开殆。本研究头影测量重叠图结果显示: 矫治结束后患者下前牙有一定程度的伸长, 但从口内相中并未发现前牙区牙龈明显退缩。一方面可能是因患者处于青少年阶段, 牙槽骨和牙龈的适应性改建能力较强; 另一方面可能是由于该患者的整体矫治疗程较长, 为牙槽骨和牙龈的改建提供了充足时间。考虑到下前牙的伸长量仍然较大, 长期稳定性仍需进一步随访观察。

保持作为正畸治疗的重要环节, 是确保矫治效果长期稳定的关键<sup>[32-33]</sup>。特别是对于病因复杂、涉及垂直向控制和不良舌习惯的开殆病例, 复发率相对较高, 因此开殆解除后的保持尤为重要<sup>[34-35]</sup>。在本病例中, 由于患者自身原因, 未能及时复诊且依从性较差, 导致整体治疗时间延长, 这一特殊情况对矫治效果产生了双重影响: 一方面, 治疗时间延长影响矫治效率, 但另一方面也为牙周组织的改建提供了充分的时间, 有利于治疗效果的稳定。此外, 在矫治结束前, 医生嘱患者继续佩戴固定矫治器维持3个月后再更换为Hawleys保持器并长期保持, 有利于防止复发, 确保咬合关系的长期稳定。

目前,治疗结束后1年随访观察,疗效基本稳定。

在开骀的矫治过程中,还应该充分利用生长发育的影响,抓住最佳矫治时机<sup>[36-37]</sup>。在对比矫治前后正位片时本文作者发现患者轻度的骨骼不对称得到了改善。这可能是由于矫治前患者仅磨牙有咬合接触,局部咬合障碍点导致了下颌的偏斜,但随着咬合关系的建立以及患者自身的生长发育,下颌骨位置逐渐趋于正常,但患者面部软组织充盈,这种变化并未在面相中有所体现。本研究中,从矫治前后重叠图对比中观察到患者下颌升支有明显的生长,进一步通过Jaraback分析法测量结果显示:患者的后面高较矫治前有明显升高(S-Go距离由79.7 mm升高到82.1 mm),而前面高变化较小(N-Me距离由118.9 mm升高到119.5 mm),上述差异使骀平面有一定程度的逆时针旋转,从S-Go/N-Me中判断患者为水平生长型。以上发现提示临床医生,对于处于生长发育期的患者,早期干预不仅可以解决错骀畸形,还有利于促进颌面软硬组织向正常方向生长,对牙颌面发育具有重要意义;对于水平生长型的开骀患者,正畸治疗后可能会获得更为理想的治疗效果。

综上所述,本病例在破除不良舌习惯的同时,采取上颌单颌拔牙、下颌磨牙远移的方式,充分利用患者生长发育潜力,通过内收前牙、压低并远中直立后牙以及伸长前牙,解决患者前牙开骀,并延长矫治结束前佩戴矫治器的时间以增加稳定性,取得了较为满意的治疗效果。

#### 利益冲突声明:

所有作者声明不存在利益冲突。

#### 作者贡献声明:

田磊参与研究的整体设计和论文撰写,刘宇妍参与论文审阅,王雨晴和张芷钰参与病例资料的收集及整理,孙秀梅参与论文写作指导和审校。

#### [参考文献]

- [1] HSU J Y, CHENG J H, FENG S W, et al. Strategic treatment planning for anterior open bite: a comprehensive approach[J]. *J Dent Sci*, 2024, 19(3): 1328-1337.
- [2] WANG J, BANDA A K, KAU C H, et al. Craniofacial management of anterior openbite: a clinical review [J]. *Front Oral Maxillofac Med*, 2024, 6: 26.
- [3] SHAHNAM A R. The Multiloop edgewise archwire technique: treatment effects and stability in correction of anterior openbite [M]. Washington: University of Washington, 2023.
- [4] LEE J, CHOI Y J, PARK J H, et al. Surgical vs nonsurgical treatments in patients with anterior open-bite have similar effects in occlusal function: a 2-year follow-up study [J]. *Am J Orthod Dentofacial Orthop*, 2024, 165(1): 38-45.
- [5] ALWADEI A. Surgical-orthodontic with atypical extraction pattern as a treatment for an anterior open bite: a case report [J]. *J Pak Med Assoc*, 2024, 74(1): 161-164.
- [6] YASHIMA Y, KAKU M, YAMAMOTO T, et al. Camouflage correction of skeletal class III severe open bite with tooth ankylosis treated by temporary anchorage devices: a case report [J]. *Dent J*, 2023, 11(4): 107.
- [7] CHAMBERLAND S, NATAF N. Noninvasive conservative management of anterior open bite treated with TADs versus clear aligner therapy [J]. *Clin Oral Investig*, 2024, 28(4): 236.
- [8] TAI K, PARK S, WEISSHEIMER A, et al. Nonextraction anterior open bite treatment with distalization and intrusion [J]. *J World Fed Orthod*, 2024, 13(1): 48-54.
- [9] CREMONINI F, FALCONI V, CARAZZATO L, et al. Severe anterior open bite in a Class II hyperdivergent adult patient: a case report of clear aligner orthodontic camouflage treatment [J]. *Int Orthod*, 2025, 23(3): 100989.
- [10] ZHANG H X, HU H M, LIN D E, et al. Clear aligner treatment of an adult open bite with bilateral missing mandibular first molars through molar protraction with Albert cantilever arms [J]. *Int Orthod*, 2024, 22(4): 100918.
- [11] TAVARES C A E, ALLGAYER S. Open bite in adult patients [J]. *Dent Press J Orthod*, 2019, 24(5): 69-78.
- [12] ANTONARAKIS G S, HERZOG G, KILIARIDIS S. Vertical relapse after orthodontic and orthognathic surgical treatment in a patient with myotonic dystrophy [J]. *Eur J Paediatr Dent*, 2019, 20(1): 53-58.
- [13] MILLESI G A, DE FAZIO G R, ZIMMERMANN M, et al. Improved stability of open bite deformities: taking control of the transverse width using digital technology and robotic archwire bending [J]. *Int J Oral Maxillofac Surg*, 2025, 54(3): 245-250.
- [14] KURODA S, SAKAI Y, TAMAMURA N, et al. Treatment of severe anterior open bite with skeletal anchorage in adults: comparison with orthognathic surgery outcomes [J]. *Am J Orthod Dentofacial Orthop*,

- 2007, 132(5): 599-605.
- [15] XUE H X, XU S Y, QI Y Z, et al. Treatment of an adult patient with severe dental crowding by applying asymmetric extraction, fixed appliance, and micro-implant anchorage: a case report[J]. BMC Oral Health, 2025, 25(1): 436.
- [16] ARTESE F, FERNANDES L Q P, DE OLIVEIRA CAETANO S R, et al. Early treatment for anterior open bite: Choosing adequate treatment approaches [J]. Semin Orthod, 2023, 29(2): 207-215.
- [17] BUNTA O, FILIP I, GARBA C, et al. Tongue behavior in anterior open bite-a narrative review [J]. Diagnostics (Basel), 2025, 15(6): 724.
- [18] VIRJI S A, NG E T, JAYACHANDRAN S, et al. A case study on myofunctional therapy and malocclusions created by oral habits[J]. Can J Dent Hyg, 2023, 57(1): 61-68.
- [19] KANG M J, HONG M. Treatment of an open bite patient with maxillary expansion and micro-implant anchorage [J]. Clinical J Korean Assoc Orthodontists, 2023, 13(1): 52-63.
- [20] KIM J S. Orthodontic treatment of a skeletal class II malocclusion patient with anterior open bite [J]. Clin J Korean Assoc Orthod, 2023, 13(4): 297-307.
- [21] FINKLEMAN S, COHANIM B, TAI S K, et al. Does planned molar intrusion with aligners assist with closure of anterior open bite? [J]. Am J Orthod Dentofacial Orthop, 2024, 166(4): 330-349.e1.
- [22] ARQUB SABU, AL-MOGHRABI D, IVERSON M G, et al. Assessment of the efficacy of various maxillary molar intrusion therapies: a systematic review [J]. Prog Orthod, 2023, 24(1): 37.
- [23] LAUDADIO C, INCHINGOLO A D, MALCANGI G, et al. Management of anterior open-bite in the deciduous, mixed and permanent dentition stage: a descriptive review[J]. J Biol Regul Homeost Agents, 2021, 35(2 Suppl. 1): 271-281.
- [24] PETERKIN C, ARQUB SABU, MURPHY N, et al. A retrospective comparative cephalometric evaluation of non-extraction multiloop edgewise archwire and bicuspid extraction therapies in anterior open bite treatment [J]. Clin Oral Investig, 2024, 28(10): 569.
- [25] BALIAN A, ISOLA F, RIZZATO A, et al. Trattamento ortodontico precoce non estrattivo dell' open bite anteriore “,” Early non-extraction orthodontic treatment of anterior open bite[J]. Dent Cadmos, 2024, 92(4): 278.
- [26] COLLINS J L. Treatment Outcomes and Stability in Extraction Vs. Non-Extraction Adult Anterior Open Bite Patients [M]. Seattle: University of Washington, 2022.
- [27] JANSON G, VALARELLI F P, BELTRÃO R T S, et al. Stability of anterior open-bite extraction and nonextraction treatment in the permanent dentition [J]. Am J Orthod Dentofacial Orthop, 2006, 129(6): 768-774.
- [28] HERZOG C, KONSTANTONIS D, KONSTANTONI N, et al. Arch-width changes in extraction vs nonextraction treatments in matched Class I borderline malocclusions [J]. Am J Orthod Dentofacial Orthop, 2017, 151(4): 735-743.
- [29] ATSAWASUWAN P, HOHLT W, EVANS C A. Nonsurgical approach to Class I open-bite malocclusion with extrusion mechanics: a 3-year retention case report [J]. Am J Orthod Dentofacial Orthop, 2015, 147(4): 499-508.
- [30] 程 锋. 成人前牙开合的诊治策略 [D]. 武汉: 华中科技大学, 2019.
- [31] VARANDA R V, KUMARI J, VAN RHEDEN R E M, et al. Survival of periodontal ligament myofibroblasts after short-term mechanical strain in rats and in vitro: Could myofibroblasts contribute to orthodontic relapse?[J]. Arch Oral Biol, 2025, 172: 106173.
- [32] FLEMING P S, PANDIS N. Orthodontic retention: Rationale and periodontal implications [J]. Periodontol 2000, 2024. DOI: 10.1111/prd.12560.
- [33] AL-MOGHRABI D, ALGHARBI M, ABU ARQUB S, et al. The effectiveness of adjuncts or alternatives to the use of orthodontic retainers in preserving posttreatment outcomes: a systematic review [J]. Am J Orthod Dentofacial Orthop, 2023, 163(1): 9-21.e3.
- [34] ZUROFF J P, CHEN S H, SHAPIRO P A, et al. Orthodontic treatment of anterior open-bite malocclusion: stability 10 years postretention [J]. Am J Orthod Dentofacial Orthop, 2010, 137(3): 302.e1-302.e8;discussion 302-303.
- [35] CENZATO N, VELLA M, TRIPICCHIO C, et al. Indicazioni cliniche e raccomandazioni per la contenzione ortodontica: revisione narrativa della letteratura [J]. Dent Cadmos, 2022, 90(5): 336.
- [36] LI H. Reflections on the current state of early orthodontic treatment [J]. Hua Xi Kou Qiang Yi Xue Za Zhi, 2025, 43(2): 151-157.
- [37] FLEMING P S, ANDREWS J. Orthodontic treatment: Getting the timing right [J]. Semin Orthod, 2023, 29(2): 137-145.