

基于CT三维重建评估髂嵴对L5~S1椎间孔镜手术通道放置的影响

王金璠^{1,2}, 刘晓阳², 葛忠鹏², 崔新刚^{1,2}

(1.山东大学齐鲁医学院, 山东 济南 250012; 2.山东第一医科大学附属省立医院脊柱外科, 山东 济南 250021)

摘要:目的 分析髂嵴对穿刺放置手术通道可行性的影响。方法 回顾性分析2022年1月1日至2022年12月31日在山东省立医院行腰椎CT及腰椎DR检查的75例患者影像资料。使用Mimics 21.0软件对CT图像进行三维重建,模拟手术通道放置,评估患者L5~S1节段行PETD手术放置通道可行性。根据结果将患者分为可放置通道组和不可放置通道组,通过测量和比较两组髂嵴相对高度分级、髂嵴高度、髂嵴倾斜角、关节突倾斜角、髂嵴最高点到中线距离和髂嵴内聚角等参数之间的差异,分析髂嵴对L5~S1节段行PETD手术放置通道的影响。结果 测量分析结果显示,可放置通道组中髂嵴高度 h 、髂嵴倾斜角 α 、髂嵴内聚角 δ 等髂嵴相关的解剖参数均明显小于不可放置通道组[23.65(29.33~18.50) vs 38.20(39.80~34.40), $P<0.001$; 20.20(24.30~16.08) vs 29.15(31.98~26.65), $P<0.001$; 45.35(48.03~40.70) vs 47.75(49.98~45.33), $P=0.003$]。随着髂嵴高度的提升,通道放置的成功率不断下降,定义为“高髂嵴”(髂嵴相对高度分级为2级)的通道建立成功率只有10%。当髂嵴高度高于31.95 mm,髂嵴倾斜角大于 24.35° ,髂嵴内聚角大于 47.2° 时,穿刺放置通道容易失败。结论 髂嵴对于L5~S1行PETD手术放置通道的可行性具有显著影响。髂嵴越高,越陡峭(髂嵴倾斜角、内聚角越大)的患者越不容易成功放置通道。“高髂嵴”(髂嵴高于L4椎弓根下缘的患者)通常难以放置通道。

关键词:CT; 三维重建; 髂嵴; L5~S1; 椎间孔镜

中图分类号:R681.5 文献标志码:A

Impact of iliac crest on the placement of L5-S1 transforaminal endoscopic surgical channel based on three-dimensional CT reconstruction

WANG Jinjin^{1,2}, LIU Xiaoyang², GE Zhongpeng², CUI Xingang^{1,2}

(1. Cheeloo College of Medicine, Shandong University, Jinan 250012, Shandong, China;

2. Department of Spine Surgery, Shandong Provincial Hospital Affiliated to Shandong First Medical University, Jinan 250021, Shandong, China)

Abstract: Objective To analyze the impact of iliac crest on the feasibility of puncture placement of surgical channels.

Methods The imaging data of 75 patients who underwent lumbar spine CT and lumbar spine DR examination at Shandong Provincial Hospital during Jan. 1, 2022 and Dec. 31, 2022 were retrospectively analyzed. Mimics 21.0 software was used to perform three-dimensional reconstruction of CT images and simulate surgical channel placement to evaluate the feasibility of channel placement in percutaneous endoscopic transforaminal lumbar discectomy (PETD) in patients' L5-S1 segment. Based on the results, the patients were divided into two groups. In the implantable group, the channel

could be placed; in the non-implantable group, the channel could not be placed. The relative height classification of the iliac crest, height of the iliac crest, inclination angle of the iliac crest, inclination angle of the articular process, distance from the highest point of the iliac crest to the midline, and the cohesion angle of the iliac crest were compared between the two groups to analyze the effects of iliac crest on the channel placement of the L5-S1 segment. **Results** The measurement results showed that height of the iliac crest, inclination angle of the iliac crest, and the cohesion angle of the iliac crest were significantly lower in the implantable group than in the non-implantable group [23.65 (29.33-18.50) vs 38.20 (39.80-34.40), $P<0.001$; 20.20 (24.30-16.08) vs 29.15 (31.98-26.65), $P<0.001$; 45.35 (48.03-40.70) vs 47.75 (49.98-45.33), $P=0.003$]. As the height of the iliac crest increased, the success rate of channel placement decreased. The success rate of channel establishment of high iliac crest (the relative height of the iliac crest was grade 2) was only 10%. When height of the iliac crest was higher than 31.95 mm, inclination angle of the iliac crest was greater than 24.35° , and the cohesion angle of the iliac crest was greater than 47.2° , the channel placement was prone to failure. **Conclusion** The iliac crest has a significant impact on the feasibility of the L5-S1 PETD surgical channel placement. Patients with higher and steeper iliac crest (greater iliac crest inclination angle and cohesion angle) are less likely to have the channel successfully placed. Patients with "high iliac crest" (iliac crest above the lower edge of the L4 pedicle) are often difficult to place the channel.

Key words: CT; Three-dimensional reconstruction; Iliac crest; L5-S1; Intervertebral foramen endoscope

腰椎间盘突出症(lumbar disc herniation, LDH)是最常见的腰椎退变性疾病,由于突出的髓核压迫神经根、马尾神经引起腰腿痛等一系列的症状,常发生于L4~5和L5~S1节段,占有腰椎间盘突出症的95%左右^[1-3]。腰椎间盘突出症的外科治疗手段越来越趋于微创化,经皮内窥镜下经椎间孔腰椎间盘摘除术(percutaneous endoscopic transforaminal lumbar discectomy, PETD)只需要通过直径7 mm的工作通道取出突出的髓核,已逐渐成为手术治疗腰椎间盘突出症的首选方法^[4]。然而由于髂嵴解剖结构的阻碍,L5~S1节段的PETD手术有时会具有一定的挑战性^[5-7]。因此,通过术前影像评估患者在PETD手术中能否顺利放置通道具有重要意义。本研究回顾性分析75例患者影像学资料,对其左右两侧共150例样本进行模拟通道建立及参数测量,评估髂嵴对L5~S1椎间孔镜手术通道放置的影响。

1 资料与方法

1.1 研究对象

回顾性分析2022年1月1日至2022年12月31日山东省立医院影像科行腰椎CT平扫及腰椎DR正位片检查的75例患者影像资料,其中男34例,女41例,25~65岁,平均48.67岁。从病历系统中收集患者的性别、年龄、身高、体质量等各项一般临床资料。根据模拟通道放置结果,路径与髂嵴没有重叠的为可放置通道组($n=61$ 例),有重叠的为

不可放置通道组($n=14$ 例)。见图1。

纳入标准:①年龄18~65岁;②无脊柱畸形;③脊柱及骨盆无骨折、结核、肿瘤等疾病;④无腰骶部手术史;⑤无感染性疾病或其他慢性疾病等。排除标准:①年龄 <18 岁或 >65 岁;②脊柱或骨盆畸形;③脊柱及骨盆骨折或手术史;④腰椎或骨盆肿瘤,感染性疾病或其他慢性疾病。

1.2 方法

1.2.1 腰椎DR检查及腰椎薄层CT检查

本研究患者的腰椎CT图像采用西门子公司提供的SOMATOM Force电子计算机断层扫描仪进行检查,腰椎DR图像采用联影公司提供的UDR 780i PRO数字化X射线诊断系统,检查体位均为仰卧位。

1.2.2 CT三维图像重建及建立PETD手术通道模型

将患者腰椎CT图像的原始文件导入Mimics 21.0软件,进行三维重建(图2)。在3D模型上,模拟手术通道的经典穿刺路径,取S1椎体上终板上缘中点作为通道的止点,S1椎体上关节突最高点为通道的经过点,构建一个长14 cm、半径3.5 mm的标准PETD手术通道模型。

1.2.3 髂嵴高度分级

基于腰椎DR正位片对患者的髂嵴高度进行分级(图3),平L4~5椎间隙高度定为0级;高于L4~5椎间隙,低于L4椎弓根下缘定义为1级;高于L4椎弓根下缘,定义为2级;低于L4~5椎间隙,高于L5椎弓根下缘定义为-1级;低于L5椎弓根下缘定义为-2级。

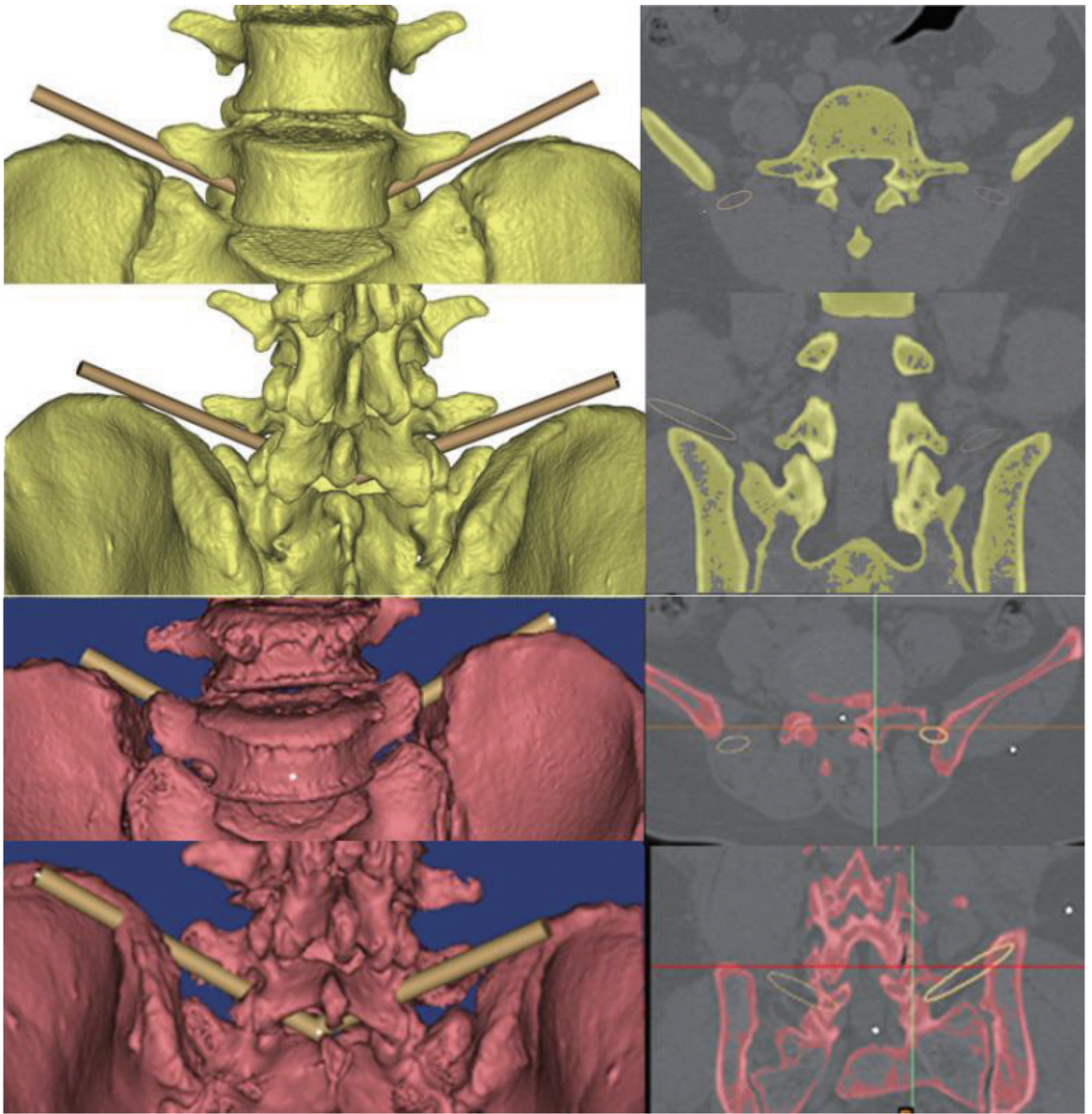


图1 黄色为可放置通道组;红色为不可放置通道组,在冠状位与矢状位 CT 上均可看到通道(黄色影)与髂嵴重叠
 Figure 1 Yellow indicated the implantable group; red indicated the non-implantable group; the channel (yellow shadow) overlapped with the iliac crest on coronal and sagittal CT

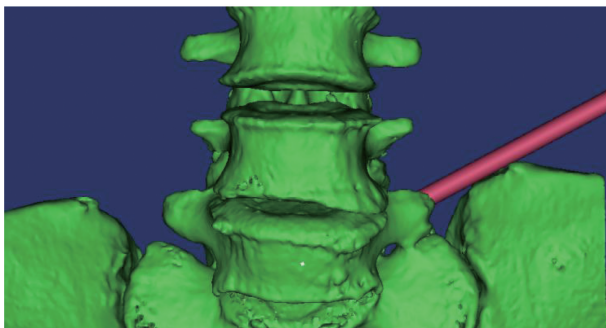


图2 采用 Mimics 21.0 基于 CT 图像建立腰椎-髂嵴-手术通道 3D 模型
 Figure 2 Mimics 21.0 was used to establish a 3D model of the lumbar spine-iliac crest-surgical channel based on CT images

1.2.4 髂嵴倾斜角与髂嵴高度

在构建好的 3D 模型上(图 3),取 S1 椎体后上

缘中点,定义该点到髂嵴最高点的连线与其所在平面之间的夹角为髂嵴倾斜角。髂嵴最高点与 S1 椎体后上缘中点所在平面的垂直距离定义为髂嵴高度。见图 4。

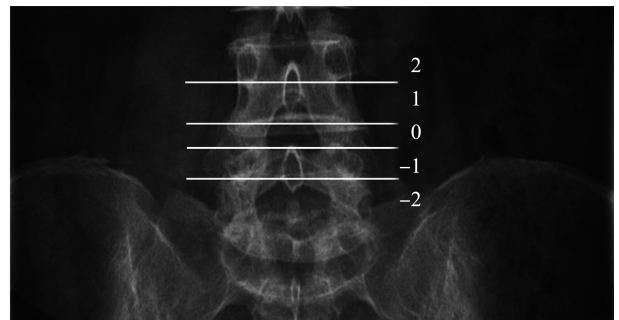


图3 腰椎 DR 正位上的髂嵴高度分级
 Figure 3 The height of the iliac crest was graded in the positive position of the lumbar spine DR

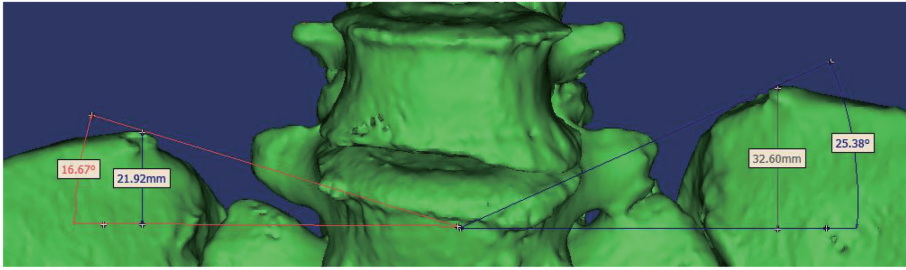


图4 腰椎-髂嵴3D模型髂嵴高度和髂嵴倾斜角测量

Figure 4 The height of the iliac crest and the inclination angle of the iliac crest were measured on a 3D model of the lumbar spine and iliac crest

1.2.5 关节突倾斜角

建立的 PETD 手术通道 3D 模型路径经过 S1 关节突上顶点,在矢状位图像上,通道与水平面夹角

即为关节突上顶点与水平面的夹角,定义此角度为关节突倾斜角。见图5。

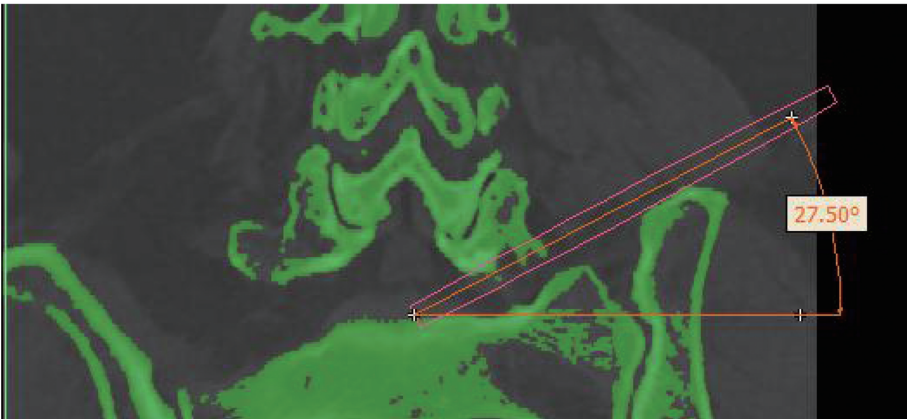


图5 在矢状位 CT 上测量通道与水平面的夹角,定义为关节突倾斜角

Figure 5 The angle between the channel and the horizontal plane was measured on the sagittal CT, which was defined as the articular process tilt angle

1.2.6 髂嵴单侧距离、髂嵴内聚角及测量方法

在腰椎 DR 正位图像上,定义髂嵴最高点到 S1 椎体后上缘中点所在矢状面的距离为髂嵴单侧距离,

S1 椎体后上缘中点所在水平面与髂嵴的交点到髂嵴最高点的连线 L,L 与水平面的夹角为髂嵴内聚角。采用 Surgimap 软件对上述数据进行测量统计。见图6。

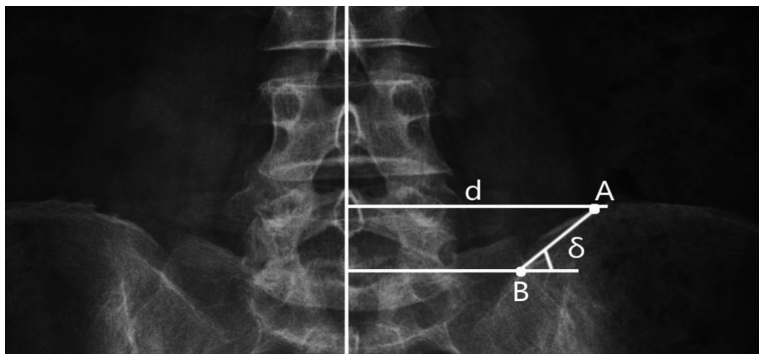


图6 在腰椎 DR 正位图上测量髂嵴最高点到中线距离以及髂嵴内聚角

Figure 6 The distance from the highest point of the iliac crest to the middle line and the internal polyangle of the iliac crest on the positive position map of the lumbar spine DR were measured

1.3 统计学处理

采用 SPSS 26.0 统计学软件,所有定量数据采用 Komogorov-Smirnov 法检验,不符合正态分布,故均用中位数和四分位数间距表达集中趋势与离散程度。两组间定量数据差异采用曼-惠特尼检

验,两组间性别差异采用卡方检验,经检验两组间差异有统计学意义的定量数据行二元 Logistic 回归分析。采用 ROC 曲线求定量数据的截断值。 $P < 0.05$ 为差异有统计学意义。

2 结果

2.1 一般临床资料比较

两组患者年龄、身高均差异无统计学意义 ($P>0.05$)。不可放置通道组体质量高于可放置通道组,差异有统计学意义 ($P=0.011$)。不可放

置通道组男患者高于可放置通道组 ($P=0.029$)。见表1。

2.2 髂嵴相关解剖学参数对于通道放置的影响

可放置通道组髂嵴高度、髂嵴倾斜角明显低于不可放置通道组 ($P<0.001$),髂嵴内聚角也更小 ($P=0.003$)。两组间关节突倾斜角、髂嵴单侧距离差异无统计学意义 ($P>0.05$)。见表2。

表1 一般临床资料的比较

Table 1 Comparison of general clinical data

临床资料	可放置通道组	不可放置通道组	<i>P</i>
例数	61	14	
男/女	24/37	10/4	0.029
年龄/岁	51.00(55.00~40.50)	53.50(57.25~39.25)	0.491
身高/cm	165.00(176.00~162.00)	172.00(175.25~161.50)	0.789
体质量/kg	68.00(75.00~65.00)	77.00(82.00~67.25)	0.011

表2 两组之间髂嵴相关参数测量结果的比较

Table 2 Comparison of measurements of iliac crest-related parameters between the two groups

组别	髂嵴高度/mm	髂嵴倾斜角/°	关节突倾斜角/°	髂嵴单侧距离/mm	髂嵴内聚角/°
可放置通道组	23.65 (29.33~18.50)	20.20 (24.30~16.08)	29.40 (32.53~24.58)	73.00 (77.75~70.10)	45.35 (48.03~40.70)
不可放置通道组	38.20 (39.80~34.40)	29.15 (31.98~26.65)	29.75 (31.83~28.38)	72.55 (78.38~68.83)	47.75 (49.98~45.33)
<i>P</i>	<0.001	<0.001	0.274	0.778	0.003

2.3 不同髂嵴高度的通道放置成功率差异

髂嵴高度分级为-1、-2、0、1级的患者,通道放置成功率分别为100%、100%、98.4%、87.9%,而在髂嵴高度2级的患者中,通道放置成功率仅为10%。见表3。

表3 不同髂嵴高度分级通道放置成功率的比较

Table 3 Comparison of success rates for channel placement at different iliac crest altitudes

髂嵴高度分级	可放置通道组/n	不可放置通道组/n	成功率/%
-2	8	0	100
-1	26	0	100
0	62	1	98.4
1	29	4	87.9
2	2	18	10

2.4 通道放置成功相关指标的回归分析

对两组间差异有统计学意义的定量数据和一般临床资料进行回归分析,结果显示,髂嵴高度(1.547, $P<0.001$)、髂嵴倾斜角(1.599, $P<0.001$)、髂嵴内聚角(1.108, $P=0.009$)、体质量(1.111, $P=0.010$)、性别(3.854, $P=0.037$)的比值比均与通道放置成功显著相关。见图7。

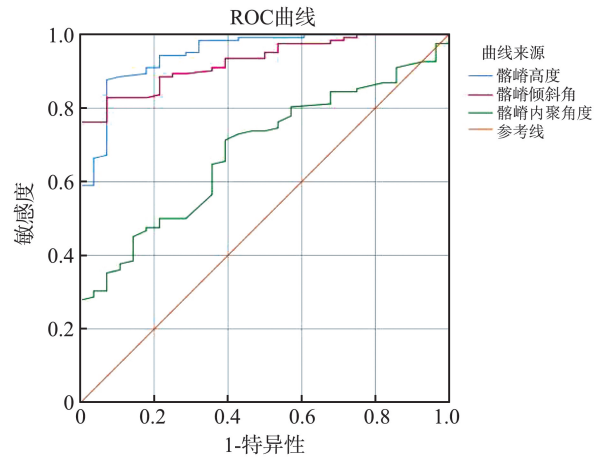


图7 髂嵴相关参数的ROC曲线

Figure 7 ROC curve of related parameters of iliac crest

3 讨论

腰椎间盘突出症作为脊柱外科最常见的疾病,保守治疗的效果欠佳,对患者造成了严重的心理和经济负担。自上世纪70年代Yasargil首次使用内窥镜技术切除突出椎间盘以来,微创手术的技术不断发展,逐渐成为外科治疗腰椎间盘突出症的首选^[8-9]。本研究选择脊柱微创术式中最常用的

PETD 作为手术方式,其相较于传统手术方式具有明显的优势,创伤小、对脊柱稳定性影响小、术后恢复快、并发症少^[10-12],但由于髂嵴、肥大的关节突等骨性结构的阻碍,L5~S1 节段的手术在建立通道时可能失败^[13-14],因此本研究通过术前 CT 影像三维重建模拟通道放置的成功率,并由此评估髂嵴相关空间结构对放置通道的影响。

安全、准确地建立通道是 PETD 手术成功的关键。髂嵴是穿刺路径上产生阻碍的主要结构,“高髂嵴”为 PETD 手术带来了难度,加重了患者的心理负担^[14]。Song 等^[15]提出高髂嵴患者术后恢复效果不如低髂嵴患者,由于手术难度大,时间长,有时还需借助椎间孔成形,增加了术中出血量和术中神经损伤的风险^[16]。为避免高髂嵴对手术的不利影响,魏景超等^[17]采用改良手术俯卧位以降低患侧髂嵴相对高度,改善高髂嵴对手术带来的不便。Yang 等^[18]提出了一种基于双平面斜位透视新型的腰髂三角技术,解决高髂嵴患者通道难以放置的问题。但是,目前临床上术前评估髂嵴高度主要依靠 X 线,缺乏对于髂嵴空间结构的三维分析,因此,本研究依靠 CT 图像重建,从三维图像上分析髂嵴的各项参数对于通道放置的影响。根据模拟通道放置的结果将所有患者分为可放置通道组和不可放置通道组,结果显示两组之间的髂嵴高度、髂嵴倾斜角以及髂嵴内聚角均存在差异,在不可放置通道患者当中,髂嵴的高度更高;髂嵴倾斜角与髂嵴内聚角可以量化髂嵴的“陡峭”程度,两者越大,说明髂嵴越陡峭。回归分析结果也说明了越高、越陡峭的髂嵴在穿刺放置通道时越困难。根据 ROC 曲线的结果(图 7),髂嵴高度小于 31.95 mm,髂嵴倾斜角在 24.35° 以下,髂嵴内聚角小于 47.2° 时,通道放置的成功率会更高。根据 Choi 等^[19]研究,将髂嵴高度分级为 2 级的定义为高髂嵴,其他为低髂嵴,结果显示,随着髂嵴高度分级的升高,通道放置的成功率越来越低,定义为“高髂嵴”患者放置通道的成功率仅有 10%。表明髂嵴高度是影响 L5~S1 节段的 PETD 手术成功与否的关键。除此之外,本研究比较了两组患者的一般临床资料,结果显示,在不可放置通道组中,体质量更大,说明越胖的患者在穿刺建立通道时越有难度,与本研究临床工作经验相吻合;男患者比例更高,与先天的骨盆发育差异有关,由于生育功能的原因,女性骨盆宽阔,导致了更加平缓的髂嵴与骶骨之间的角度^[20-21]。因此,对于高髂嵴的女患者,可以尝试进行穿刺,而对男患者则需要谨慎考虑,高髂嵴患者合并肥胖时往往更难穿刺成功,可以考虑采

用适应证更广的椎板间入路^[22]。

目前,临床上缺乏全面精准的 PETD 术前评估手段,依靠 CT 及 X 线二维图像,易产生偏差。同时,由于缺乏良好的术前规划,手术医生面临更长时间的辐射暴露及多次穿刺的风险,增加了患者的痛苦^[23-24]。EUN 等^[25]提出在斜矢状位 MRI 上面评估穿刺置管的可行性,提升了术前评估的精确性。由于腰椎-骶骨的立体空间结构,基于三维模型才能够更加准确地评估各种骨性结构的阻挡。本研究基于患者的腰椎 CT 图像进行了三维重建,并以此为基础进行通道模拟与数据测量,提高了术前预测的准确性、可靠性,结果显示,绝大部分“低髂嵴”的患者都可以在术前预测中成功放置通道,与临床经验和既往研究结果一致。本研究结果显示,并不是所有的“高髂嵴”患者都不能成功穿刺建立通道。已有研究证明 L5~S1 节段在体位变动时的相对位置关系保持恒定不变^[26-27],所以在仰卧位 CT 获得的数据同样可以为手术时的俯卧位提供参考。本研究能够结合患者术前影像学检查运用于临床,为高髂嵴患者进行更为精准的术前评估,避免因穿刺不成功给患者带来的痛苦和心理负担;另一方面,术前模拟成功,可以帮助手术医生选择适当的穿刺路径,提高穿刺成功率,缩短辐射暴露时间^[22]。

本研究局限性在于临床样本量较少,选用的均为无脊柱畸形的标准化患者,实际临床应用时还存在部分因为疼痛导致的姿势性侧凸或后凸的患者,没有考虑腰椎骶化或骶椎腰化等存在移行椎的特殊情况。本研究忽略了体位变动带来的影响,将在进一步研究中筛选出在仰卧位不能穿刺却可以在俯卧位手术体位进行穿刺的患者,从而增加手术的适应证。

综上所述,本研究基于腰椎 CT 的三维重建模型,评估髂嵴对于 L5~S1 节段行 PETD 手术时通道建立的影响,提供准确有效的术前评估手段,帮助手术医生选择合适的手术方案及穿刺路径,具有较高的临床实际应用价值。

参考文献:

- [1] Martin MD, Boxell CM, Malone DG. Pathophysiology of lumbar disc degeneration: a review of the literature[J]. Neurosurg Focus, 2002, 13(2): E1.
- [2] Benoist M. The natural history of lumbar disc herniation and radiculopathy[J]. Joint Bone Spine, 2002, 69(2): 155-160.
- [3] 中华医学会骨科学分会脊柱外科学组, 中华医学会骨

- 科学分会骨科康复学组. 腰椎间盘突出症诊疗指南[J]. 中华骨科杂志, 2020, 40(8): 477-487.
- Chinese Orthopedic Association of Spine Surgery Group, Chinese Orthopaedic Association of Orthopedic Rehabilitation Group. Clinical practice guideline for diagnosis and treatment of lumbar disc herniation[J]. Chinese Journal of Orthopaedics, 2020, 40(8): 477-487.
- [4] Pan M, Li Q, Li S. Percutaneous endoscopic lumbar discectomy: indications and complications[J]. Pain Physician, 2020, 23(1): 49-56.
- [5] Wang ZW, Chen Z, Wang K. Percutaneous endoscopic transforaminal discectomy for L5-S1 disc herniation[J]. National Medical Journal of China, 2020, 100(4): 270-273.
- [6] Shen SC, Chen HC, Tsou HK. Percutaneous endoscopic lumbar discectomy for L5-S1 disc herniation based on image analysis and clinical findings; a retrospective review of 345 cases[J]. Medicine (Baltimore), 2023, 102(5): e32832.
- [7] Wang YL, Wang XY, Fang BD. L5-S1 disc degeneration and the anatomic parameters of the iliac crest: imaging study[J]. Eur Spine J, 2015, 24(11): 2481-2487.
- [8] Postacchini F, Postacchini R. Operative management of lumbar disc herniation: the evolution of knowledge and surgical techniques in the last century[J]. Acta Neurochir Suppl, 2011, 108: 17-21. doi: 10.1007/978-3-211-99370-5_4.
- [9] 邱贵兴. 腰椎疾患诊治新进展[J]. 山东大学学报(医学版), 2019, 57(5): 1-2.
- Qiu Guixing. Research progress in the diagnosis and treatment of lumbar disease[J]. Journal of Shandong University (Health Sciences). 2019, 57(5): 1-2.
- [10] 邹明翔, 周其佳, 左松球. 经皮椎间孔镜治疗腰椎间盘突出症的临床疗效分析[J]. 世界复合医学, 2020, 6(11): 41-43.
- ZOU Mingxiang, ZHOU Qijia, ZUO Songqiu. Analysis of the clinical efficacy of percutaneous intervertebral foraminoscope in the treatment of lumbar disc herniation[J]. World Journal of Complex Medicine, 2020, 6(11): 41-43.
- [11] Gadjradj PS, Harhangi BS. Full-endoscopic transforaminal discectomy versus open microdiscectomy for sciatica: update of a systematic review and meta-analysis[J]. Spine (Phila Pa 1976), 2022, 47(18): E591-E594.
- [12] Gadjradj PS, Harhangi BS, Amelink J. Percutaneous transforaminal endoscopic discectomy versus open microdiscectomy for lumbar disc herniation: a systematic review and meta-analysis[J]. Spine (Phila Pa 1976), 2021, 46(8): 538-549.
- [13] Wang Z, Chen Z, Wu H. Treatment of high-iliac-crest L5-S1 lumbar disc herniation via a transverse process endoscopic transforaminal approach[J]. Clin Neurol Neurosurg, 2020, 197: 106087. doi: 10.1016/j.clineuro.2020.106087.
- [14] Chen KT, Wei ST, Tseng C. Transforaminal endoscopic lumbar discectomy for L5-s1 disc herniation with high iliac crest: technical note and preliminary series[J]. Neurospine, 2020, 17(Suppl 1): S81-S87.
- [15] Song QC, Zhao Y, Li D. Percutaneous endoscopic transforaminal discectomy for the treatment of L5-S1 lumbar disc herniation and the influence of iliac crest height on its clinical effects[J]. Exp Ther Med, 2021, 22(2): 866.
- [16] Wang D, Xie W, Cao W. A cost-utility analysis of percutaneous endoscopic lumbar discectomy for L5-s1 lumbar disc herniation: transforaminal versus interlaminar[J]. Spine (Phila Pa 1976), 2019, 44(8): 563-570.
- [17] 魏景超, 高尚聚, 李文毅, 等. 改良俯卧位下经皮椎间孔镜手术治疗合并高髂嵴的L5~S1椎间盘突出症疗效分析[J]. 中国骨与关节损伤杂志, 2020, 35(7): 735-737.
- WEI Jingchao, GAO Shangju, LI Wenyi. Clinical analysis of improved prone position percutaneous transforaminal endoscopic surgery for L5S1 disc herniation with high iliac crest[J]. Chinese Journal of Bone and Joint Injury, 2020, 35(7): 735-737.
- [18] Yang JS, Liu KX, Kadimcherla P. Can the novel lumboiliac triangle technique based on biplane oblique fluoroscopy facilitate transforaminal percutaneous endoscopic lumbar discectomy for patients with L5-S1 disc herniation combined with high iliac crest? case-control study of 100 patients[J]. Pain Physician, 2020, 23(3): 305-314.
- [19] Choi KC, Park CK. Percutaneous endoscopic lumbar discectomy for L5-S1 disc herniation: consideration of the relation between the iliac crest and L5-S1 disc[J]. Pain Physician, 2016, 19(2): E301-E308.
- [20] Konishi R, Ozawa J, Kuniki M. Sex differences in pelvis, thigh, and shank coordination during walking[J]. J Biomech, 2024, 162: 111891. doi: 10.1016/j.jbiomech.2023.111891.
- [21] Fischer B, Grunstra N, Zaffarini E. Sex differences in the pelvis did not evolve de novo in modern humans[J]. Nat Ecol Evol, 2021, 5(5): 625-630.
- [22] 王冰. 腰椎完全内镜经椎板间入路技术的临床教程[J]. 山东大学学报(医学版), 2019, 57(5): 23-29.
- Wang Bing. A clinical guideline of full-endoscopic lumbar interlaminar approach techniques[J]. Journal of Shandong University (Health Sciences), 2019, 57(5): 23-29.
- [23] Arif S, Brady Z, Enchev Y. Minimising radiation exposure to the surgeon in minimally invasive spine surgeries;

- a systematic review of 15 studies[J]. *Orthop Traumatol Surg Res*, 2021, 107(7): 102795.
- [24] Erken HY, Yilmaz O. Collimation reduces radiation exposure to the surgeon in endoscopic spine surgery: a prospective study[J]. *J Neurol Surg A Cent Eur Neurosurg*, 2022, 83(1): 6-12.
- [25] Eun SS, Lee SH, Liu WC. A novel preoperative trajectory evaluation method for L5-S1 transforaminal percutaneous endoscopic lumbar discectomy[J]. *Spine J*, 2018, 18(7): 1286-1291.
- [26] Stephens GC, Yoo JU, Wilbur G. Comparison of lumbar sagittal alignment produced by different operative positions[J]. *Spine (Phila Pa 1976)*, 1996, 21(15): 1802-1806.
- [27] Chin KR, Kuntz AF, Bohlman HH. Changes in the iliac crest-lumbar relationship from standing to prone [J]. *Spine J*, 2006, 6(2): 185-189.
- (编辑:徐苗蓁)
-
- (上接第 41 页)
- [23] 孔学军, 柴青芬, 郭科, 等. 成人卵圆孔未闭超声检查及右心声学造影分析[J]. *中华医学杂志*, 2017, 97(43): 3380-3383.
- KONG Xuejun, CHAI Qingfen, GUO Ke, et al. Analysis of contrast echocardiography for detecting right to left shunt in adults with patent foramen ovale[J]. *National Medical Journal of China*, 2017, 97(43): 3380-3383.
- [24] Zhang HQ, Huang WY, Lan TY, et al. The value of contrast-enhanced transesophageal echocardiography in the detection of cardiac right-to-left shunt related with cryptogenic stroke and migraine[J]. *Bio Med Research International*, 2020, 2020: 8845652. doi: 10.1155/2020/8845652.
- [25] 李璠, 曹媛媛, 张小用, 等. 不同状态时右心声学造影检测卵圆孔未闭右向左分流检出率的比较[J]. *心脏杂志*, 2018, 30(2): 200-202.
- LI Fan, CAO Yuanyuan, ZHANG Xiaoyong. Comparison of diagnosis values of different states in right heart contrast transthoracic echocardiography for right to left shunt in patent foramen ovale[J]. *Chin Heart J*, 2018, 30(2): 200-202.
- [26] Yang J, Zhang H, Wang Y, et al. The efficacy of contrast transthoracic echocardiography and contrast transcranial Doppler for the detection of patent foramen ovale related to cryptogenic stroke[J]. *Biomed Res Int*, 2020, 2020(2): 1-6.
- (编辑:刘霞)