

颈外动脉-桡动脉-岩骨段颈内动脉搭桥治疗 巨大高颈段动脉瘤

郭文强^{1*}, 高恺明^{2*}, 佟小光²

(1.山东大学齐鲁医院(青岛)神经外科, 山东 青岛 266035; 2.天津市环湖医院神经外科, 天津 300074)

摘要:目的 探讨巨大高颈段颈内动脉动脉瘤的治疗策略。方法 回顾性分析1例巨大高颈段颈内动脉动脉瘤患者的临床资料、手术策略及随访,回顾相关文献。结果 1例52岁男性,因“间断呛咳1年,加重伴头痛2个月”入院,DSA提示右侧巨大高颈段颈内动脉动脉瘤,行颈外动脉-桡动脉-颈内动脉岩骨段搭桥并动脉瘤孤立术,术后造影显示动脉瘤消失,桥血管通畅。术后无新发脑缺血或脑梗死,无新发神经功能障碍,原有症状显著改善。结论 对于高颈段的巨大颈内动脉动脉瘤的治疗,脑血管搭桥手术仍然是有效治疗方案之一,颈外动脉-桡动脉-岩骨段颈内动脉搭桥可以很好地处理此类病变,是理想的治疗手段。

关键词: 高颈段; 巨大动脉瘤; 颈内动脉岩骨段; 搭桥

中图分类号:R651.1

文献标志码:A

External carotid artery-to-petrous internal carotid artery radial artery graft bypass for giant high cervical aneurysm

GUO Wenqiang^{1*}, GAO Kaiming^{2*}, TONG Xiaoguang²

(1. Department of Neurosurgery, Qilu Hospital of Shandong University (Qingdao), Qingdao 266035, Shandong, China;

2. Department of Neurosurgery, Tianjin Huanhu Hospital, Tianjin 300074, China)

Abstract: Objective To investigate the treatment strategy of giant high cervical extracranial internal carotid artery aneurysm (EICAA). **Methods** The clinical data, surgical strategy and follow-up of one case were retrospectively analyzed, and the relevant literature was reviewed. **Results** A 52-year-old male was admitted to hospital due to “intermittent cough for 1 year, aggravation and headache for 2 months”. DSA showed a giant right high cervical EICAA. An external carotid artery-radial artery graft-internal carotid artery petrous segment bypass combined with aneurysm trapping was performed. There was no new cerebral ischemia or cerebral infarction after surgery, no new neurological dysfunction, and the original symptoms were significantly improved. **Conclusion** Cerebrovascular bypass surgery is still one of the effective treatment strategies for large internal carotid artery aneurysms with high cervical segments, and internal carotid artery bypass grafting in the external carotid artery-radial artery-petrous segment can effectively deal with such lesions.

Key words: High cervical portion; Giant aneurysm; Petrous segment of internal carotid artery; Bypass

颅外段颈内动脉瘤(extracranial internal carotid artery aneurysms, EICAA)比较罕见,约占所有动脉瘤的不足1%^[1-2]。虽然其破裂发生率很低,但其致残致死率依然很高,因此需要积极的手术干预。其中,又以位于颅底水平的高颈段EICAA更有挑战

性^[3-7]。尽管血管内介入治疗和血流导向装置得到了广泛的应用,脑血管搭桥手术仍然是处理此类动脉瘤的不可忽视的手段^[8]。本研究报道了1例位于颅底的巨大高颈段颅外颈内动脉瘤,采用颈外动脉-桡动脉-岩骨段颈内动脉搭桥+载瘤动脉孤立术

并最终得以治愈。

1 病例资料

患者,男性,52岁,因“间断呛咳1年,加重伴头痛2个月”入院。患者就诊于耳鼻喉科门诊,门诊检查发现右侧颈部高颈段区域有一搏动性肿物,进一步行CT检查显示右侧咽旁间隙区域的混杂密度类圆形占位。内镜检查提示咽腔黏膜下的搏动性肿物。经CTA检查证实肿物为右侧高颈段区域的颅外段颈内动脉动脉瘤,大小约 $2.4\text{ cm} \times 2.5\text{ cm} \times 3.2\text{ cm}$ 。高分辨率核磁共振检查显示右侧颈内动脉C1段巨大动脉瘤,瘤腔内血栓形成;MR灌注显示右侧侧脑室旁及半卵圆中心MTT及TTP略延迟。术前行脑血管造影及球囊闭塞试验提示前交通动脉开放,球囊闭塞试验结果为阴性(术中患者未出现神经功能障碍)。

动脉瘤位于颅底,瘤体巨大,瘤体显示不清,无法行介入手术治疗,行常规手术切除和原位吻

合损伤过大,遂决定行颈外动脉-桡动脉-岩骨段颈内动脉搭桥+载瘤动脉孤立术。仰卧位,头转向对侧,显露颈部血管备用;额颞颥开颅,磨除部分中颅底,硬膜外显露 Glasscock 三角,磨除表面的薄层骨质以显露右侧颈内动脉岩骨段,长度约1 cm。同时由手外科医生行桡动脉获取,桡动脉获取后,通过压力扩张方法冲洗并结扎细小分支后,即刻进行吻合。术中应用肝素盐水及罂粟碱盐水进行冲洗预防血栓形成。先行颈外动脉-桡动脉端端吻合,桥血管经皮下到达中颅底,行桡动脉-颈内动脉岩骨段端侧吻合,并分别在颈内动脉起始部和岩骨段颈内动脉-桡动脉吻合口近端分别置一永久动脉瘤夹以彻底孤立颈段颈内动脉。手术顺利,术后复查脑血管造影未见动脉瘤显影,桥血管通畅,颅内血管显影如前。术后复查核磁灌注提示原低灌注区灌注明显改善。患者术后情况平稳,原有症状明显减轻,无新发神经功能障碍,顺利出院。截至投稿前,术后半年,无新发神经功能症状,原有神经损伤症状基本消失。

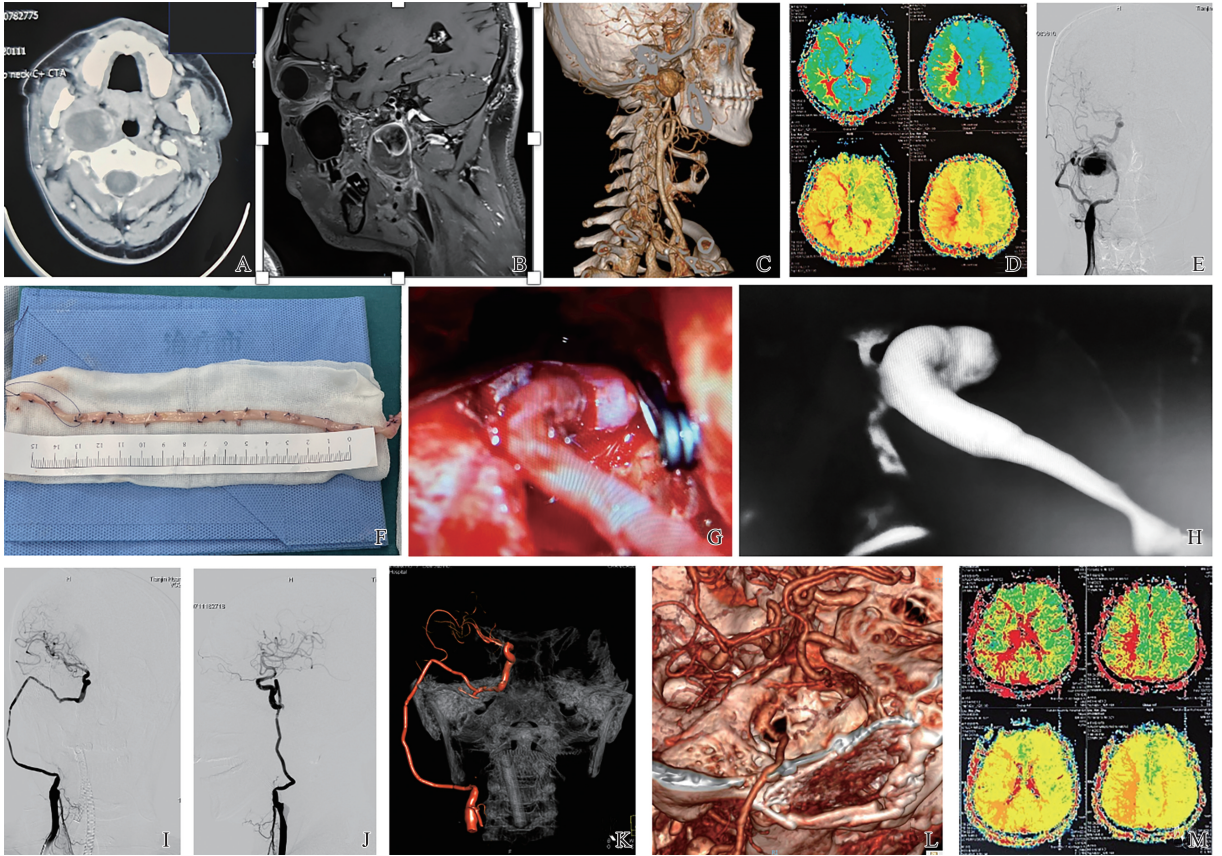


图1 患者影像资料

A: 术前CT; B: 术前高分辨率磁共振; C: 术前CTA三维重建; D: 术前磁共振灌注; E: 术前脑血管造影; F~H: 术中影像; I~K: 术后即刻脑血管造影; L: 术后CTA三维重建; M: 术后磁共振灌注。

Figure 1 Patient's imaging findings

A: Preoperative CT examination; B: Preoperative high resolution MRI; C: Preoperative 3D-CTA examination; D: Preoperative MRP; E: Preoperative DSA examination; F-H: Intraoperative image; I-K: Immediately postoperative DSA and 3D-DSA examination; L: Postoperative 3D-CTA examination; M: Postoperative MRP.

2 讨论

2.1 EICAA 是罕见疾病,有着相当的风险,需要积极治疗

颅外段颈内动脉瘤约占所有动脉瘤的不足 1%^[1-2]。其成因依然有争议,但一般认为与动脉粥样硬化、外伤、手术史、感染、放疗史、先天性疾病等相关^[2,9]。最常见的临床症状为颈部搏动性肿块及局部疼痛^[2],也可因压迫而导致饮水呛咳、吞咽困难、声音嘶哑以及 Horner 综合征等表现^[10-11]。体积较大或夹层动脉瘤可能导致缺血性脑血管病的发生^[2,11]。本研究报道的患者,主要表现为压迫症状(吞咽困难、饮水呛咳),而后在院期间(术前)表现出了缺血症状(肢体麻木无力)。因此,此类患者仍需要积极的治疗。

颅外段颈内动脉瘤目前尚无统一的指南或共识,一般认为,手术治疗是首选^[12-13]。1805年,Cooper 教授报道了第 1 例颅外段颈动脉瘤,应用颈动脉结扎手术对其进行了治疗,开启了颅外段颈动脉瘤治疗的先河^[14]。直到 20 世纪 50 年代,颈动脉结扎术仍是颅外段颈动脉瘤的首选手术治疗方式^[2]。随着外科技术和血管内技术发展,该治疗方案逐渐被其他方案所替代^[2,15-16]。

2.2 手术修复仍然是目前治疗此类疾病的金标准^[13]

1952年,Dimitza 教授^[17]首次进行颅外段颈动脉瘤的切除及端端血管吻合,获得成功;1959年,Beall 等^[18]首次进行颅外段颈动脉瘤切除并应用人工血管进行颈动脉重建,取得成功。进行此类手术的关键在于动脉瘤瘤体、瘤颈以及远端正常颈内动脉的显露。当动脉瘤位于高颈段接近颅底时,常规的颈部手术已无法获得满意的显露^[19],需要侧颅底技术的支持^[20-21]。1978年,Fisch 教授^[20]报道了颞下窝入路并将之应用于高颈段动脉瘤或高颈段颅底占位的手术治疗,但存在听力丧失和包括面神经、后组颅神经在内的神经功能损伤等风险^[12]。

2.3 血管内介入治疗是有价值的,但也是有选择性的,同样存在相当的风险

随着血管内治疗技术和材料的进步,越来越多的颅外段动脉瘤可以通过血管内的方法治疗^[22-24]。对于高颈段动脉瘤来说,常规开放手术显露动脉瘤及远端颈内动脉尤为困难,且存在损伤颅神经的风险^[12]。血管内治疗可以获得满意的效果,但远期效果仍需要严密随访观察。血管内治疗也存在相应的风险。Li 等^[25]报道了包括 224 例患者共 113 个研

究,总的卒中发生率为 1.8%,颅神经损伤率为 0.5%,院内死亡率为 4.1%,长期随访后约 4.7%的病例需要再次介入手术,2.4%的病例转为开放性手术,晚期并发症率为 11.7%。对于颈动脉极其迂曲、弯折的病例以及主动脉弓或颈总动脉迂曲或疾病的病例,血管内治疗也是极其困难的。血管内治疗也受介入材料的影响^[22]。在本研究报道的这一病例中,动脉瘤位于高颈段近颅底区域,载瘤动脉迂曲和动脉瘤体巨大伴瘤腔内大量血栓形成是我们常规开放手术的难点,同时这也是 DSA 中无法清晰显示瘤颈的原因之一,而这也促使我们最终选择行血管搭桥+载瘤动脉闭塞术。

2.4 脑血管搭桥在处理此类疾病中优势明显,尤其是颈外动脉-桡动脉-岩骨段颈内动脉搭桥

高颈段动脉瘤的开放手术存在非预期栓塞、远端控制困难、周围结构损伤、神经损伤等风险^[13],同时血管内治疗技术无法处理瘤体巨大、瘤颈显示不清的动脉瘤。因此,对于高颈段动脉瘤,本研究更主张以搭桥结合载瘤动脉闭塞以彻底替代血流并完全孤立动脉瘤,而不是直接处理动脉瘤。

颅内外血管搭桥技术是治疗颈动脉闭塞性疾病的经典术式,在早期作为颈动脉闭塞术的补充,虽然早期较少的经验证实辅助性搭桥并没有阻止因闭塞颈动脉而导致缺血事件的发生,但这依然不能否认搭桥血流重建结合颈内动脉闭塞在治疗颈内动脉动脉瘤中的作用^[26-27]。

本研究推测,早期的颅内外血管搭桥对于流量的把握不足导致了不良事件的高发生率,因此,对于高颈段动脉瘤的搭桥血流重建手术,本研究建议采用高流量搭桥以恢复正常血流。颅外-颅内(extracranial-Intracranial, EC-IC)高流量搭桥已被诸多文献证实了其在处理颈内动脉系统动脉瘤的重要作用^[28-30]。但对于高颈段动脉瘤,尤其是位于岩骨段颈内动脉以下起源的动脉瘤,此类搭桥的受血血管位于颈内动脉 C7 段或者大脑中动脉 M2 段,手术难度高,仍然存在缺血或栓塞风险^[29]。因此如何在尽可能不开颅的情况下恢复顺向的血流成为了目标。

Fisch 等^[20-21]在 1980 年开创了颈内动脉岩骨段显露的先河。此后,诸多医师尝试经由此路径进行了颈段和岩段颈内动脉的修复和搭桥手术操作,并取得了理想的治疗效果^[31-32]。尽管无需开颅,但存在听力丧失和颅神经功能损伤的风险^[12]。另外的一些缺点包括咽鼓管功能的损伤和鼓索神经的损伤^[12]。

相较于上述过程,Miyazaki 等^[33-34]通过中颅底的切除来显露岩骨段颈内动脉,方便了以此为基础

的搭桥手术,而 Fitzpatrick 等^[35]在 Glasscock^[31]和 Sekhar 等^[32]研究的基础上,对上述方法进行了改良,磨除少量中颅底的骨质,即可在硬膜外达成约 1 cm 的岩段颈内动脉水平段的显露,足够接下来的搭桥操作。本研究中使用该暴露方法,将岩骨段颈内动脉水平段作为受血段,将同侧颈外动脉作为供血段,通过皮下隧道使用桡动脉连接到一起,完成吻合后再完全孤立受累段颈内动脉。这一过程完全是硬膜外的操作,对颅内血流的影响达到了最小,而最终的血流方向也是顺向血流。相较于将颈段颈内动脉作为供血血管,本研究中的步骤仅进行了一次颈内动脉的阻断,进一步降低了缺血发生的可能。

综上所述,对于巨大高颈段颈内动脉动脉瘤,脑血管搭桥仍然是有效的治疗方案之一。颈外动脉-桡动脉-岩骨段颈内动脉搭桥结合载瘤动脉孤立术可以很好地处理高颈段或颅底的血管病变。这一操作完全是硬膜外的,能够用较短的桡动脉,将受累颈内动脉完全孤立循环外,同时作为一种顺向的高流量搭桥,对颅内影响小,治疗效果确切,值得进一步研究和推广。

参考文献:

- [1] Théry M, Ziza V. Symptomatic extracranial internal carotid artery aneurysm deferred repair [J]. *J Med Vasc*, 2023, 48(2): 84-87.
- [2] Sharma RK, Asiri AM, Yamada Y, et al. Extracranial internal carotid artery aneurysm - challenges in the management; a case report and review literature [J]. *Asian J Neurosurg*, 2019, 14(3): 970-974.
- [3] Giannopoulos S, Trinidad E, Aronow H, et al. Endovascular repair of extracranial carotid artery aneurysms: a systematic review[J]. *Vasc Endovascular Surg*, 2020, 54(3): 254-263.
- [4] Jin J, Liu Y, Shen X, et al. Endovascular and hybrid interventions for extracranial juxta-skullbase carotid artery aneurysms: experience and long-term results[J]. *J Stroke Cerebrovasc Dis*, 2021, 30(4): 105611. doi: 10.1016/j.jstrokecerebrovasdis.2021.105611.
- [5] Radak D, Davidovic L, Vukobratov V, et al. Carotid artery aneurysms: Serbian multicentric study[J]. *Ann Vasc Surg*, 2007, 21(1): 23-29.
- [6] Choi E, Gwon JG, Kwon SU, et al. Management strategy for extracranial carotid artery aneurysms: a single-center experience[J]. *Medicine (Baltimore)*, 2022, 101(19): e29327. doi: 10.1097/MD.00000000000029327.
- [7] Xue S, Tang X, Zhao G, et al. Contemporary outcomes of open and endovascular intervention for extracranial carotid artery aneurysms: a single centre experience[J]. *Eur J Vasc Endovasc Surg*, 2020, 60(3): 347-354.
- [8] Hoffman ME, Squiers JJ, Hamandi M, et al. Systematic review of the influence of anatomy and aneurysm type on treatment choice and outcomes in extracranial carotid artery aneurysm[J]. *Ann Vasc Surg*, 2022, 83: 349-357. doi: 10.1016/j.avsg.2022.02.006.
- [9] Sfyroeras GS, Nikolopoulou EA, Moulakakis KG, et al. Extracranial internal carotid artery aneurysm in a patient with marfan syndrome [J]. *Ann Vasc Surg*, 2019, 57(273): 7-10.
- [10] Mikhaïlov MS, Rideli VI, Musaev AB. Surgical treatment of an extracranial aneurysm of the internal carotid artery[J]. *Angiol Sosud Khir*, 2020, 26(3): 167-171.
- [11] 杨燎, 陈忠, 王盛. 颅外段颈动脉瘤的外科治疗体会 [J]. *心肺血管病杂志*, 2020, 39(13): 1373-1375. YANG Liao, CHEN Zhong, WANG Sheng. Surgical treatment of extracranial carotid artery aneurysm [J]. *Journal of Cardiovascular & Pulmonary Diseases*, 2020, 39(13): 1373-1375.
- [12] Mukherjee P, Huilgol R, Graham A, et al. Open and endovascular repair of aneurysms affecting the distal extracranial internal carotid artery: case series[J]. *J Laryngol Otol*, 2016, 130 (Suppl 4): 29-34. doi: 10.1017/S0022215116000694.
- [13] Koketsu K, Kim K, Ideguchi M, et al. High-flow bypass surgery using a radial artery graft for an extracranial internal carotid artery aneurysm: Case reports and literature review[J]. *Surg Neurol Int*, 2021, 12:333. doi: 10.25259/SNI_408_2021.
- [14] Srivastava SD, Eagleton MJ, O'Hara P, et al. Surgical repair of carotid artery aneurysms: a 10-year, single-center experience[J]. *Ann Vasc Surg*, 2010, 24(1): 100-105.
- [15] 蒲佐, 倪冷. 颅外段颈动脉瘤的腔内诊疗进展[J]. *血管与腔内血管外科杂志*, 2021, 7(6): 712-715. PU Zuo, NI Leng. Advances in endovascular diagnosis and treatment of extracranial carotid aneurysms[J]. *Journal of Vascular and Endovascular Surgery*, 2021, 7(6): 712-715.
- [16] Choi E, Gwon JG, Kwon SU, et al. Management strategy for extracranial carotid artery aneurysms: a single-center experience[J]. *Medicine (Baltimore)*, 2022, 101(19): e29327. doi: 10.1097/MD.00000000000029327.
- [17] Dimtza A. Aneurysms of the carotid arteries; report of two cases[J]. *Angiology*, 1956, 7(3): 218-227.
- [18] Beall AC Jr, Crawford ES, Cooley DA, et al. Extracranial aneurysms of the carotid artery. Report of seven cases [J]. *Postgrad Med*, 1962, 32: 93-102. doi: 10.

- 1080/00325481.1962.11692659.
- [19] Hamasaki R, Yanagisawa T, Takahashi Y, et al. Surgical treatment of cervical carotid artery aneurysm [J]. *No Shinkei Geka*, 2017, 45(8): 677-683.
- [20] Fisch U. Infratemporal fossa approach to tumours of the temporal bone and base of the skull [J]. *J Laryngol Otol*, 1978, 92(11): 949-967.
- [21] Fisch UP, Oldring DJ, Senning A. Surgical therapy of internal carotid artery lesions of the skull base and temporal bone [J]. *Otolaryngol Head Neck Surg* (1979), 1980, 88(5): 548-554.
- [22] Angioletta D, Pulli R, Marinazzo D, et al. Surgical and endovascular treatment of extracranial carotid artery aneurysms; early and long-term results of a single center [J]. *Ann Vasc Surg*, 2014, 28(3): 659-664.
- [23] Akinduro OO, Gopal N, Hasan TF, et al. Pipeline embolization device for treatment of extracranial internal carotid artery pseudoaneurysms: a multicenter evaluation of safety and efficacy [J]. *Neurosurgery*, 2020, 87(4): 770-778.
- [24] Zaidi ST, George MJ, Cambiaghi T, et al. Transcarotid stenting of extracranial carotid artery aneurysm with covered stents and flow reversal [J]. *J Vasc Surg Cases Innov Tech*, 2023, 9(4): 101347. doi: 10.1016/j.jvscit.2023.101347.
- [25] Li Z, Chang G, Yao C, et al. Endovascular stenting of extracranial carotid artery aneurysm: a systematic review [J]. *Eur J Vasc Endovasc Surg*, 2011, 42(4): 419-426.
- [26] Heros RC. Thromboembolic complications after combined internal carotid ligation and extra-to-intracranial bypass [J]. *Surg Neurol*, 1984, 21(1): 75-79.
- [27] Li FD, Gao ZQ, Ren HL, et al. Pre-reconstruction of cervical-to-petrous internal carotid artery: an improved technique for treatment of vascular lesions involving internal carotid artery at the lateral skull base [J]. *Head Neck*, 2016, 38 (Suppl 1): E1562-567. doi: 10.1002/hed.24279.
- [28] Wang X, Han G, Wang H, et al. Cerebral revascularization for complex middle cerebral artery aneurysms: surgical strategies and outcomes in a single center [J]. *Neurosurg Rev*, 2023, 46(1): 68.
- [29] Sia SF, Morgan MK. High flow extracranial-to-intracranial brain bypass surgery [J]. *J Clin Neurosci*, 2013, 20(1): 1-5.
- [30] Peeters SM, Colby GP, Kim WJ, et al. Proximal internal carotid artery occlusion and extracranial-intracranial bypass for treatment of fusiform and giant internal carotid artery aneurysms [J]. *World Neurosurg*, 2023, 180: e494-e495. doi: 10.1016/j.wneu.2023.09.097.
- [31] Glasscock ME 3rd, Smith PG, Bond AG, et al. Management of aneurysms of the petrous portion of the internal carotid artery by resection and primary anastomosis [J]. *Laryngoscope*, 1983, 93(11 Pt 1): 1445-1453.
- [32] Sekhar LN, Schramm VL Jr., Jones NF, et al. Operative exposure and management of the petrous and upper cervical internal carotid artery [J]. *Neurosurgery*, 1986, 19(6): 967-982.
- [33] Miyazaki S, Fukushima T, Fujimaki T. Resection of high-cervical paraganglioma with cervical-to-petrous internal carotid artery saphenous vein bypass. Report of two cases [J]. *J Neurosurg*, 1990, 73(1): 141-146.
- [34] Spetzler RF, Fukushima T, Martin N, et al. Petrous carotid-to-intradural carotid saphenous vein graft for intracavernous giant aneurysm, tumor, and occlusive cerebrovascular disease [J]. *J Neurosurg*, 1990, 73(4): 496-501.
- [35] Fitzpatrick BC, Spetzler RF, Ballard JL, et al. Cervical-to-petrous internal carotid artery bypass procedure. Technical note [J]. *J Neurosurg*, 1993, 79(1): 138-141.

(编辑:张彩凤)