

# 181例阴道镜病理诊断宫颈原位腺癌的典型图像特征及阴道镜漏诊原因分析

李清<sup>1</sup> 陈丽梅<sup>1</sup> 张宏伟<sup>1</sup> 王瑛<sup>1</sup> 汪清<sup>1</sup> 隋龙<sup>1</sup> 丛青<sup>1</sup> 华克勤<sup>2△</sup>

(<sup>1</sup>复旦大学附属妇产科医院宫颈疾病诊疗中心, <sup>2</sup>妇科 上海 200090)

**【摘要】** 目的 通过剖析阴道镜术后宫颈原位腺癌(adenocarcinoma *in situ*, AIS)病例及典型阴道镜图像,分析阴道镜诊断漏诊原因,以降低漏诊率,为临床诊治提供更有力的指导。方法 回顾性分析2019年1月—2023年12月期间在复旦大学附属妇产科医院收治的AIS患者的临床资料,纳入的患者均经阴道镜检查并经病理确诊。收集患者的年龄、细胞学检查结果、人乳头瘤病毒(human papilloma virus, HPV)检测结果、阴道镜图像、阴道镜诊断以及病理结果。有本院宫颈环形电切(loop electrosurgical excision procedure, LEEP)病理的患者另外纳入LEEP手术后的病理报告。结果 共纳入181例阴道镜病理诊断AIS的患者,平均年龄为40.62岁。46.4%的患者细胞学正常或未见上皮内病变或恶性,17.1%的患者细胞学为非典型腺细胞或AIS,84.5%的患者HPV 16/18阳性。阴道镜漏诊率为45.3%[阴道镜诊断为炎症/低级别鳞状上皮内病变(low-grade squamous intraepithelial lesion, LSIL)]。重新复核阴道镜图片,发现较为突出的征象为:醋白上皮、柱状上皮改变(特征1为涂醋前柱状上皮呈暗红色矮颗粒状改变,涂醋后柱状上皮局灶或弥漫性醋白改变,绒毛隆起;特征2为融合的柱状上皮,粗大、隆起、水肿,表面醋白),非典型血管,异常腺开口。进一步对82例漏诊病例进行分析,24%为视野不清、分泌物遮挡,44%为缺少对典型特征的认识。阴道镜漏诊病例(诊断炎症/LSIL)中细胞学正常占比57.3%,细胞学>LSIL占比22.0%,未漏诊病例[诊断高级别鳞状上皮内病变(high-grade squamous intraepithelial lesion, HSIL)/AIS/癌]中细胞学正常占比37.4%,细胞学>LSIL占比38.4%。两组差异有统计学意义。分析病灶位置发现,在阴道镜漏诊病例中,26.8%的AIS病变仅见于宫颈管搔刮标本,显著高于未漏诊组的6.1%。结论 本研究总结了AIS五大典型征象,发现阴道镜漏诊的主要原因是视野不清和对典型征象认识不足。漏诊病例中仅存在于宫颈管搔刮标本的AIS的占比高达26.8%。建议加强对典型图像特征的认识、优化阴道镜视野,并重视宫颈管搔刮,以降低阴道镜诊断AIS的漏诊率。

**【关键词】** 宫颈; 原位腺癌; 阴道镜; 漏诊

**【中图分类号】** R737.33 **【文献标志码】** A **doi:** 10.3969/j.issn.1672-8467.2026.01.005

## Typical colposcopic features and diagnostic pitfalls in 181 cases of pathologically diagnosed cervical adenocarcinoma *in situ*

LI Qing<sup>1</sup>, CHEN Li-mei<sup>1</sup>, ZHANG Hong-wei<sup>1</sup>, WANG Jue<sup>1</sup>, WANG Qing<sup>1</sup>,  
SUI Long<sup>1</sup>, CONG Qing<sup>1</sup>, HUA Ke-qin<sup>2△</sup>

(<sup>1</sup>Cervical Diseases Diagnosis and Treatment Center, <sup>2</sup>Department of Gynecology, Obstetrics and Gynecology Hospital, Fudan University, Shanghai 200090, China)

**【Abstract】** **Objective** To analyze cases and colposcopic images of cervical adenocarcinoma *in situ* (AIS) to identify reasons for colposcopic missed diagnosis, summarize typical colposcopic features of AIS, and reduce the colposcopic missed diagnosis rate, so as to provide enhanced guidance for clinical diagnosis and treatment. **Methods** We retrospectively analyzed data from patients treated in Obstetrics and

<sup>△</sup>Corresponding author E-mail: huakeqinjiaoshou@163.com

网络首发时间:2025-06-20 09:04:34 网络首发地址:https://link.cnki.net/urlid/31.1885.r.20250619.1151.002

Gynecology Hospital, Fudan University from Jan 2019 to Dec 2023. Patients pathologically diagnosed with AIS following colposcopic examination were included. We collected the age, cytology, human papilloma virus (HPV) test results, colposcopic images, colposcopic diagnoses, and pathological outcomes. We also collected the post-LEEP pathology report if patients underwent loop electrosurgical excision procedure (LEEP) in our hospital. **Results** A total of 181 patients pathologically diagnosed with AIS following colposcopic examination were included, with an average age of 40.62 years. Cytology was negative for intraepithelial lesion or malignancy in 46.4% of the patients, atypical glandular cells or AIS in 17.1% of the patients, and HPV 16/18 positive in 84.5% of the patients. The missed diagnosis rate of colposcopy was 45.3% [diagnosed as inflammation/low-grade squamous intraepithelial lesion (LSIL)]. Review of colposcopic images revealed prominent signs: acetowhite epithelium, columnar epithelial changes (Feature 1 was columnar epithelium appeared dark red with short granular changes before acetic acid application, and focal or diffuse acetowhite changes with villi elevation after application; Feature 2 was fused columnar epithelium, thickened, elevated, edematous, and acetowhite on the surface), atypical vessels and abnormal glandular openings. Further analysis of 82 missed cases showed that 24% were due to unclear vision and secretion obstruction, and 44% due to a lack of recognition of typical features. In cases missed by colposcopy (diagnosed as inflammation/LSIL), cytology was normal in 57.3%, and cytology > LSIL accounted for 22.0%; while in correctly diagnosed cases [diagnosed as high-grade squamous intraepithelial lesion (HSIL)/AIS/cancer], cytology was normal in 37.4%, and cytology > LSIL accounted for 38.4%. There was a statistically significant difference between the two groups. Further analysis of lesion location revealed that AIS lesions were only present in the endocervical curettage samples in 26.8% of the colposcopically missed diagnosis cases, significantly higher than the 6.1% in the non-missed cases. **Conclusion** We summarized 5 typical colposcopic features of AIS, and identified that the main reasons for colposcopic missed diagnosis were unclear visual fields and insufficient recognition of these typical features. Notably, 26.8% of the missed diagnosis cases had AIS detected only in endocervical curettage samples. We recommend enhancing the recognition of typical colposcopic features, optimizing visual fields during colposcopy, and emphasizing the importance of endocervical curettage to reduce the missed diagnosis rate of AIS by colposcopy.

**【Key words】** cervix; adenocarcinoma *in situ*; colposcopy; missed diagnosis

近年来,随着宫颈癌筛查的广泛实施和人乳头瘤病毒(human papillomavirus, HPV)疫苗的普及,宫颈癌的发病率呈现下降趋势。然而,宫颈腺癌及其前期病变——宫颈原位腺癌(adenocarcinoma *in situ*, AIS)的比例有所上升<sup>[1]</sup>。美国 AIS 的发病率约为 1.3~9.3/10 万<sup>[2]</sup>。宫颈鳞状上皮内病变 3 级(cervical intraepithelial neoplasia 3, CIN3)的检出率是宫颈鳞状细胞癌的 8.7 倍,而 AIS 的检出率是宫颈腺癌的 0.9 倍<sup>[3]</sup>,表明腺上皮致癌进展的自然病程与鳞状上皮不同,AIS 更易被漏诊。作为宫颈腺癌的癌前病变,AIS 的精确诊断与治疗对于预防宫颈腺癌的发展极为关键。然

而,由于 AIS 临床表现不典型和病变位置隐蔽,其在阴道镜下的诊断面临挑战<sup>[4]</sup>。

尽管现有研究广泛涉及 AIS 的筛查<sup>[5-6]</sup>、预防<sup>[7]</sup>、术后监测<sup>[8-10]</sup>以及预后指标<sup>[11-13]</sup>,但关于 AIS 阴道镜图像特征的分析资料仍然不足<sup>[14]</sup>。AIS 的阴道镜图像通常缺乏典型特征,导致诊断困难,容易漏诊,进而影响患者的进一步治疗。国内外针对大样本阴道镜图像分析的研究匮乏,相关的文献资料十分有限。本研究首次对 181 例阴道镜术后病理诊断为 AIS 的图像展开系统分析和深入挖掘,成功概括出 5 个阴道镜特征;同时,还对漏诊病例进行了深入剖析,找出导致漏诊的关键因素。为提高 AIS 诊断的

准确率提供了新的思路和方法。

## 资料和方法

**研究对象和纳排标准** 回顾性收集2019年1月至2023年12月期间在复旦大学附属妇产科医院就诊的AIS患者。纳入标准:(1)接受阴道镜检查;(2)活检病理诊断为AIS。排除标准:(1)无阴道镜电子记录者;(2)阴道镜图像缺失者;(3)阴道镜图像模糊、图像过暗者。

**资料收集和伦理审查** 收集所有患者术前6个月内的细胞学及HPV结果、阴道镜诊断、阴道镜病理和阴道镜图像资料。对在我院接受宫颈环形电切(loop electrosurgical excision procedure, LEEP)手术者,另外收集相应LEEP病理结果。本研究获复旦大学附属妇产科医院伦理委员会批准(批准号:2024-80)。

**指标分析** (1)比较AIS患者的细胞学和HPV

分型。(2)回顾每例AIS患者的阴道镜诊断和转化区类型,并对漏诊病例[阴道镜诊断炎症/低级别鳞状上皮内病变(low-grade squamous intraepithelial lesion, LSIL)]进行汇总。分析每位患者对应的阴道镜图片,总结相对典型的征象后,再次对每例图像进行具体征象分析,登记病灶所占象限数,以分析阴道镜漏诊原因。(3)汇总统计LEEP术后病理。(4)对漏诊病例及未漏诊病例进行分组,分析两组年龄、筛查结果、阴道镜特征等。

**统计学分析** 采用SPSS 20.0软件进行统计分析。定量数据以 $\bar{x} \pm s$ 表示,采用 $t$ 检验进行比较;分类数据以频数和百分比形式呈现,采用 $\chi^2$ 检验进行分析。 $P < 0.05$ 为差异有统计学意义。

## 结果

**研究对象一般情况** 本研究共纳入181例阴道镜病理AIS患者(图1),平均年龄为 $(40.62 \pm 9.59)$ 岁。

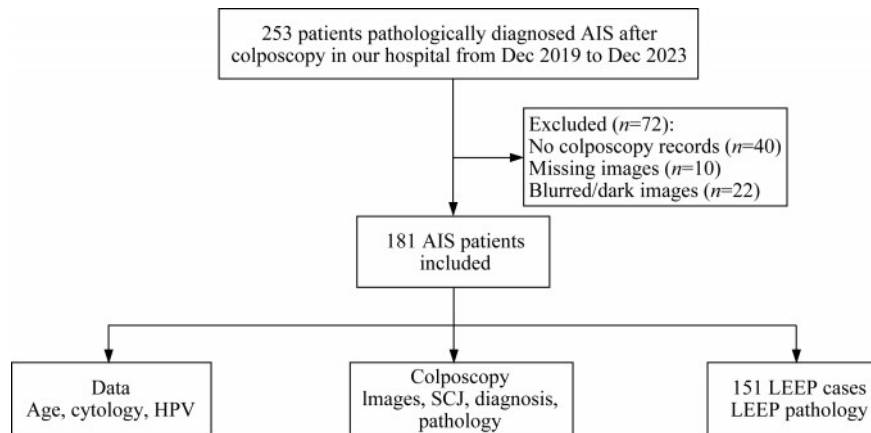


图1 研究对象纳入流程图

Fig 1 Flowchart of the patient enrollment

**细胞学和HPV分析** 阴道镜术后病理诊断AIS患者的细胞学和HPV分布:181例AIS中,84例为无上皮内病变或恶性细胞(negative for intraepithelial lesion or malignancy, NILM),23例为意义不明确的非典型鳞状细胞(atypical squamous cells of undetermined significance, ASCUS),18例为LSIL,22例为高级别鳞状上皮内病变(high-grade squamous intraepithelial lesion, HSIL)/非典型鳞状细胞-不能排除高级别鳞状上皮内病变(atypical squamous cells-cannot exclude HSIL, ASC-H)/低级别鳞状上皮内病变-不能排除高级别鳞状上皮内病变(LSIL, ASC-H),31例为非典型腺细胞(atypical

glandular cells, AGC)/AIS,3例为肿瘤。统计HPV分布情况,仅HPV16阳性者66例,仅HPV18阳性者52例,仅其他型高危HPV阳性者17例,35例为多类型HPV感染,11例HPV阴性。值得注意的是,HPV16阳性病例共90例,HPV18阳性病例共71例。非16/18型HPV中,最常见的类型为HPV45(9例)、HPV52(5例)和HPV53(5例)。

### 阴道镜特征

**典型阴道镜特征** 仔细分析181例经阴道镜术后病理确诊的AIS患者的阴道镜图像。综合文献复习,总结了以下5种较为典型的阴道镜征象(图2)。

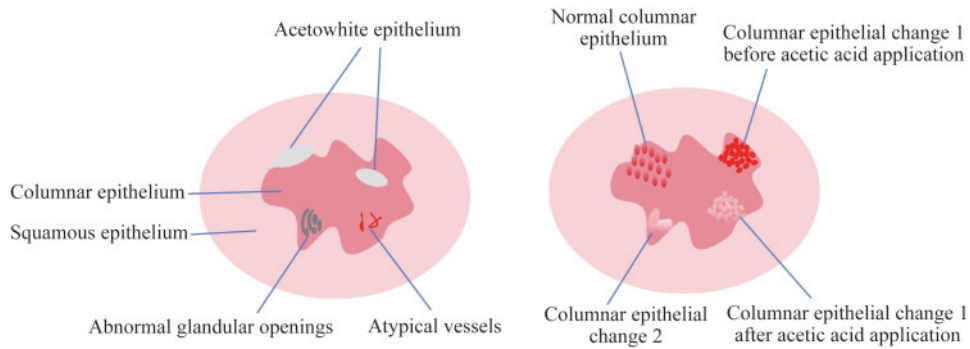
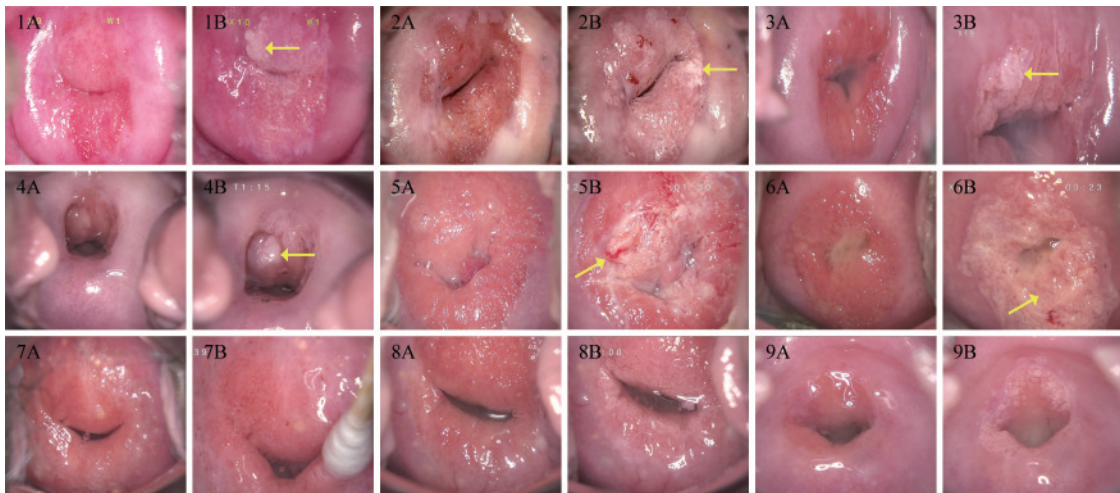


图2 AIS典型阴道镜特征图示

Fig 2 Typical colposcopy findings in AIS

(1)醋白上皮:这一特征呈现为在柱状上皮背景下的明显白色斑块,或在柱状上皮中不规则的白色斑块与红色交织(红白相间)。通常观察到醋白上皮在鳞柱交界附近,或者在鳞柱交界内侧,被柱状上皮包围(详见图3~5中AIS图例)。(2)柱状上皮变化1:涂醋前后柱状上皮的变化,是本研究总结的典型征象。涂醋前柱状上皮绒毛密集,呈矮颗粒状改变,柱状上皮背景呈暗红色(柱状上皮萎缩呈矮颗粒状,间质血管更易透过柱状上皮呈现,故而色泽为较深,常呈暗红色),涂醋后柱状上皮局灶或弥漫性醋白,病灶处绒毛隆起。涂醋前暗红色的表现,与正常柱状上皮外翻不同,后者柱状上皮绒毛分布均匀,绒毛间有一定间隙,较为稀疏,形态一

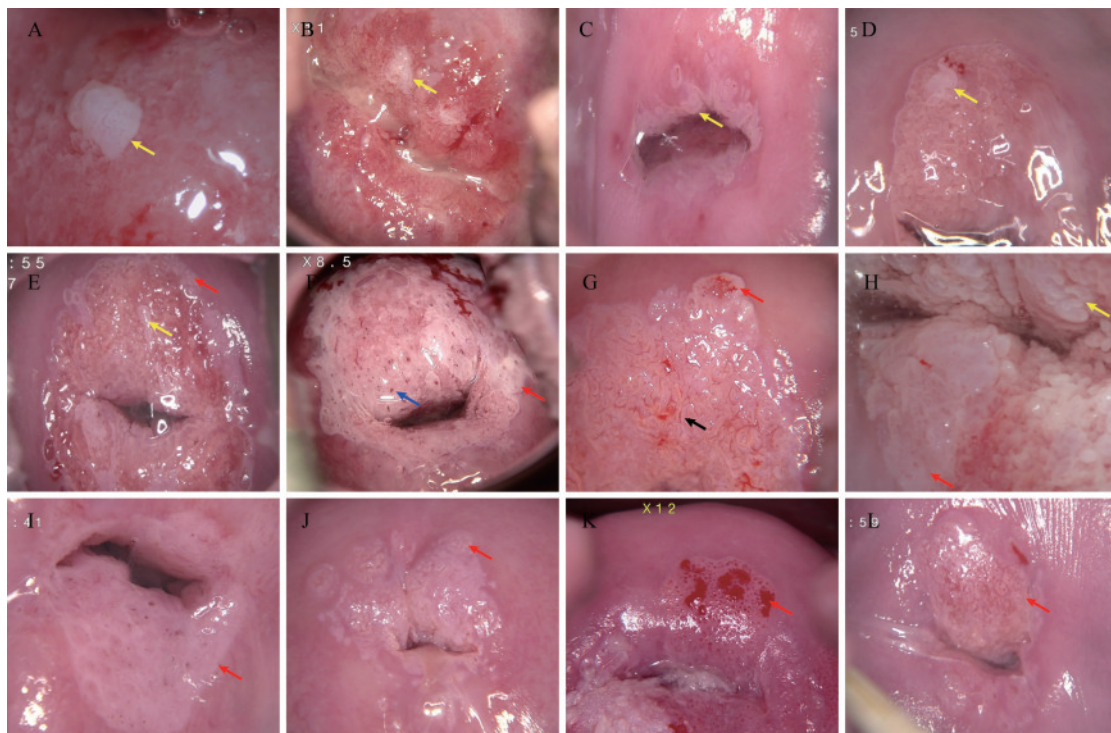
致,比较均匀,呈现粉红色,而非暗红色(图3)。(3)柱状上皮变化2:柱状上皮融合,绒毛粗大,隆起,水肿,涂醋后表面呈厚醋白,边界清晰,锐利(图4中黄色箭头所指处)。(4)非典型血管:可成发卡状/树枝状(图4G中黑色箭头所指处)。(5)异常腺开口:AIS的典型腺开口发生为在宫颈柱状上皮/转化区的,密集、受压、扁平、深浅不一的裂隙状开口;或者扩张,周围环绕着醋白环,呈现出类似袖口样的高腺开口特征。相比之下,鳞状上皮病变,如宫颈HSIL的腺开口,通常位于鳞状上皮或转化区内,较少出现在柱状上皮区域,且不易受到挤压变形(图4蓝色箭头所指处)。图5则详细展示AIS、HSIL和宫颈腺癌的不同腺开口。



Images 1-6 display colposcopic findings of AIS, while images 7-9 depict normal colposcopic findings. 'A' indicates images taken before acid application, and 'B' denotes images after acid application. 1A-6A: Prior to acetic acid application, the tissue exhibited dark red coloration with evident granular changes and atrophy. 1B-6B: Following the application of acetic acid, the images revealed acetowhite epithelium (marked by the yellow arrow). 7A-9A: Before acetic acid application, columnar epithelium eversion is observed. The columnar epithelial villi are evenly distributed with interspersed spacing, appearing relatively sparse and uniform in morphology. The color is pink rather than dark red. 7B-9B: After acetic acid application, no significant acetowhite epithelium or lesions are detected.

图3 AIS的典型征象——柱状上皮变化1

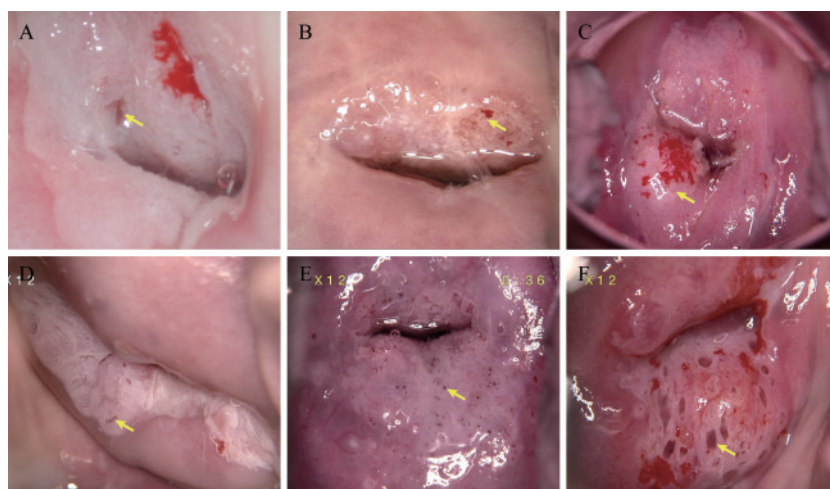
Fig 3 Prominent signs of AIS: columnar epithelium change 1



A-D display pure AIS; E-H show AIS combined with HSIL; I-L illustrate pure HSIL. The yellow arrows highlight typical columnar epithelial changes in AIS, characterized by fused columnar epithelium with enlarged, thickened, and edematous villi, showing dense acetowhitening and sharp, well-defined borders after acetic acid application. Blue arrow in Figure F indicates the glandular opening in AIS. Black arrow in Figure G points to atypical blood vessels in AIS. The red arrow highlights typical HSIL signs, including thick acetowhite epithelium (F, H and I), coarse mosaic (E, J and L), and coarse punctate blood vessels (G, K).

图4 AIS的典型征象——柱状上皮变化2

Fig 4 Prominent signs of AIS: columnar epithelium change 2



A-D (AIS): Typical gland openings in AIS are located within the columnar epithelium/transformation zone, appearing as densely packed, compressed, flattened, and irregularly slit-like openings. Alternatively, they may present as dilated openings surrounded by acetowhite halos, exhibiting a characteristic "cuff-like" high gland opening pattern. E (HSIL): HSIL typically occurs in the squamous epithelium or transformation zone and rarely involves the columnar epithelium. The gland openings are less prone to compression or distortion. F (Adenocarcinoma): Gland openings in adenocarcinoma are abnormally enlarged, with loosely arranged tissue and abundant clear secretions. Yellow arrows indicate gland openings.

图5 AIS、HSIL及宫颈腺癌阴道镜腺开口示例

Fig 5 Glandular opening in AIS, HSIL and cervical adenocarcinoma

**阴道镜特征和漏诊原因** 查阅181例AIS患者的阴道镜电子记录,汇总鳞柱交界(squamo-columnar junction, SCJ)分型和阴道镜诊断;记录阴道镜活检病理结果。69例为SCJ1,28例为SCJ2型者,84例为SCJ3型。阴道镜诊断正常/LSIL者82例(漏诊率45.3%),诊断HSIL/AIS者82例,诊断浸润癌者17例。87例AIS仅存在于宫颈活检组织,28例仅在于子宫颈管搔刮组织(endocervical curettage, ECC),66例同时存在于宫颈活检和ECC中。此外,91例为单纯AIS,90例为AIS合并鳞状上皮内病变(squamous intraepithelial lesion, SIL)。根据上述5种典型特征,对181例阴道镜图片进行复审。病灶累及4个象限者40例,累及3个象限者22例,累及2个象限者52例,累及1个象限者52例,15例无宫颈表面病灶。前述5种典型特征中,最常见的特征是醋白上皮,其中92例为薄醋白上皮,70例为厚醋白上皮。此外,103例表现为柱状上皮变化1,94例显示柱状上皮变化2。此外,有58例呈现非典型血管,38例提示异常腺体开口,26例有点状血管(16例细点状血管,10例粗点状血管),24例镶嵌(13例细镶嵌,11例粗镶嵌),17例有肿块形成。

对82例漏诊病例原因进行分析,发现36例是由于对阴道镜特征(前述5种特征)不熟悉,再次复审未漏诊,诊断为HSIL/AIS;37例为阴道镜图像不满意,其中20例为宫颈暴露不满意(14例分泌物遮挡,4例出血,2例阴道镜焦距欠佳),17例为3型转化区,宫颈无病灶,仅颈管搔刮阳性;余9例图像无明显特征性,再次复审依旧拟诊炎症/LSIL。

**LEEP病理** 181例AIS患者中,有151例在我院接受了LEEP手术。LEEP病理分布如下:AIS者57例,AIS合并SIL者47例,宫颈腺癌21例,LSIL/HSIL 9例,正常宫颈组织9例,鳞状细胞癌5例,原位腺鳞癌2例,腺鳞癌1例。

**阴道镜漏诊和未漏诊病例比较** 将阴道镜诊断为 $\leq$ LSIL(炎症/LSIL)的患者归为漏诊组,阴道镜诊断为 $\geq$ HSIL(HSIL/AIS/癌症)的患者归为未漏诊组,比较两组患者的年龄、细胞学、HPV、转化区类型、典型阴道镜特征、阴道镜病理和LEEP病理(表1)。两组在年龄、HPV分布、转化区类型、“柱状上皮变化1”、阴道镜病理(纯AIS, AIS+SIL)、LEEP病理分布等方面差异无统计学意义。细胞学正常的NILM更易漏诊,细胞学 $>$ LSIL(HSIL/

AGC/ASC-H)者更不易漏诊( $P=0.018$ )。有阴道镜征象如柱状上皮变化2、醋白上皮、非典型血管、异常腺体开口和肿块形成的患者更不易被漏诊( $P$ 均 $<0.05$ )。漏诊组涉及的象限较少(0~1个象限),且阴道镜病理仅颈管搔刮AIS者比例较高( $P<0.001$ )。

## 讨 论

我们分析了181例阴道镜术后病理诊断为AIS患者的年龄、细胞学、HPV分布、阴道镜特征、阴道镜病理及LEEP病理结果。患者平均年龄为( $40.62 \pm 9.59$ )岁,与文献报道的32~40岁诊断高峰年龄段相吻合<sup>[1,15]</sup>。本组HPV16的阳性率为49.7%(90/181),HPV18的阳性率为39.2%(71/181),与美国SGO指南中提到的AIS中HPV16阳性率46%~58%和HPV18阳性率38%~50%的范围一致<sup>[1]</sup>。本组HPV16和/或HPV18的联合阳性率高达84.5%(153/181),非HPV16/18型别的阳性率为6.1%(11/181),而HPV阴性样本占9.4%(17/181),进一步证实了HPV16和HPV18在AIS发病中的重要作用。本研究中细胞学异常的总检出率为53.6%(97/181),其中鳞状上皮异常检出率为36.5%(66/181),腺体上皮异常检出率为17.1%(31/181),提示在AIS诊断中识别腺体上皮异常的重要性。值得注意的是,在84例细胞学结果为阴性的病例中,有78例HPV16/18阳性,占比高达92.9%,突显了在临床诊断中结合细胞学检测和HPV筛查的重要性。

以往研究主要关注AIS的手术方式和切缘状态对复发风险的影响。Cohen等<sup>[9]</sup>发现AIS行LEEP或冷刀锥切,切缘无差异;Liu等<sup>[16]</sup>比较AIS行全子宫切除与锥形切除,两组复发率亦无显著差异;Soegaard-Andersen<sup>[17]</sup>和Salani等<sup>[18]</sup>的研究进一步探讨了手术边缘状态与复发风险的关系。这些文献为AIS的手术治疗提供了科学依据。然而,AIS的临床困境在于阴道镜诊断的困难、漏诊率高。阴道镜诊断的主观性较强,且存在一定的假阴性率。这种局限性可能与操作者的经验、活检组织的部位、大小及深度、以及病变是否位于宫颈管等因素有关。国际宫颈病理与阴道镜联盟(International Federation for Cervical Pathology and

表1 阴道镜诊断 $\leq$ LSIL(漏诊组)与 $\geq$ HSIL(未漏诊组)患者的一般特征比较Tab 1 Comparison of general characteristics between patients with colposcopic diagnosis  $\leq$ LSIL and  $\geq$ HSIL [ $\bar{x} \pm s$  or  $n(\%)$ ]

Category	Subcategory	Colposcopic impression $\leq$ LSIL ( $n=82$ )	Colposcopic impression $\geq$ HSIL ( $n=99$ )	$t/\chi^2$	$P$
Age (y)	-	41.0 $\pm$ 10.36	40.24 $\pm$ 8.92	0.523	0.557
LCT	NILM	47 (57.3)	37 (37.4)*	8.002	<b>0.018</b>
	ASCUS/LSIL	17 (20.7)	24 (24.2)		
	>LSIL	18 (22.0)	38 (38.4)*		
HPV	HPV16+	43 (50.0)	47 (45.6)	0.500	0.779
	HPV18+	30 (34.9)	41 (39.8)		
	Other/(-)	13 (15.1)	15 (14.6)		
SCJ	SCJ1	32 (39.0)	37 (37.4)	0.484	0.785
	SCJ2	14 (17.1)	14 (14.1)		
	SCJ3	36 (43.9)	48 (48.5)		
CEC 1	No	39 (47.6)	39 (39.4)	1.220	0.269
	Yes	43 (52.4)	60 (60.6)		
CEC 2	No	47 (57.3)	40 (40.4)	5.140	<b>0.023</b>
	Yes	35 (42.7)	59 (59.6)		
Acetowhite epithelium	No	15 (18.3)	4 (4.0)	9.697	<b>0.002</b>
	Yes	67 (81.7)	95 (96.0)		
Atypical vessels	No	71 (86.6)	52 (52.5)	23.894	$\leq$ <b>0.001</b>
	Yes	11 (13.4)	47 (47.5)		
Abnormal glandular opening	No	76 (92.7)	67 (67.7)	16.908	$\leq$ <b>0.001</b>
	Yes	6 (7.3)	32 (32.3)		
Formation of a lump	No	81 (98.8)	83 (83.8)	11.767	<b>0.001</b>
	Yes	1 (1.2)	16 (16.2)		
Dot-like blood vessels	No	80 (97.6)	75 (75.8)	17.333	$\leq$ <b>0.001</b>
	Yes	2 (2.4)	24 (24.2)		
Mosaic	No	80 (97.6)	77 (77.8)	15.262	$\leq$ <b>0.001</b>
	Yes	2 (2.4)	22 (22.2)		
Number of quadrants involved	0-1	54 (65.9)	13 (13.1)	53.473	$\leq$ <b>0.001</b>
	2-4	28 (34.1)	86 (86.9)		
	Cervix only	39 (47.6)	48 (48.5)		
Pathology of colposcopy AIS	ECC only	22 (26.8)	6 (6.1)*	17.385	$\leq$ <b>0.001</b>
	Both	21 (25.6)	45 (45.5)*		
	AIS	46 (56.1)	45 (45.5)		
Pathology of colposcopy	AIS+SIL	36 (43.9)	54 (54.5)	2.032	0.154
	$\leq$ LSIL	6 (8.7)	4 (4.9)		
	HSIL/AIS	51 (73.9)	61 (74.4)		
Pathology of LEEP	HSIL/AIS	51 (73.9)	61 (74.4)	1.058	0.630
	Ca	12 (17.4)	17 (20.7)		

LSIL: Low-grade squamous intraepithelial lesion; HSIL: High-grade squamous intraepithelial lesion; LCT: Liquid-based cytologic test; HPV: Human papillomavirus; SCJ: Squamocolumnar junction; CEC: Columnar epithelium change; AIS: Adenocarcinoma *in situ*; LEEP: Loop electrosurgical excision procedure; ASCUS: Atypical squamous cells of undetermined significance; Other/(-): Other types or negative; ECC: Endocervical curettage; \*Pairwise comparisons showed significant differences between rows.

Colposcopy, IFCCP)阴道镜术语中相关阴道镜征象也主要针对鳞状上皮内病变,缺少对腺上皮病变的探讨。Wright<sup>[14]</sup>汇总了17例AIS和4例宫颈腺癌的阴道镜图像特征,如病灶位于柱状上而不涉及鳞柱交界、较大的腺开口、柱状上皮乳头状凸起、有较多分泌物、红白相间等;非典型血管包括包括纤细的线状血管、须状血管、基底扩张的血管、呈字母形状的血管,以及在乳头样突起顶端的单个或多个点状结构。Lickrish等<sup>[19]</sup>讨论了AIS和侵袭性腺癌的阴道镜特征,指出病变通常是非典型的,可延伸到子宫颈管;典型的变化包括柱状上皮的改变,侵袭性腺癌可能伴有非典型血管的出现。这与本研究中的柱状上皮内的病变、柱状上皮水肿粗大、病变红白相间、非典型血管等相似。我们分析了181例阴道镜后病理诊断的AIS患者阴道镜图像,总结出5大征象:醋白上皮、柱状上皮变化1、柱状上皮变化2、非典型血管、异常腺开口。尤其是柱状上皮变化1,是我们总结的新的典型征象,即涂醋前柱状上皮绒毛密集、呈矮颗粒状改变、柱状上皮背景呈暗红色,涂醋后柱状上皮局灶或弥漫性醋白、病灶处绒毛隆起。复核图像后发现,有103例均有该征象(56.91%)。这一大规模的研究样本为阴道镜图像特征与AIS之间的关联提供了更为丰富和可靠的数据支持。通过对大量患者的阴道镜图像进行系统性分析,揭示了AIS在阴道镜下更为全面的特征表现,从而为临床医师提供了更为精确的诊断依据。复核82例漏诊病例,如按照上述5大征象,可减少36例(43.90%)漏诊。

阴道镜检查作为一种直观的诊断手段,在宫颈病变的诊断中扮演着重要角色。然而,由于AIS的病变较为隐蔽,且容易受到分泌物等因素的影响,使得其诊断更具挑战性。在对82例漏诊病例复核图像时,发现有20例(24.39%)为宫颈暴露不满意(14例为分泌物遮挡,4例出血,2例阴道镜焦距欠佳)。因此,规范化的阴道镜操作程序对于提高诊断的准确性和减少漏诊至关重要。除了术中充分暴露宫颈、动作轻柔、清除分泌物和减少出血,阴道镜医师还应该接受定期的培训。此外,使用先进的阴道镜技术和图像增强工具,如电子阴道镜和图像分析软件,可以帮助医师更清晰地观察到微小的病变,从而做出更精确的诊断。这些措施可以显著提高AIS的检出率,为患者提供更及时有效的治疗。

由于AIS病灶可能存在于宫颈管深处,并且能以跳跃性病变的形式存在,因此颈管搔刮对于识别这些病变至关重要。我们在分析阴道镜漏诊和未漏诊病例时发现,漏诊组阴道镜病理仅宫颈管搔刮AIS者比例为26.8%,而未漏诊组该比例为6.1% ( $P<0.001$ ),且AIS中HPV16/18阳性率高达84.5%。因此,建议可在HPV16/18感染非孕期的女性中常规进行ECC,特别是有AIS风险的患者群体。医师通过ECC能够更准确地评估宫颈管内的状况,及时发现隐匿性病变,从而避免漏诊。这对于制定正确的治疗计划、选择合适的手术方式以及提高患者预后至关重要。

本研究的局限性在于回顾性研究和单一中心样本,限制了研究结果的外推,但仍为理解AIS的诊断特征和改进阴道镜检查提供了有价值的参考。

我们通过分析181例阴道镜术后AIS病例及图像,总结了典型的5个阴道镜图像特征。阴道镜漏诊的主要原因是视野不清(如分泌物遮挡)和对典型特征认识不足。熟悉典型阴道镜特征后,43.90%的漏诊病例可被正确拟诊。我们还发现细胞学检查结果与阴道镜诊断结果存在显著差异,细胞学正常或低级别病变的患者在漏诊组中占比更高,且AIS病灶仅存在于宫颈管搔刮样本的病例在漏诊组中更为常见。因此,提高阴道镜检查的视野清晰度、加强对典型图像特征的认识以及重视宫颈管搔刮样本的病理检查,有助于降低AIS的阴道镜漏诊率,从而为临床诊断与治疗提供更有力的指导。

**作者贡献声明** 李清 数据收集和统计,论文撰写。陈丽梅 研究设计,数据收集。张宏伟,王珏 数据统计,绘图。汪清,隋龙,丛青 临床指导,论文修订。华克勤 课题指导,数据收集,论文修订。

**利益冲突声明** 华克勤是本刊编委,未参与此文的同行评议和终审决策。没有其他利益冲突需要声明。

## 参 考 文 献

- [1] TEOH D, MUSA F, SALANI R, *et al.* Diagnosis and management of adenocarcinoma *in situ*: a society of gynecologic oncology evidence-based review and recommendations [J]. *Obstet Gynecol*, 2020, 135 (4): 869-

- 878.
- [ 2 ] CLEVELAND AA, GARGANO JW, PARK IU, *et al.* Cervical adenocarcinoma *in situ*: human papillomavirus types and incidence trends in five states, 2008-2015[J]. *Int J Cancer*, 2020, 146(3):810-818.
- [ 3 ] BEFANO B, WENTZENSEN N, LOREY T, *et al.* Calendar-period trends in cervical precancer and cancer diagnoses since the introduction of human papillomavirus and cytology co-testing into routine cervical cancer screening at Kaiser Permanente Northern California [J]. *Gynecol Oncol*, 2024, 184:89-95.
- [ 4 ] JOHNSTON C. Cervical adenocarcinoma *in situ*: a persistent clinical dilemma[J]. *Lancet*, 1997, 350(9088):1337-1338.
- [ 5 ] ZHANG RC, VUE NC, OBASI LU, *et al.* Impact of screening modality on the detection of cervical adenocarcinoma *in situ* and adenocarcinoma [J]. *J Low Genit Tract Dis*, 2021, 25(4):267-269.
- [ 6 ] LI C, ROCK KL, WODA BA, *et al.* IMP3 is a novel biomarker for adenocarcinoma *in situ* of the uterine cervix: an immunohistochemical study in comparison with p16 (INK4a) expression[J]. *Mod Pathol*, 2007, 20(2):242-247.
- [ 7 ] AULT KA. Effect of prophylactic human papillomavirus L1 virus-like-particle vaccine on risk of cervical intraepithelial neoplasia grade 2, grade 3, and adenocarcinoma *in situ*: a combined analysis of four randomised clinical trials [J]. *Lancet*, 2007, 369(9576):1861-1868.
- [ 8 ] MUNRO A, CODDE J, SPILSBURY K, *et al.* Risk of persistent or recurrent neoplasia in conservatively treated women with cervical adenocarcinoma *in situ* with negative histological margins[J]. *Acta Obstet Gynecol Scand*, 2017, 96(4):432-437.
- [ 9 ] COHEN PA, LEUNG Y, ANDERSON L, *et al.* Excisional treatment comparison for *in situ* endocervical adenocarcinoma (EXCISE): a phase 2 pilot randomized controlled trial to compare histopathological margin status, specimen size and fragmentation after loop electrosurgical excision procedure and cold knife cone biopsy [J]. *Gynecol Oncol*, 2020, 159(3):623-629.
- [ 10 ] UPADHYAY BS, WANG T, ZHAO C. Follow-up findings in postconservative treatment surveillance for women with cervical adenocarcinoma *in situ* [J]. *J Low Genit Tract Dis*, 2021, 25(1):38-42.
- [ 11 ] CODDE E, MUNRO A, STEWART C, *et al.* Risk of persistent or recurrent cervical neoplasia in patients with 'pure' adenocarcinoma-in-situ (AIS) or mixed AIS and high-grade cervical squamous neoplasia (cervical intraepithelial neoplasia grades 2 and 3 (CIN 2/3)): a population-based study [J]. *BJOG*, 2018, 125(1):74-79.
- [ 12 ] YOUNG JL, JAZAERI AA, LACHANCE JA, *et al.* Cervical adenocarcinoma *in situ*: the predictive value of conization margin status [J]. *Am J Obstet Gynecol*, 2007, 197(2):195.e1-e8.
- [ 13 ] TIERNEY KE, LIN PS, AMEZCUA C, *et al.* Cervical conization of adenocarcinoma *in situ*: a predicting model of residual disease [J]. *Am J Obstet Gynecol*, 2014, 210(4):361-366.
- [ 14 ] WRIGHT VC. Colposcopy of adenocarcinoma *in situ* and adenocarcinoma of the uterine cervix: differentiation from other cervical lesions [J]. *J Low Genit Tract Dis*, 1999, 3(2):83-97.
- [ 15 ] CIAVATTINI A, GIANNELLA L, DELLI CG, *et al.* Adenocarcinoma *in situ* of the uterine cervix: clinical practice guidelines from the Italian society of colposcopy and cervical pathology (SICPCV) [J]. *Eur J Obstet Gynecol Reprod Biol*, 2019, 240:273-277.
- [ 16 ] LIU J, WANG Y, WAN X, *et al.* Comparison of the safety between cervical conization and hysterectomy for patients with cervical adenocarcinoma *in situ* [J]. *J Gynecol Oncol*, 2023, 34(1):e8.
- [ 17 ] SOEGAARD-ANDERSEN E, FRANDBEN AP, SANDAHL P. Adenocarcinoma *in situ* of the uterine cervix (AIS) treated by loop electrosurgical excision procedure strategy: an observational study [J]. *J Low Genit Tract Dis*, 2024, 28(2):149-152.
- [ 18 ] SALANI R, PURI I, BRISTOW RE. Adenocarcinoma *in situ* of the uterine cervix: a metaanalysis of 1278 patients evaluating the predictive value of conization margin status [J]. *Am J Obstet Gynecol*, 2009, 200(2):181-182.
- [ 19 ] LICKRISH GM, COLGAN TJ, WRIGHT VC. Colposcopy of adenocarcinoma *in situ* and invasive adenocarcinoma of the cervix [J]. *Obstet Gynecol Clin North Am*, 1993, 20(1):111-122.

(收稿日期:2024-11-15; 编辑:张秀峰)