

[DOI] 10.12016/j.issn.2096-1456.202440415

· 临床研究 ·

不同骨性畸形成年患者舌位置及体积的三维评估

邱伟倬, 门欣睿, 张恺文, 蒋晓鸽, 陈嵩

口腔疾病防治国家重点实验室 国家口腔医学中心 国家口腔疾病临床医学研究中心 四川大学华西口腔医院
正畸科, 四川 成都, 610041

【摘要】 目的 分析不同成年骨性畸形患者的舌体体积、位置与牙列、颌骨参数之间的关系,为骨性畸形患者的病因、诊断及治疗提供参考。方法 本研究已通过单位伦理委员会审查批准,并获得患者知情同意。收集60例成年患者的锥形束CT及头影测量侧位片数据,根据ANB角将其分为骨性I类($0^\circ < ANB < 4^\circ$)、II类($ANB > 4^\circ$)及III类($ANB < 0^\circ$)3组,每组各20例。使用Dolphin软件测量牙、骨参数,使用Mimics软件对舌体、口腔及上气道进行三维重建,测量舌体位置、舌体积、口腔体积及上气道体积,并进行统计分析。结果 骨性III类组的舌体积和口腔体积大于骨性I类及骨性II类组,差异有统计学意义($P = 0.02$)。骨性III类组的舌体长度大于骨性I类及骨性II类组($P = 0.016$)。舌体积/口腔体积占比在3种骨性畸形中无明显差异($P > 0.05$)。舌体积与U1-SN呈正相关,与覆殆、覆盖呈负相关($P < 0.05$)。舌体积与Go-Gn、Pg-Np呈显著正相关($P < 0.01$),与上下颌牙弓宽度、基骨弓宽度呈显著正相关($P < 0.01$)。上气道体积与TT-VRL、TP-VRL成正相关($P < 0.05$)。结论 骨性III类患者的舌体积较大,且舌体较长。舌体积较大的患者可能伴有更大、位置更靠前的下颌骨。舌位更靠后的患者可能具有更小的上气道体积。在制定正畸或正颌治疗方案时,应重视舌体的位置和体积与颌骨、气道之间的联系,以兼顾牙颌形态与口周功能的治疗效果。

【关键词】 舌体积; 舌位置; 骨性畸形; 口腔体积; 固有口腔体积; 上气道; 下颌骨; 锥形束CT; 头影测量; 错殆畸形

【中图分类号】 R78 **【文献标志码】** A **【文章编号】** 2096-1456(2025)01-0033-08

【引用著录格式】 邱伟倬,门欣睿,张恺文,等. 不同骨性畸形成年患者舌位置及体积的三维评估[J]. 口腔疾病防治, 2025, 33(1): 33-40. doi:10.12016/j.issn.2096-1456.202440415.

Three-dimensional evaluation of tongue position and volume in adult patients with different skeletal malocclusions CHIOU Wei-Cho, MEN Xinrui, ZHANG Kaiwen, JIANG Xiaoge, CHEN Song. State Key Laboratory of Oral Diseases & National Center for Stomatology & National Clinical Research Center for Oral Diseases & Department of Orthodontics, West China Hospital of Stomatology, Sichuan University, Chengdu 610041, China

Corresponding author: CHEN Song, Email: songchen882002@hotmail.com, Tel: 86-17713647073

【Abstract】 Objective To analyze the relationship between tongue volume, tongue position, dental and skeletal parameters in adult patients with different skeletal malocclusions, providing references for the etiology, diagnosis, and treatment of skeletal malocclusions. **Methods** This study has been reviewed and approved by the Ethics Committee, and informed consent has been obtained from patients. Cone-beam computed tomography (CBCT) and cephalometric radiographs were collected from 60 adult patients, divided into three groups based on ANB angle values: skeletal Class I ($0^\circ < ANB < 4^\circ$), II ($ANB > 4^\circ$), and III ($ANB < 0^\circ$), with 20 cases in each group. Dental and skeletal parameters were measured using Dolphin software. Mimics software was used for 3D reconstruction of the tongue, oral cavity, and upper airway to measure tongue position, tongue volume, oral cavity volume, and upper airway volume, followed by statistical analysis. **Results** The skeletal Class III group had significantly larger tongue and oral cavity volumes than the skeletal Class I and Class II groups ($P = 0.02$). Tongue length in the skeletal Class III group was also greater than in the skeletal

【收稿日期】2024-10-26; **【修回日期】**2024-11-28

【基金项目】四川省科技计划项目(2022YFS0127)

【作者简介】邱伟倬, 硕士, E-mail: chiouweizhuo@gmail.com

【通信作者】陈嵩, 教授, 博士, E-mail: songchen882002@hotmail.com, Tel: 86-17713647073



微信公众号

Class I and Class II groups ($P = 0.016$). There was no significant difference in the ratio of tongue volume/oral cavity capacity among the three skeletal malocclusion groups ($P > 0.05$). Tongue volume was positively correlated with U1-SN and negatively correlated with overbite and overjet ($P < 0.05$). Additionally, tongue volume showed a significant positive correlation with Go-Gn and Pg-Np ($P < 0.01$), as well as with maxillary and mandibular dental arch width and basal bone arch width ($P < 0.01$). Upper airway volume was positively correlated with TT-VRL and TP-VRL ($P < 0.05$). **Conclusion** Patients with skeletal Class III malocclusion have larger tongue volumes and longer tongues. Patients with larger tongue volumes may also have larger, more forward-positioned mandibles. Patients with more posterior tongue positions may have smaller upper airway volumes. When developing orthodontic or orthognathic treatment plans, it is crucial to consider the relationship between tongue position, tongue volume, the jaws, and the airway to ensure optimal outcomes for both dental and orofacial function.

【Key words】 tongue volume; tongue position; skeletal malocclusion; oral cavity capacity; oral cavity proper volume; upper airway; mandible; CBCT; lateral cephalogram; malocclusion

J Prev Treat Stomatol Dis, 2025, 33(1): 33-40.

【Competing interests】 The authors declare no competing interests.

This study was supported by the grants from Sichuan Science and Technology Program (No. 2022YFS0127).

神经肌肉平衡在上下颌骨的生长过程中发挥着重要作用,并可能影响咬合关系的建立^[1-2]。牙齿在牙槽骨中的功能稳定位置以及牙弓形态是由舌体和面部肌肉组织之间的相互作用决定的。舌施加的力在引导牙弓形成和咬合关系建立中发挥着关键作用^[3-5]。

已有研究表明,舌体与骨性畸形之间存在密切联系。Shinde等^[6]通过头影测量侧位片发现,骨性Ⅱ类错颌患者的舌位较骨性Ⅰ类患者靠后,且舌体较短。Chauhan等^[7]测量头影测量侧位片得出,骨性Ⅱ类Ⅰ分类患者的舌尖位置较骨性Ⅰ类患者更高。Yilmaz等^[8]通过磁共振成像发现,与骨性Ⅰ类患者相比,骨性Ⅱ类患者的舌背位置更靠前,舌尖位置更靠后。然而,以上研究大多是聚焦于舌体位置与骨性错颌畸形之间的联系,较少探讨舌体积、舌体积在口腔中占比以及舌体与上气道的联系。此外,大多数研究仅采用头影测量侧位片进行舌体二维测量,无法反映舌体的真实三维结构。

因此,本研究旨在利用锥形束CT(cone beam computed tomography, CBCT)对3种不同骨性畸形成年患者的舌体积及位置进行三维测量分析,并同时对上气道体积进行三维测量,以探讨其与骨性畸形的关系,为骨性畸形的病因研究提供依据,并为正畸或正颌治疗中的方案制定、复诊监控及术后保持提供参考。

1 资料与方法

1.1 研究对象

采集2019年1月—2023年6月就诊于四川大学华西口腔医院正畸科的患者头影测量侧位片及CBCT等数据。纳入标准:①年龄18~40岁;②恒牙

列;③完整、清晰的全牙颌大视野CBCT及头影测量侧位片。排除标准:①正畸、正颌治疗史;②颞下颌骨关节病史;③颅颌面、全身发育异常;④除第三磨牙外有缺失牙、埋伏牙;⑤前牙开颌、前牙无接触;⑥腺样体、扁桃体肥大。

本研究最终纳入研究对象60例,参考Steiner^[9]分析法,将纳入的研究对象依据ANB角分为3组,每组20例:①骨性Ⅰ类组($0^\circ < ANB < 4^\circ$);②骨性Ⅱ类组($ANB > 4^\circ$);③骨性Ⅲ类组($ANB < 0^\circ$)。本研究由四川大学华西口腔医院医学伦理委员会审批(审批号:WCHSIRB-D-2024-274)。

1.2 CBCT及头影测量侧位片拍摄

60例研究对象的CBCT均采用华西口腔医院放射科的CBCT扫描仪(3D Accutomo CB-CT, MORITA公司,日本)进行扫描。扫描参数为:85.0 kV, 5.0 mA, 视野20 cm×19 cm,扫描时间17.5 s,扫描层厚0.25 mm。扫描时患者保持牙尖交错位,无咀嚼及吞咽,眶耳平面与水平扫描线重合,正中矢状线与垂直扫描线重合。扫描后的CBCT数据以DICOM格式存储。采用华西口腔医院放射科的X线头影测量机(VERA VIEWEPOCS 2D, MORITA, 日本)拍摄头影测量侧位片,拍摄时取站立位,眶耳平面与地面平行,双唇自然闭合,颌位在牙尖交错位。

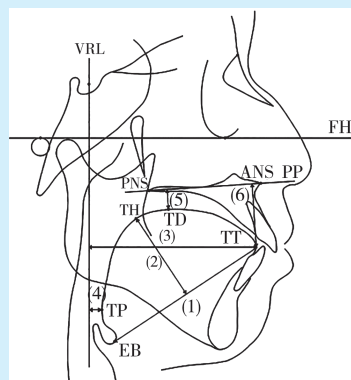
1.3 测量方法

1.3.1 二维测量内容 将头影测量侧位片导入Dolphin 11.8软件,将CBCT的DICOM数据导入Mimics Research 16.0软件,校正头位后进行测量。标志点及测量内容参考以往研究^[6,10],测量项目的定义详见表1、图1。

表1 头影测量侧位片的二维测量参数
Table 1 2D parameters for cephalometric radiographs

| | Parameters | Definition |
|--------------------------------|--------------------------------------|--|
| Parameters measured by Dolphin | SNA/° | Position of maxilla relative to skull |
| | SNB/° | Position of mandible relative to skull |
| | ANB/° | Positional relationship between maxilla and mandible |
| | MP-SN/° | Mandibular inclination |
| | ANS-PNS/mm | Maxillary length |
| | Go-Gn/mm | Corpus mandibulae length |
| | ANS-Me/N-Me | Ratio of lower to total facial height |
| | S-Go/N-Me | Ratio of posterior to anterior facial height |
| | A-Np/mm | Vertical distance from A point to Np |
| | Pg-Np/mm | Vertical distance from pogonion to Np |
| | U1-SN/° | Inclination of maxillary central incisor |
| | L1-MP/° | Inclination of mandibular central incisor |
| | U1-Np/mm | Protrusion of maxillary central incisor |
| | L1-Np/mm | Protrusion of mandibular central incisor |
| | Ob/mm | Overbite |
| | Oj/mm | Overjet |
| Parameters measured by Mimics | Maxillary dental arch width/mm | The distance between the most convex lingual points of the maxillary first molar crowns |
| | Mandibular dental arch width/mm | The distance between the most convex lingual points of the mandibular first molar crowns |
| | Maxillary basal bone arch width /mm | Distance between maxillary zygomatic arch points |
| | Mandibular basal bone arch width /mm | The distance between the buccal cortical points corresponding to the resistance center of the mandibular first molar |
| | TGL/mm | Tongue length, distance from tongue tip to epiglottis base |
| | TGH/mm | Tongue high. When the TT-EB line is translated to be tangent to the tongue dorsum, the vertical distance between the tangent point and the TT-EB connection |
| | TT-VRL/mm | Vertical distance from TT to VRL |
| | TP-VRL/mm | Vertical distance from TP to VRL |
| | TD-PP/mm | Tongue dorsum height. When the palatal plane is translated to be tangent to the tongue dorsum, the vertical distance between the tangent point and the palatal plane |
| | TT-PP/mm | Vertical distance from TT to PP |

SNA: angle between sella, nasion and subspinale point A. SNB: angle between sella, nasion and supramentale point B. ANB: angle between subspinale point A and supramentale point B. MP- SN: angle between SN plane and the mandibular plane angle. ANS- PNS: distance from anterior nasal spine to posterior nasal spine. Go-Gn: distance from gonion to gnathion. ANS-Me/N-Me: the ratio of the lower anterior facial height relative to the total anterior facial height. S-Go/N-Me: the ratio of the posterior total facial height to the anterior total facial height. Np: vertical line extended from nasion perpendicular to the Frankfort horizontal plane. A-Np: vertical distance from A point to Np. Pg-Np: vertical distance from pogonion to Np. U1-SN: angle between upper mesial incisor, and SN plane. L1-MP: angle between lower mesial incisor and mandibular plane. U1-Np: vertical distance from upper mesial incisor to Np. L1-Np: vertical distance from lower mesial incisor to Np. Ob: overbite. Oj: overjet. TGL: tongue length. TGH: tongue high. VRL: vertical line extended from sella perpendicular to the Frankfort horizontal plane. TT: tip of tongue. TP: the most posterior point of tongue. TD: the most close point to tongue from palatal plane. PP: palatal plane. TT-VRL: vertical distance from TT to VRL. TP-VRL: vertical distance from TP to VRL. TD-PP: vertical distance from TD to PP. TT-PP: vertical distance from TT to PP



VRL: vertical line extended from sella perpendicular to the Frankfort horizontal plane. FH: Frankfort horizontal plane. ANS: anterior nasal spine. PNS: posterior nasal spine. PP: palatal plane. EB: base of epiglottis. TT: tip of tongue. TP: the most posterior point of tongue. TH: the most far point of tongue from EB-TT line. TD: the most close point of tongue to palatal plane. (1)TGL: tongue length; (2) TGH: tongue height; (3)TT-VRL: vertical distance from TT to VRL; (4)TP-VRL: vertical distance from TP to VRL; (5)TD-PP: vertical distance from TD to PP; (6)TT-PP: vertical distance from TT to PP

Figure 1 2D parameters of tongue

图1 舌体二维参数

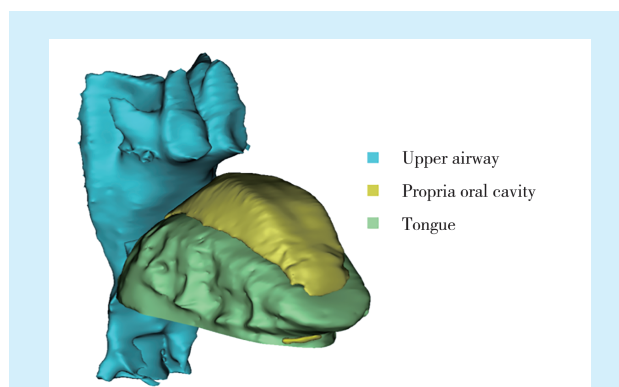


Figure 2 Reconstruction of the tongue, propria oral cavity and upper airway

图2 舌体、固有口腔、上气道重建

1.3.2 三维测量内容 将CBCT的DICOM数据导入Mimics软件进行三维重建并校正头位。参考Ding等^[11]的研究,将舌体积(tongue volume, TV)的上界定为舌背,下界为经过舌系带的平行于PP平面的直线。前界为舌尖,后界为口咽。固有口腔体积(oral cavity proper volume, OCPV)包括舌背和上颚之间的空间以及舌下与口底之间的空间。参考Truong等^[12]的研究,上气道体积(upper airway volume, UAV)的上界定为S点与PNS点连线形成的平面,下界为经过Eb点的平行于FH平面的平面。在矢状、冠状及水平面上逐张涂抹,勾勒出舌体、固有口腔及上气道的形状。三维重建后获得TV、OCPV及UAV(图2)。口腔包括固有口腔及舌体,即口腔体积(oral cavity capacity, OCC)的计算为TV+OCPV,然后再计算TV/OCC的比值,得到舌体积占比。

1.4 统计学分析

为了计算样本量,先进行了预实验。将各组纳入5例,计算其舌体积的均值及标准差。将结果代入G*Power软件进行计算($1-\beta = 0.80, \alpha = 0.05$),显示各组至少需要17例患者。所有数据由同一研究者完成测量,在同一条件下测量2次,间隔1周。将两次测量值进行组内相关系数分析(ICC),得出2次测量值一致性良好($0.79-0.91, P < 0.05$),取两次测量值平均值作为实验数据。将数据导入SPSS 29.0软件进行数据分析。采用Kolmogorov-Smirnov法对各组数据进行正态性检验,采用Levene法检验方差齐性。使用单因素方差分析和Bonferroni事后检验来比较3组数据的差异。计算皮尔逊相关系数来评估舌体积与各参数之间的联系。若变量不满足正态分布或方差不齐,则采用非参数Kruskal-Wallis检验进行组间比较,并计算Spearman相关系数来评估参数之间的关系。

2 结果

2.1 研究对象基本情况

研究对象年龄(24.58 ± 4.84)岁。各组间年龄及后前面高比(S-Go/N-Me)相比无显著性差异,资料具有可比性,ANB角组间差异比较具有统计学意义($F=96.795, P < 0.001$)。见表2。

表2 本研究最终纳入的骨性畸形成年患者基本情况

Table 2 Basic information of adult patients with different skeletal malocclusions included in this study

| Parameters | Skeletal Class I (n = 20) | Skeletal Class II (n = 20) | Skeletal Class III (n = 20) | F | P |
|------------|---------------------------|----------------------------|-----------------------------|--------|---------|
| Age/years | 25.65 ± 5.15 | 24.55 ± 4.30 | 23.55 ± 5.05 | 0.938 | 0.397 |
| ANB/mm | 2.28 ± 1.17 | 5.50 ± 1.06 | -2.74 ± 2.66 | 96.795 | < 0.001 |
| S-Go/N-Me | 0.67 ± 0.04 | 0.64 ± 0.04 | 0.65 ± 0.07 | 2.249 | 0.115 |

ANB: angle between subspinale point A and supramentale point B. S-Go/N-Me: the ratio of the posterior total facial height to the anterior total facial height

2.2 不同骨性畸形组舌体位置及体积的比较

三组骨性畸形患者的舌体位置、舌体积、口腔体积及舌体积占比见表3。骨性Ⅲ类组TGL大于骨性Ⅰ类组及骨性Ⅱ类组($P < 0.05$)。骨性Ⅱ类组舌尖

位置较骨性Ⅰ类组更靠前($P < 0.05$)。骨性Ⅲ类组TV及OCC大于骨性Ⅰ类及骨性Ⅱ类组($P < 0.05$)。骨性Ⅲ类患者的UAV大于骨性Ⅰ类患者($P < 0.05$)。其余参数无显著差异。

表3 不同骨性畸形成年患者舌的位置及体积的差异性分析

Table 3 Differential analysis of tongue position and volume in adult patients with different skeletal malocclusions

| Parameters | Skeletal Class I (n = 20) | Skeletal Class II (n = 20) | Skeletal Class III (n = 20) | F | P ^a | Post hoc ^b |
|----------------------|------------------------------|-------------------------------|--------------------------------|-------|----------------|-----------------------|
| TGL/mm | 67.86 ± 4.52 | 67.27 ± 5.98 | 71.7 ± 4.73 | 4.435 | 0.016 | Ⅲ > Ⅱ; Ⅲ > Ⅰ |
| TGH/mm | 35.46 ± 4.64 | 34.01 ± 4.93 | 36.83 ± 4.76 | 1.736 | 0.185 | |
| TT-VRL/mm | 64.32 ± 8.78 | 70.72 ± 6.58 | 69.48 ± 6.43 | 4.269 | 0.021 | Ⅱ > Ⅰ |
| TP-VRL/mm | 5.1 ± 1.98 | 7.07 ± 4.91 | 7.15 ± 3.49 | 2.001 | 0.108 | |
| TT-PP/mm | 25.11 ± 3.38 | 25.71 ± 5.05 | 26.12 ± 4.62 | 0.266 | 0.768 | |
| TD-PP/mm | 5.71 ± 2.91 | 7.4 ± 4.04 | 7.04 ± 4.57 | 1.039 | 0.403 | |
| TV/cm ³ | 43.51 ± 8.92 | 43.27 ± 8.57 | 50.56 ± 9.52 | 4.222 | 0.02 | Ⅲ > Ⅱ; Ⅲ > Ⅰ |
| OCPV/cm ³ | 4.1 ± 1.41 | 3.52 ± 2.33 | 6.02 ± 4.68 | 3.512 | 0.153 | |
| OCC/cm ³ | 47.61 ± 8.65 | 46.79 ± 8.41 | 55.33 ± 12.2 | 4.527 | 0.015 | Ⅲ > Ⅱ; Ⅲ > Ⅰ |
| TV/OCC | 0.91 ± 0.04 | 0.92 ± 0.05 | 0.90 ± 0.06 | 1.034 | 0.499 | |
| UAV/cm ³ | 22.19 ± 6.33 | 23.95 ± 7.2 | 27.77 ± 6.41 | 3.671 | 0.032 | Ⅲ > Ⅰ |

a: P value represents the result of the analysis of variance. b: statistically significant results($P < 0.05$)of the post hoc tests. TGL: tongue length. TGH: tongue height. TT: tip of tongue. VRL: vertical line extended from sella perpendicular to the Frankfort horizontal plane. TP: the most posterior point of tongue. TD: the most close point of tongue to palatal plane. TT-VRL: vertical distance from TT to VRL. TP-VRL: vertical distance from TP to VRL. TT-PP: vertical distance from TT to PP. TD-PP: vertical distance from TD to PP. TV: tongue volume. OCPV: oral cavity proper volume. OCC: oral cavity capacity. UAV: upper airway volume

2.3 舌体积与牙、骨参数、舌位置参数的相关性分析

舌体积与牙、骨参数、舌位置参数的相关性分析结果见表4。TV与ANB角呈负相关,与SNA角、SNB角、ANS-PNS、Go-Gn及ANS-Me/N-Me呈正相关($P < 0.05$)。TV与U1-SN呈正相关,与Ob、Oj呈负相关($P < 0.01$)。TV与Pg-Np、U1-Np、L1-Np呈显著正相关($P < 0.01$)。TV与上下颌基骨弓宽度、牙弓宽度呈显著正相关($P < 0.01$)。TV与OCC、TGH、TT-VRL、TT-PP呈显著正相关($P < 0.01$)。

2.4 上气道体积与舌体积、舌位置参数的相关性分析

UAV与TT-VRL、TP-VRL呈正相关($P < 0.05$)，其余参数无统计学意义差异(表5)。

3 讨论

在正畸治疗和正颌手术中,舌的位置和体积的评估是制定治疗方案的重要依据。BWS(Beckwith-Wiedemann syndrome)患者伴有巨舌症^[13-14],可能会出现下颌前突、下颌长度增加、前牙开颌和牙弓过宽等症。不良舌习惯的患者往往会伴随着牙前突、

牙列间隙等现象,且若正畸治疗后患者舌习惯未得到纠正,错颌畸形复发的风险较大^[15],因此该类患者需要严格佩戴保持器。对于有呼吸道问题的患者(如obstructive sleep apnea,OSA),舌的位置和体积直接关系到气道的宽度^[16-18],而气道大小是制定正畸或正颌治疗方案的重要参考因素^[19-21]。因此,了解舌的位置和体积在骨性畸形中的差异,对于错颌畸形的诊断、治疗方案的制定及术后保持效果的评估具有重要意义。

3.1 使用CBCT对舌体进行测量

测量舌体的方法多种多样,包括排水量测量、藻酸盐印模^[11]、头影测量侧位片、螺旋CT^[22]、超声^[23]及磁共振成像(magnetic resonance imaging, MRI)^[24]等。头影测量侧位片无法从三维角度对舌体及口腔进行测量。尽管螺旋CT和MRI可以更好地展示舌体及口腔的三维形态,但由于拍摄时患者处于仰卧位,舌体的形状和位置会受到重力的影响。此外,MRI的长时间曝光可能会导致伪影,降低图像质量^[25]。相比之下,CBCT是一种可靠的测量舌体位置和体积的工具,具有较小的辐射量,且拍摄时患者处于坐位,能够避免舌体后坠。目前,CBCT已被用于测量舌体

表4 不同骨性畸形成年患者的舌体积与牙、骨参数、舌位置参数的相关性分析
Table 4 Correlation analysis of tongue volume with tooth, bone and tongue position parameters in adult patients with different skeletal malocclusions

| Parameters | <i>r</i> | <i>P</i> | Parameters | <i>r</i> | <i>P</i> |
|-------------|----------|----------|--------------------------------------|----------|----------|
| ANB | -0.308 | 0.017 | L1-Np | 0.376 | 0.003 |
| SNA | 0.261 | 0.044 | Maxillary dental arch width /mm | 0.548 | < 0.001 |
| SNB | 0.448 | < 0.001 | Maxillary basal bone arch width /mm | 0.417 | < 0.001 |
| MP-SN | -0.206 | 0.114 | Mandibular dental arch width /mm | 0.544 | < 0.001 |
| ANS-PNS | 0.311 | 0.016 | Mandibular basal bone arch width /mm | 0.487 | < 0.001 |
| Go-Gn | 0.525 | < 0.001 | OCPV | -0.078 | 0.551 |
| S-Go/N-Me | 0.119 | 0.364 | OCC | 0.895 | < 0.001 |
| ANS-Me/N-Me | 0.372 | 0.003 | TV/OCC | 0.402 | 0.001 |
| U1-SN | 0.378 | 0.003 | TGL | 0.203 | 0.121 |
| L1-MP | 0.002 | 0.987 | TGH | 0.528 | < 0.001 |
| Ob | -0.404 | 0.001 | TT-VRL | 0.516 | < 0.001 |
| Oj | -0.51 | < 0.001 | TP-VRL | 0.144 | 0.272 |
| A-Np | 0.119 | 0.366 | TD-PP | -0.022 | 0.868 |
| Pg-Np | 0.39 | 0.002 | TT-PP | 0.573 | < 0.001 |
| U1-Np | 0.361 | 0.005 | | | |

ANB: angle between subspinale point A and supramentale point B. SNA: angle between sella, nasion and subspinale point A. SNB: angle between sella, nasion and supramentale point B. MP- SN: angle between SN plane and the mandibular plane angle. ANS- PNS: distance from anterior nasal spine to posterior nasal spine. Go-Gn: distance from gonion to gnathion. S-Go/N-Me: the ratio of the posterior total facial height to the anterior total facial height. ANS-Me/N-Me: the ratio of the lower anterior facial height relative to the total anterior facial height. U1-SN: angle between upper mesial incisor and SN plane. L1-MP: angle between lower mesial incisor and mandibular plane. Ob: overbite. Oj: overjet. Np: vertical line extended from nasion perpendicular to the Frankfort horizontal plane. A-Np: vertical distance from A point to Np. Pg-Np: vertical distance from pogonion to Np. U1-Np: vertical distance from upper mesial incisor to Np. L1-Np: vertical distance from lower mesial incisor to Np. TV: tongue volume. OCPV: oral cavity proper volume. OCC: oral cavity capacity. TGL: tongue length. TGH: tongue height. VRL: vertical line extended from sella perpendicular to the Frankfort horizontal plane. TT: tip of tongue. TP: the most posterior point of tongue. TD: the most close point of tongue to palatal plane. PP: palatal plane. TT-VRL: vertical distance from TT to VRL. TP-VRL: vertical distance from TP to VRL. TD-PP: vertical distance from TD to PP. TT-PP: vertical distance from TT to PP

表5 不同骨性畸形成年患者的上气道体积与舌体积、舌位置参数的相关性分析

Table 5 Correlation analysis of upper airway volume with tongue volume and tongue position parameters in adult patients with different skeletal malocclusions

| Parameters | <i>r</i> | <i>P</i> |
|------------|----------|----------|
| TV | 0.124 | 0.345 |
| OCPV | 0.101 | 0.443 |
| OCC | 0.158 | 0.229 |
| TV/OCC | -0.047 | 0.719 |
| TGL | 0.23 | 0.077 |
| TGH | 0.14 | 0.285 |
| TT- VRL | 0.262 | 0.043 |
| TP- VRL | 0.278 | 0.032 |
| TD- PP | 0.037 | 0.782 |
| TT- PP | 0.059 | 0.655 |

TV: tongue volume. OCPV: oral cavity proper volume. OCC: oral cavity capacity. TGL: tongue length. TGH: tongue height. TT-VRL: vertical distance from TT to VRL. TP-VRL: vertical distance from TP to VRL. TD-PP: vertical distance from TD to PP. TT-PP: vertical distance from TT to PP

积,且被认为是精确可靠的^[26-27]。因此,本研究采用CBCT来精确测量舌体及口腔的各项二维及三维参数。

3.2 舌体积及口腔体积

先前研究已证实^[28],男性和女性的舌体积大小并无显著差异,且预实验结果也显示男性和女性的舌体积及位置无显著差异,故本文未根据性别进行分组。本研究中,舌体积(TV)的平均值为45.78 cm³,高于Uysal等^[28]的测量结果。Uysal等^[28]将舌体的下界定义为经过下颌第一磨牙和前磨牙的釉牙骨质界的平面,而后界定义为经过后鼻脊点的垂直于眶耳平面的平面。本研究认为此测量方式未能反映舌体的真实体积,且TV的测量可能会受到舌体与下颌磨牙之间位置关系的影响。在本研究中,舌体的下界被定义为通过舌系带前缘中点的平行于腭平面的平面,避免了个体间下颌磨牙位置差异对舌体积测量的影响。

本研究结果显示,相比骨性 I 类和骨性 II 类的患者,骨性 III 类患者的舌体积较大,差别具有统计学意义。此外,舌体积与 SNB 角、Go-Gn、Pg-Np 呈显著正相关,表明舌体积与下颌骨的长度及前后向位置关系密切。这与 Iwasaki 等^[29]的研究结果一致,提示较大的舌体积可能是骨性 III 类错殆畸形的病因之一,舌体积较大的患者通常伴有更大、位置更靠前的下颌骨。

本研究还发现,TV 与上下前牙的前后向位置(U1-Np 和 L1-Np)呈显著正相关,表明舌体积可能影响前牙的前后向位置。此外,舌体积与上下颌牙弓宽度及基骨弓宽度的相关性显著,提示较大的舌体积可能会伴随着较大的牙弓宽度和颌骨宽度。若患者上下前牙前突或牙弓宽度较大,可能意味着舌体积较大。已有研究证实^[30-31],舌体在静止状态下会对周围组织施加轻微压力,从而显著影响牙齿的位置。因此,针对此类患者,若通过正畸或正颌手术纠正了前突的前牙或改变了牙弓宽度,治疗结束时应建议长期保持,防止复发。

由于个体之间骨骼结构的差异,其舌体积和口腔体积也可能受到骨骼框架的影响。本研究参考了 Rana 等^[32]的研究,通过计算舌体积在口腔体积中的占比,试图减弱骨骼框架对研究结果的影响。Rana 等^[32]得出 TV/OCC 比率为 89.49%,与本研究结果接近。此外,本研究还发现,3 种骨性畸形中的舌体积占比(TV/OCC)无显著差异,提示舌体积占比可能与骨性畸形的形成无关。同时,本研究未发现 TV 与 OCPV 之间存在相关性,提示舌体积对其周围体积的影响较小。

3.3 舌体位置

Chen 等^[33]通过测量骨性 I 类及骨性 II 类患者的 CBCT 发现,与骨性 I 类患者相比,骨性 II 类患者的舌位较低,舌体较短。然而,本研究未发现 3 种骨性畸形患者在舌位高低方面存在明显差异,这可能与测量方式以及研究对象的差异有关。本研究还发现,UAV 与 TT-VRL、TP-VRL 呈正相关,表明若舌体位置越靠后,上气道体积越小。这提示医师在治疗过程中需密切关注舌体位置的变化。例如在正畸拔牙减数治疗或者正颌手术中,若前牙或颌骨大幅内收导致舌体向后移动,可能会影响上气道体积,进而引起患者不适。

3.4 本研究的局限性

由于本研究样本数量有限,且均角患者远多于高角和低角患者,故未能按垂直骨面型进行分组,无法进一步探讨垂直骨面型对舌位置及体积的影响。今后的研究可进一步完善针对不同垂直骨面型患者

舌位置及体积的研究。其次,本研究主要是聚焦于成年患者,因而无法分析发育过程中舌体对口腔体积、牙弓以及下颌骨位置的影响。后续研究可以青少年为对象,探索舌位置及体积与青少年发育的关系。

4 小结

骨性 III 类患者的舌体积较大,且舌体较长。舌体积较大的患者可能伴有更大、位置更靠前的下颌骨。舌位更靠后的患者可能具有更小的上气道体积。若治疗手段导致舌体向后移动,则可能会使上气道体积减小。因此,在制定正畸或正颌治疗方案时,需重视舌体的位置和体积与颌骨、气道之间的联系,以实现兼顾牙颌形态与口周功能的治疗效果。

[Author contributions] Chiou WC designed the study, collected and analyzed the data, wrote the article. Men XR, Zhang KW, Jiang XG designed the study and revised the article. Chen S designed the study, revised the article, guided and critically reviewed the article structures. All authors read and approved the final manuscript as submitted.

参考文献

- Manlove AE, Romeo G, Venugopalan SR. Craniofacial growth: current theories and influence on management[J]. *Oral Maxillofac Surg Clin North Am*, 2020, 32(2): 167-175. doi: 10.1016/j.coms.2020.01.007.
- Bourdiol P, Hennequin M, Peyron MA, et al. Masticatory adaptation to occlusal changes[J]. *Front Physiol*, 2020, 11: 263. doi: 10.3389/fphys.2020.00263.
- Dydyk A, Milona M, Janiszewska-Olszowska J, et al. Influence of shortened tongue frenulum on tongue mobility, speech and occlusion[J]. *J Clin Med*, 2023, 12(23): 7415. doi: 10.3390/jcm12237415.
- Deshkar M, Thosar NR, Kabra SP, et al. The influence of the tongue on the development of dental malocclusion[J]. *Cureus*, 2024, 16(5): e61281. doi: 10.7759/cureus.61281.
- Sasaki Y, Otsugu M, Sasaki H, et al. Relationship between dental occlusion and maximum tongue pressure in preschool children aged 4-6 years[J]. *Children(Basel)*, 2022, 9(2): 141. doi: 10.3390/children9020141.
- Shinde S, Sethi S, Vasa D, et al. Comparative cephalometric evaluation of tongue position in subjects with skeletal class II division 1 and division 2 malocclusion[J]. *J Orthod Sci*, 2023, 12: 28. doi: 10.4103/jos.jos_94_22.
- Chauhan A, Autar R, Pradhan KL, et al. Comparison of pharyngeal airway dimension, tongue and hyoid bone position based on ANB angle[J]. *Natl J Maxillofac Surg*, 2015, 6(1): 42-51. doi: 10.4103/0975-5950.168237.
- Yılmaz F, Sağdıç D, Karaçay S, et al. Tongue movements in patients with skeletal Class II malocclusion evaluated with real-time balanced turbo field echo cine magnetic resonance imaging[J]. *Am J Orthod Dentofacial Orthop*, 2011, 139(5): e415-e425. doi: 10.1016/j.ajodo.2010.02.031.

- [9] Steiner C. Cephalometrics for you and me[J]. *Am J Orthod*, 1953, 39(10): 729-755. doi: 10.1016/0002-9416(53)90082-7.
- [10] Grover S, Sidhu MS, Singaraju GS, et al. Three-dimensional evaluation of the tongue volume in different dentoskeletal patterns - a cone beam computed tomographic study[J]. *J Pharm Bioallied Sci*, 2021, 13(suppl 1): S137-S142. doi: 10.4103/jpbs.JPBS_614_20.
- [11] Ding X, Suzuki S, Shiga M, et al. Evaluation of tongue volume and oral cavity capacity using cone-beam computed tomography[J]. *Odontology*, 2018, 106(3): 266-273. doi: 10.1007/s10266-017-0335-0.
- [12] Truong L, Reher P, Doan N. Correlation between upper airway dimension and TMJ position in patients with sleep disordered breathing[J]. *Cranio*, 2023, 41(4): 331 - 339. doi: 10.1080 / 08869634.2020.1853465.
- [13] Marsh JL, Perlyn CA. Beckwith-widemann macroglossia: the role of surgical tongue reduction[J]. *Cleft Palate Craniofac J*, 2024, 61(4): 599-609. doi: 10.1177/10556656221148900.
- [14] Kim DW, Kim JK, Huh G, et al. Tongue reduction surgery improves mandibular prognathism in beckwith-wiedemann syndrome without compromising tongue function[J]. *Clin Exp Otorhinolaryngol*, 2023, 16(1): 67-74. doi: 10.21053/ceo.2022.00976.
- [15] Verschuere K, Rajbhaj AA, Begnoni G, et al. Risk factors for orthodontic fixed retention failure: a retrospective controlled study[J]. *Korean J Orthod*, 2023, 53(6): 365 - 373. doi: 10.4041 / kjod23.012.
- [16] Shah RR, Thaler ER. Base of tongue surgery for obstructive sleep apnea in the era of neurostimulation[J]. *Otolaryngol Clin North Am*, 2020, 53(3): 431-443. doi: 10.1016/j.otc.2020.02.006.
- [17] Koka V, De Vito A, Roisman G, et al. Orofacial myofunctional therapy in obstructive sleep apnea syndrome: a pathophysiological perspective[J]. *Medicina(Kaunas)*, 2021, 57(4): 323. doi: 10.3390/medicina57040323.
- [18] Ishman SL, Maturo S, Schwartz S, et al. Expert consensus statement: management of pediatric persistent obstructive sleep apnea after adenotonsillectomy[J]. *Otolaryngol Head Neck Surg*, 2023, 168(2): 115-130. doi: 10.1002/ohn.159.
- [19] Yey Özkeskin SZ, Ersan N, Öztürk Muhtar M, et al. Evaluation of minimum axial airway area and airway volume in orthognathic surgery patients[J]. *J Craniofac Surg*, 2024, 35(7): 1938 - 1946. doi: 10.1097/SCS.0000000000010533.
- [20] Mladenovic M, Freezer S, Dreyer C, et al. The orthodontic extraction of second premolars: the influence on airway volume[J]. *Am J Orthod Dentofacial Orthop*, 2024, 166(1): 61 - 68. doi: 10.1016/j.ajodo.2024.02.013.
- [21] 刘莉, 周嫣, 张大灵, 等. 两种方法矫治骨性Ⅲ类错颌前、后上气道变化的临床研究[J]. *口腔疾病防治*, 2021, 29(8): 541-547. doi: 10.12016/j.issn.2096-1456.2021.08.006.
- Liu L, Zhou Y, Zhang DL, et al. Two methods of treatment for skeletal Class III malocclusion on airway changes before and after clinical research[J]. *J Prev Treat Stomatol Dis*, 2021, 29(8): 541-547. doi: 10.12016/j.issn.2096-1456.2021.08.006.
- [22] Yamazaki M, Suzuki T, Hiraga C, et al. Effect of postoperative radiotherapy for free flap volume changing after tongue reconstruction[J]. *Oral Radiol*, 2021, 37(3): 518-523. doi: 10.1007/s11282-020-00489-0.
- [23] Zheng Z, Ma W, Du R. Effectiveness and validity of midsagittal tongue cross-sectional area and width measured by ultrasound to predict difficult airways[J]. *Minerva Anesthesiol*, 2021, 87(4): 403-413. doi: 10.23736/S0375-9393.20.14769-2.
- [24] Vernikouskaya I, Müller HP, Ludolph AC, et al. AI-assisted automatic MRI-based tongue volume evaluation in motor neuron disease (MND)[J]. *Int J Comput Assist Radiol Surg*, 2024, 19(8): 1579 - 1587. doi: 10.1007/s11548-024-03099-x.
- [25] Sui Y, Afacan O, Gholipour A, et al. MRI super-resolution through generative degradation learning[J]. *Med Image Comput Comput Assist Interv*, 2021, 12906: 430-440. doi: 10.1007/978-3-030-87231-1_42.
- [26] Halim IA, Park JH, Liou EJW, et al. Preliminary study: evaluating the reliability of CBCT images for tongue space measurements in the field of orthodontics[J]. *Oral Radiol*, 2021, 37(2): 256-266. doi: 10.1007/s11282-020-00443-0.
- [27] Aflah KA, Yohana W, Oscandar F. Volumetric measurement of the tongue and oral cavity with cone-beam computed tomography: a systematic review[J]. *Imaging Sci Dent*, 2022, 52(4): 333-342. doi: 10.5624/isd.20220067.
- [28] Uysal T, Yagci A, Ucar FI, et al. Cone-beam computed tomography evaluation of relationship between tongue volume and lower incisor irregularity[J]. *Eur J Orthod*, 2013, 35(5): 555 - 562. doi: 10.1093/ejo/cjr054.
- [29] Iwasaki T, Suga H, Yanagisawa - Minami A, et al. Relationships among tongue volume, hyoid position, airway volume and maxillo-facial form in paediatric patients with Class-I, Class-II and Class-III malocclusions[J]. *Orthod Craniofac Res*, 2019, 22(1): 9-15. doi: 10.1111/ocr.12251.
- [30] Ramos VF, Silva AF, Degan VV, et al. Lip and tongue pressure and the functionality of oro-facial structures in healthy individuals[J]. *J Oral Rehabil*, 2023, 50(10): 991-1001. doi: 10.1111/joor.13531.
- [31] Lee YS, Ryu J, Baek SH, et al. Comparative analysis of the differences in dentofacial morphology according to the tongue and lip pressure[J]. *Diagnostics(Basel)*, 2021, 11(3): 503. doi: 10.3390/diagnostics11030503.
- [32] Rana SS, Kharbanda OP, Agarwal B. Influence of tongue volume, oral cavity volume and their ratio on upper airway: a cone beam computed tomography study[J]. *J Oral Biol Craniofac Res*, 2020, 10(2): 110-117. doi: 10.1016/j.jobcr.2020.03.006.
- [33] Chen W, Mou H, Qian Y, et al. Evaluation of the position and morphology of tongue and hyoid bone in skeletal Class II malocclusion based on cone beam computed tomography[J]. *BMC Oral Health*, 2021, 21(1): 475. doi: 10.1186/s12903-021-01839-y.

(编辑 周春华)



Open Access

This article is licensed under a Creative Commons Attribution 4.0 International License. Copyright © 2025 by Editorial Department of Journal of Prevention and Treatment for Stomatological Diseases



官网