

[DOI]10.12016/j.issn.2096-1456.2022.11.005

· 临床研究 ·

# 儿童阻塞性睡眠呼吸暂停低通气综合征上气道形态的锥形束CT研究

杨文麒<sup>1,2</sup>, 张亚琼<sup>1,2</sup>, 郭靖晗<sup>2,3</sup>, 李远远<sup>2,3</sup>, 韩方凯<sup>1,2</sup>

1.上海市口腔医院放射科,上海(200001); 2.上海市颅颌面发育与疾病重点实验室,上海(200001); 3.上海市口腔医院正畸科,上海(200001)

**【摘要】** 目的 运用锥形束CT(cone beam computed tomography, CBCT)结合多导睡眠图(polysomnography, PSG)评估阻塞性睡眠呼吸暂停低通气综合征(obstructive sleep apnea-hypopnea syndrome, OSAHS)儿童上气道形态,为临床诊疗提供参考。**方法** 回顾分析45例OSAHS患儿与45例对照组儿童的CBCT资料,通过NNT 9.0软件进行三维重建,测量并记录上气道总容积、鼻咽段容积、腭咽段容积、舌咽段容积、喉咽段容积、上气道最小横截面积及最小横截面积处的前后径和横径;根据多导睡眠图(polysomnography, PSG)监测结果,记录阻塞性呼吸暂停低通气指数(obstructive apnea hypopnea index, OAH)和最低血氧饱和度(lowest oxygen saturation, LSaO<sub>2</sub>);记录身体质量指数(body mass index, BMI);分析气道容积参数、BMI与PSG检测结果之间的相关性。**结果** OSAHS组上气道总容积、鼻咽段容积、腭咽段容积、舌咽段容积、喉咽段容积、上气道最小横截面积及最小横截面积处的前后径和横径等测量结果均小于对照组,差异具有统计学意义( $P < 0.05$ )。OSAHS组上气道总容积、最小横截面积、最小横截面积处的横径与OAH呈负相关( $P < 0.05$ )。OSAHS组上气道总容积、最小横截面积、最小横截面积前后径及横径与LSaO<sub>2</sub>之间相关性无统计学意义( $P > 0.05$ )。OSAHS组儿童的BMI与PSG结果之间相关性无统计学意义( $P > 0.05$ )。**结论** OSAHS患儿上气道形态较正常儿童缩窄;CBCT三维气道分析技术对临床评估OSAHS患儿上气道形态及阻塞程度具有一定的价值。

**【关键词】** 锥形束CT; 儿童; 阻塞性睡眠呼吸暂停低通气综合征; 多导睡眠图; 三维成像; 上气道; 上气道总容积; 上气道最小横截面积; 身体质量指数

**【中图分类号】** R783.5 **【文献标志码】** A **【文章编号】** 2096-1456(2022)11-0792-06

**【引用著录格式】** 杨文麒, 张亚琼, 郭靖晗, 等. 儿童阻塞性睡眠呼吸暂停低通气综合征上气道形态的锥形束CT研究[J]. 口腔疾病防治, 2022, 30(11): 792-797. doi:10.12016/j.issn.2096-1456.2022.11.005.

**Cone-beam computed tomography study of upper airway morphology in children with obstructive sleep apnea-hypopnea syndrome** YANG Wenqi<sup>1,2</sup>, ZHANG Yaqiong<sup>1,2</sup>, GUO Jinghan<sup>2,3</sup>, LI Yuanyuan<sup>2,3</sup>, HAN Fangkai<sup>1,2</sup>. 1.

Department of Radiology, Shanghai Stomatological Hospital, Fudan University, Shanghai 200001, China; 2. Shanghai Key Laboratory of Craniomaxillofacial Development and Diseases, Fudan University, Shanghai 200001, China; 3. Department of Orthodontics, Shanghai Stomatological Hospital, Fudan University, Shanghai 200001, China

Corresponding author: HAN Fangkai, Email: han\_fangkai@fudan.edu.cn, Tel: 86-13916969676

**【Abstract】 Objective** To evaluate the morphology of the upper airway of children with obstructive sleep apnea-hypopnea syndrome (OSAHS) using cone-beam computed tomography (CBCT) combined with polysomnography (PSG) and provide references for clinical practice. **Methods** CBCT data of 45 OSAHS children and 45 normal children and PSG data of the OSAHS group were retrospectively collected. Three-dimensional reconstructions were performed using NNT 9.0 software. The total upper airway volume, nasopharyngeal volume, palatopharyngeal volume, glossopharyngeal volume, laryngopharyngeal volume, minimum cross-sectional area, anterior-posterior diameter of the minimum cross-

**【收稿日期】** 2022-01-18; **【修回日期】** 2022-05-10

**【基金项目】** 上海市“科技创新行动计划”扬帆计划项目(21YF1439800);上海市卫健委先进适宜技术推广项目(2019SY041);上海申康医院发展中心,促进市级医院临床技能与临床创新三年行动计划(SHDC2020CR2043B)

**【作者简介】** 杨文麒, 技师, 本科, Email: yang\_wenqi@fudan.edu.cn

**【通信作者】** 韩方凯, 副主任医师, 硕士, Email: han\_fangkai@fudan.edu.cn, Tel: 86-13916969676



微信公众号

tion, and lateral diameter of the minimum cross-section were measured and recorded. According to PSG monitoring results, patients with an obstructive apnea hypopnea index (OAHI) and lowest oxygen saturation (LSaO<sub>2</sub>) were assessed. Body mass index (BMI) was recorded. The correlation between airway volume parameters, BMI and PSG test results was analyzed. **Results** The total upper airway volume, nasopharyngeal volume, palatopharyngeal volume, glossopharyngeal volume, laryngopharyngeal volume, minimum cross-sectional area, anterior-posterior diameter of the minimum cross-section, and lateral diameter of the minimum cross-section of the OSAHS group were significantly reduced compared with those of the control group ( $P < 0.05$ ). In the OSAHS group, the total upper airway volume, the minimum cross-sectional area and the lateral diameter of the minimum cross-section showed moderate negative correlations with the obstructive apnea hypopnea index (OAHI) ( $P < 0.05$ ). Moreover, the total upper airway volume, minimum cross-sectional area, anterior-posterior diameter of the minimum cross-section and lateral diameter of the minimum cross-section showed no correlation with the minimum blood oxygen saturation ( $P > 0.05$ ). No significant correlation was noted between BMI and PSG in the OSAHS group ( $P > 0.05$ ). **Conclusion** The morphology of the upper airway of children with OSAHS was significantly smaller than that of normal children. CBCT three-dimensional technology for analyzing the upper airway has a certain value in evaluating the morphology and degree of obstruction of the upper airway in children with OSAHS.

**【Key words】** cone beam CT; children; obstructive sleep apnea hypopnea syndrome; polysomnography; three-dimensional imaging; upper airway; total upper airway volume; minimum cross sectional area of the upper airway; body mass index

**J Prev Treat Stomatol Dis, 2022, 30(11): 792-797.**

**【Competing interests】** The authors declare no competing interests.

This study was supported by grants from the Shanghai "Science and Technology Innovation Action Plan" Sailing Plan Project (No. 21YF1439800); Advanced and Appropriate Technology Promotion Project of Shanghai Municipal Health Commission (No. 2019SY041); and the Shanghai Shenkang Hospital Development Center, Three-Year Action Plan for Promoting Clinical Skills and Clinical Innovation of Municipal Hospitals (No. SHDC2020CR2043B).

儿童阻塞性睡眠呼吸暂停低通气综合征 (obstructive sleep apnea-hypopnea syndrome, OSAHS) 是指睡眠期间长时间的部分上呼吸道阻塞和/或间歇性完全阻塞 (阻塞性呼吸暂停), 影响儿童正常通气和睡眠结构从而引发的一系列病理生理变化的临床综合征<sup>[1]</sup>。根据流行病学调查显示, 儿童 OSAHS 的患病率为 1%~4%<sup>[2]</sup>。OSAHS 患儿睡眠时往往出现低氧血症、高碳酸血症<sup>[3]</sup>, 导致患儿注意力缺陷、多动障碍、颌颌面畸形、发育迟缓、认知发育障碍、心血管系统疾病等一系列并发症<sup>[4-5]</sup>。因此儿童 OSAHS 的早期发现、诊断和干预治疗对其预后有着重要意义。多导睡眠图 (polysomnography, PSG) 被认为是诊断儿童 OSAHS 的金标准<sup>[6-7]</sup>, 然而 PSG 费用昂贵, 监测过程耗时长, 受试者需在睡眠中心就寝, 临床应用存在着局限性, 且无法提供上气道完整的结构形态<sup>[8]</sup>。以往的大部分研究对上气道多采用头颅定位侧位片, 二维数据的测量分析往往存在着维度空间方面自身的局限性<sup>[9-10]</sup>。锥形束 CT (cone beam computed tomography, CBCT) 与传统医用 CT 相比, 具有较低的辐射剂量、较高的空间分辨率、较快的成像速度、费用低等优点<sup>[11]</sup>。CBCT 的缺陷在于对软组织成像不

佳, 但由于空气与软组织的密度差异较大, CBCT 能很好地区分软硬组织和上气道的边界, 使其对上气道的三维形态结构的定量测量成为可能<sup>[12]</sup>。

本研究通过比较 OSAHS 患儿与正常儿童的 CBCT 图像, 测量分析其上气道三维形态的差异, 并根据最新版本《中国儿童阻塞性睡眠呼吸暂停诊断与治疗指南 (2020)》的诊断指标结合 PSG 对 OSAHS 患儿的上气道形态进行分析, 探讨使用 CBCT 评估儿童 OSAHS 的准确性, 以为临床提供参考。

## 1 资料和方法

### 1.1 研究对象

本研究为回顾性研究, 筛选 2020 年至 2021 年在上海市口腔医院正畸科及儿童口腔科就诊患儿, 查阅病历资料, 纳入完成 CBCT 图像检测者, OSAHS 组患儿需有睡眠监测结果, 报告由呼吸内科医生出具。根据中华医学会 OSAHS 的诊断标准, 记录身体质量指数 (body mass index, BMI)、阻塞性呼吸暂停低通气指数 (obstructive apnea hypopnea index, OAHI) 及最低血氧饱和度 (lowest oxygen saturation, LSaO<sub>2</sub>), 将 OAHI > 1 次/h 和 LSaO<sub>2</sub> ≤ 92%

定义为儿童 OSAHS 的诊断标准<sup>[6]</sup>。该项研究已通过上海市口腔医院伦理委员会审核(批件号:沪口防伦审[2020]015号)。

OSAHS 组纳入标准:①年龄 7~14 岁;②经临床医生诊断为口呼吸患儿;③且经 PSG 诊断为 OSAHS, OAHl>1 次/h, LSaO<sub>2</sub> ≤92%;④有颌面部 CBCT 影像学资料(包含会厌基底部)。对照组纳入标准:①年龄 7~14 岁;②经临床医生记录无口呼吸表现;③患儿自述且家属证实鼻腔通畅、无夜间睡眠鼾症、无呼吸暂停症状、无上呼吸道及肺部疾病;④有颌面部 CBCT 影像学资料(包含会厌基底部)。排除标准:①有腺样体或扁桃体手术史;②有正畸或颌骨手术史;③先天性颅面部畸形及颌面部综合征性畸形患者;④颌面部其他疾患,如外伤、肿瘤等;⑤遗传性疾病,认知缺陷,神经肌肉疾病。

## 1.2 CBCT 图像获取

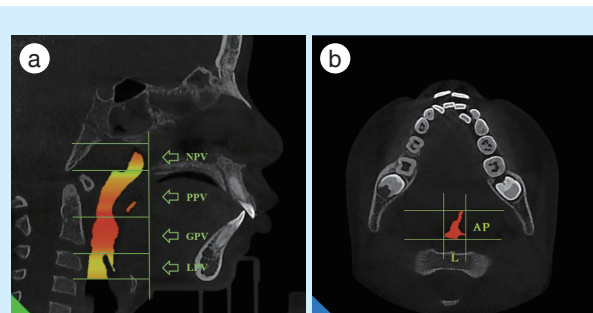
所有患者都由同一台 CBCT(NewTom VG, Italy)进行三维扫描。扫描参数:管电压 110 kV,管电流 5 mA,曝光时间 3.6 s,扫描视野 15 cm×15 cm。拍摄时,患儿处于直立位,采用自然头位并使用头颅固定器固定,上下颌处于牙尖交错位,平静自由鼻呼吸。嘱咐患儿拍摄中不能进行吞咽和其他动作,以法兰克福平面(Frankfort Horizontal plane, FH 平面)为扫描基准线,所得图像重建层厚 0.3 mm,以 DICOM 3.0 格式保存并输出至 NNT 9.0 软件进行三维测量分析。

## 1.3 图像处理与测量方法

在 NNT 9.0 软件上进行头位矫正,采用三点定义法,以右眼眶点为原点,左、右耳点为另外两点定义 FH 平面,确定横断面;冠状面选择左、右耳点横向连接且垂直于横断面;正中矢状位通过左、右耳点连线的中点分别垂直于横断面和冠状面。运用容积测量模块,选择高分辨率模式,调整感兴趣区域(region of interest, ROI)灰度阈值为-1 000~-400,运用自动测量生成上气道横截面积及容积变化曲线,定位上气道最小横截面积,并设定色彩渲染以进行更好的三维观察。

上气道的 ROI 上界设定为与 FH 平面平行的鼻咽顶平面,下界设定为与 FH 平面平行的会厌基底部平面,前界为过后鼻棘点同时与 FH 平面和正中矢状面垂直的平面,后界止于颈椎锥体。以硬腭水平、软腭尖、会厌尖上缘分别与 FH 平面平行的平面将上气道分为鼻咽段、腭咽段、舌咽段、喉咽

段四个部分。测量指标:上气道总容积(upper airway volume, UPV)、鼻咽段容积(nasopharynx volume, NPV)、腭咽段容积(palatopharyngeal volume, PPV)、舌咽段容积(glossopharyngeal volume, GPV)、喉咽段容积(laryngopharynx volume, LPV)、上气道最小横截面积(minimum cross sectional area, min CSA)、最小横截面前后径(anterior-posterior diameter of the minimum cross-section, AP)、最小横截面横径(图 1)。



a: upper airway was segmented and marked; b: minimum cross section of the upper airway. NPV: nasopharynx volume; PPV: palatopharyngeal volume; GPV: glossopharyngeal volume; LPV: laryngopharynx volume; AP is the anterior-posterior diameter of the minimum cross-section, and L is the lateral diameter of the minimum cross-section

Figure 1 Upper airway measurements

图 1 上气道测量指标

## 1.4 统计学分析

采用 SPSS 22.0 软件进行统计分析,定量资料符合正态分布时,以均数±标准差表示,用 *t* 检验比较组间差异;不符合正态分布时,数据以中位数(上、下四分位数)表示,采用 Mann-Whitney *U* 检验进行比较。分类变量采用卡方检验。用 Spearman 秩相关检验分析 OSAHS 组上气道总容积、上气道最小横截面积、最小横截面积前后径、最小横截面积横径与 OAHl、LSaO<sub>2</sub> 的相关性。*P* < 0.05 为差异具有统计学意义。

## 2 结果

纳入 2020 至 2021 年在上海市口腔医院正畸科及儿童口腔科就诊患儿共 90 例,其中 OSAHS 组 45 例,年龄中位数为 8(7, 10)岁, OAHl 的中位数为 3.650(2.100, 6.275)次/h, LSaO<sub>2</sub> 中位数为 89%(83%, 91%);对照组 45 例,年龄中位数为 9(7, 11)岁。OSAHS 组与对照组的年龄、性别、BMI 指数差异无统计学意义(*P* > 0.05)(表 1)。

表1 OSAHS组与对照组儿童一般情况

Table 1 Demographic characteristics of the OSAHS and control groups

Measurement index	OSAHS group	Control group	Median ( $P_{25}, P_{75}$ )	
			$\chi^2/Z$	$P$
Age/year	8 (7, 10)	9 (7, 11)	-1.115	0.265
Male/Female(n)	22/23	26/19	0.714	0.398
BMI/ (kg/m <sup>2</sup> )	16.7(15.6, 18.6)	16.1(15.1, 18.3)	-0.965	0.335

### 2.1 OSAHS组与对照组儿童上气道CBCT测量结果

OSAHS患儿的上气道总容积、鼻咽段容积、腭咽段容积、舌咽段容积、喉咽段容积、最小横截面积、最小横截面积前后径及横径均小于对照组,且差异具有统计学意义( $P < 0.05$ )(表2)。OSAHS组

最小横截面积主要位于鼻咽段及腭咽段,其中腺样体及扁桃体肥大患者占比84%。

### 2.2 OSAHS组儿童上气道CBCT测量结果及BMI指数与PSG结果的相关性

OSAHS组中上气道总容积( $r = -0.321, P = 0.031$ )、上气道最小横截面积( $r = -0.338, P = 0.023$ )、最小横截面积横径( $r = -0.422, P = 0.004$ )与OAHl均呈中度负相关。上气道总容积、上气道最小横截面积、最小横截面积前后径、最小横截面积横径与LSaO<sub>2</sub>指数均无相关性( $P > 0.05$ )。OSAHS组的BMI值与OAHl及LSaO<sub>2</sub>均无相关性( $P > 0.05$ )(表3)。

表2 OSAHS组与对照组儿童上气道CBCT测量结果

Table 2 CBCT measurements of the OSAHS and control groups

Measurement index	OSAHS group	Control group	mm <sup>3</sup> , Median ( $P_{25}, P_{75}$ )	
			$t/Z$	$P$
UPV	9 570 (7 930, 12 470)	12 920 (11 260, 17 620)	-4.555	< 0.001
NPV	2 590 (1 900, 3 190)	3 750 (2 810, 5 140)	-4.507	< 0.001
PPV	3 600 (2 850, 4 770)	4 930 (3 280, 6 570)	-2.716	0.007
GPV	2 100 (1 480, 2 670)	2 650 (1 800, 4 230)	-2.627	0.009
LPV	1 510 (1 110, 2 270)	2 310 (1 970, 2 920)	-3.894	< 0.001
min CSA[mm <sup>2</sup> , ( $\bar{x} \pm s$ )]	71.526 ± 31.402	124.204 ± 44.160	-6.521	< 0.001
AP/mm	7.500 (5.700, 9.300)	9.80 (8.700, 11.700)	-3.830	< 0.001
L [mm, ( $\bar{x} \pm s$ )]	17.687 ± 5.427	21.260 ± 4.896	-3.279	0.001

UPV: upper airway volume; NPV: nasopharynx volume; PPV: palatopharyngeal volume; GPV: glossopharyngeal volume; LPV: laryngopharynx volume; min CSA: minimum cross sectional area; AP: anterior-posterior diameter of the minimum cross-section; L: lateral diameter of the minimum cross-section; OSAHS: obstructive sleep apnea-hypopnea syndrome

表3 OSAHS组儿童上气道CBCT测量结果与PSG结果之间的相关性

Table 3 Correlation between CBCT measurements and PSG parameters in the OSAHS group

Measurement index	OAHl		Measurement index	LSaO <sub>2</sub>	
	$r$	$P$		$r$	$P$
UPV	-0.321	0.031	UPV	0.202	0.184
min CSA	-0.338	0.023	min CSA	0.180	0.238
AP	-0.245	0.105	AP	0.108	0.479
L	-0.422	0.004	L	0.171	0.261
BMI	0.294	0.050	BMI	-0.007	0.965

UPV: upper airway volume; min CSA: minimum cross sectional area; AP: anterior-posterior diameter of the minimum cross-section; L: lateral diameter of the minimum cross-section; BMI: body mass index; OAHl: obstructive apnea hypopnea index; LSaO<sub>2</sub>: lowest oxygen saturation; OSAHS: obstructive sleep apnea-hypopnea syndrome; PSG: polysomnography

### 3 讨论

近年来,儿童OSAHS因其较高的患病率和严

重的远期并发症,引起了广泛关注。以往研究发现,儿童OSAHS的发病机制与上气道的狭窄和阻塞直接相关,其中以异常的腺样体和/或扁桃体所致的上气道阻塞最为常见<sup>[13-14]</sup>。颌骨形态的异常也会导致上气道形态的改变,如下颌后缩可以是OSAHS的原发因素,也可以是睡眠呼吸暂停引起的长期异常口呼吸所导致的结果<sup>[15]</sup>。因此,儿童OSAHS的诊断需要影像学检查和PSG等多学科会诊,达到早干预、早治疗的目的。

本研究使用CBCT对OSAHS患儿及对照组儿童的上气道形态进行三维评估,结合OSAHS患儿的PSG结果进行综合分析。其中OSAHS组的上气道总容积、鼻咽段容积、腭咽段容积、舌咽段容积、喉咽段容积、最小横截面积均小于对照组,与既往研究结果相符,OSAHS患儿的上气道容积及三维形态较正常儿童明显缩小<sup>[16-17]</sup>,提示上气道形态的改变在诊断OSAHS气道阻塞时具有一定的参考

价值。

OSAHS的病理生理学原因是上气道容积不足,临床治疗手段均旨在增加上气道容积以改善气道的阻塞症状<sup>[18]</sup>。本研究结果显示OSAHS组腺样体、扁桃体所在的鼻咽段及舌咽段容积明显小于对照组,与Hsu等<sup>[16]</sup>的研究结果类似,可能是儿童生长发育期间,由于腺样体、扁桃体肥大引起的上气道解剖结构的异常改变,导致腺样体和扁桃体所在的鼻咽段及舌咽段容积减少从而引发OSAHS的表现。本研究结果还显示,OSAHS组腭咽段的容积明显小于对照组,形态学分析也表明OSAHS组患儿的软腭较长,悬雍垂较宽。Enciso等<sup>[19]</sup>研究也显示OSAHS成人往往有更大的软腭体积以及更小的腭咽气道容量,提示儿童OSAHS中软腭形态的异常亦可导致类似于成人气道形态的阻塞。此外,成人OSAHS因软腭松弛肥大低垂、悬雍垂粗大及过度下垂导致在吸气时胸腔负压的作用下,软腭、舌坠入咽腔紧贴咽后壁造成上气道阻塞<sup>[20]</sup>。因此,成人上气道测量主要集中在腭咽及舌咽段,而儿童的上气道形态处于生长发育阶段,由于腺样体和扁桃体在7岁之后不断萎缩,上气道形态也随之发生改变,因此,儿童OSAHS的上气道检查应包含鼻咽段、腭咽段及舌咽段。

上气道的最小横截面与OSAHS阻塞点位常表现出高度的一致性,可作为评估OSAHS发病机制的重要指标<sup>[21]</sup>。相较于将AHI或OAI指数作为儿童OSAHS诊断的指标,本研究根据最新版本指南<sup>[7]</sup>将OAIH<sub>1</sub> > 1次/h和LSaO<sub>2</sub> ≤ 92%定义为儿童OSAHS的诊断标准,强调了阻塞因素导致的睡眠呼吸暂停和低通气在儿童OSAHS诊断中的重要性,从疾病定义的病因出发,强调阻塞性因素是引起OSAHS患儿一系列病理生理变化的根源问题。本研究显示OSAHS组患儿的上气道最小横截面积以及最小横截面积前后径和最小横截面积横径都小于对照组。OSAHS组中上气道总容积、最小横截面积及最小横截面积横径与OAIH<sub>1</sub>指数呈中度负相关,但与LSaO<sub>2</sub>无明显相关性。提示OSAHS患儿上气道最小横截面积及气道最小横截面积横径的减小可能是导致OSAHS的因素之一,这与Masoud等<sup>[22]</sup>研究结果一致。此外,在形态学上分析显示,OSAHS组患儿的上气道最小横截面积更趋向于圆形,而对对照组的最小横截面积多为椭圆形,与Momany等<sup>[23]</sup>研究结果相类似。可能因为最小横截面积的前后径和横径因阻塞点位的结构形

态发生了缩小,导致上气道阻塞以及OSAHS患者咽部形状的改变,使其更容易塌陷。因此,对儿童OSAHS治疗时应侧重于增加上气道阻塞部分的最小横截面积和气道容量,并根据最小横截面出现的点位进行前后径或是左右横径的扩大调整。

本研究存在一定的局限性,首先样本量较小,后续可增加样本量探讨不同亚组(年龄、性别、地域、胖瘦程度等)OSAHS患儿的CBCT三维图像数据,验证上述结果的可靠性。其次本研究的对照组没有多导睡眠图数据。对照组的纳入依赖于临床评估标准,因此可能存在干扰因素。最后,尽管本研究CBCT的图像是基于标准自然头位站立位扫描获取的,这也是绝大多数对上气道形态结构进行研究所采取的拍摄头位,但不同体位获取的上气道图像可能存在差异,由于重力和头位,上气道和周围软组织的形态也会发生相应变化。尽管后期通过软件进行头位矫正来减少这一偏差,但无法消除软组织对上气道产生的影响。

综上所述,OSAHS患儿的上气道总容积、鼻咽段容积、腭咽段容积、舌咽段容积、喉咽段容积、最小横截面积,及最小横截面积前后径和横径均小于对照组儿童;OSAHS患儿上气道容积、最小横截面积及气道最小横截面积横径的减小可能是导致出现OSAHS的主要因素之一。CBCT三维成像技术能有效评估OSAHS患儿的上气道形态结构,为临床筛查诊疗及术前评估提供影像学参考价值。

**【Author contributions】** Yang WQ performed the research and wrote the article. Zhang YQ analyzed the data. Guo JH, LI YY performed the research. Han FK revised the article. All authors read and approved the final manuscript as submitted.

#### 参考文献

- [1] Chan KC, Au CT, Hui LL, et al. How OSA evolves from childhood to young adulthood: natural history from a 10-year follow-up study [J]. *Chest*, 2019, 156(1): 120-130. doi: 10.1016/j.chest.2019.03.007.
- [2] Lumeng JC, Chervin RD. Epidemiology of pediatric obstructive sleep apnea[J]. *Proc Am Thorac Soc*, 2008, 5(2): 242-252. doi: 10.1513/pats.200708-135MG.
- [3] 刘静,常丽,曹玲. 儿童阻塞性睡眠呼吸暂停的研究进展[J]. *中国医刊*, 2021, 56(7): 717-720. doi:10.3969/j.issn.1008-1070.2021.07.007.
- [4] Liu J, Chang L, Cao L. Research progress of obstructive sleep apnea in children [J]. *Chin J medicine*, 2021, 56 (7): 717-720. doi: 10.3969/j.issn.1008-1070.2021.07.007.
- [4] Shen L, Lin Z, Lin X, et al. Risk factors associated with obstructive sleep apnea-hypopnea syndrome in Chinese children: a single center retrospective case-control study[J]. *PLoS one*, 2018, 13(9):

- e0203695. doi:10.1371/journal.pone.0203695.
- [5] Chawla J, Harris MA, Black R, et al. Cognitive parameters in children with mild obstructive sleep disordered breathing[J]. *Sleep Breath*, 2021, 25(3): 1625-1634. doi: 10.1007/s11325-020-02264-1.
- [6] 贺红.《阻塞性睡眠呼吸暂停低通气综合征与口腔正畸:美国口腔正畸医师协会白皮书》解读[J]. *中华口腔医学杂志*, 2020, 55(9): 667-672. doi: 10.3760/cma.j.cn112144-20191224-00465.
- He H.《Obstructive sleep apnea hypopnea syndrome and orthodontics: Interpretation of the white paper of the American Association of orthodontists》[J]. *Chin J Stomatol*, 2020, 55 (9): 667-672. doi: 10.3760/cma.j.cn112144-20191224-00465.
- [7] 中国儿童OSA诊断与治疗指南制订工作组,中华医学会耳鼻咽喉头颈外科学分会小儿学组,中华医学会儿科学分会呼吸学组,等.中国儿童阻塞性睡眠呼吸暂停诊断与治疗指南(2020)[J]. *中国循证医学杂志*, 2020, 20(8): 883-900. doi: 10.7507/1672-2531.202005147.
- Working group for the development of guidelines for the diagnosis and treatment of OSA in Chinese children, pediatric group of Otolaryngology Head and neck surgery branch of Chinese Medical Association, respiratory group of science branch of Chinese Medical Association, et al. Guidelines for the diagnosis and treatment of obstructive sleep apnea in Chinese children (2020) [J]. *Chin J evidence based medicine*, 2020, 20 (8): 883-900. doi: 10.7507/1672-2531.202005147.
- [8] Grasso I, Haigney M, Mortara D, et al. Detection of sleep-disordered breathing with ambulatory Holter monitoring[J]. *Sleep Breath*, 2018, 22(4): 1021-1028. doi:10.1007/s11325-018-1623-9.
- [9] Galeotti A, Festa P, Viarani V, et al. Correlation between cephalometric variables and obstructive sleep apnoea severity in children [J]. *Eur J Paediatr Dent*, 2019, 20(1): 43 - 47. doi: 10.23804/ejpd.2019.20.01.09.
- [10] Stipa C, Cameli M, Sorrenti G, et al. Relationship between cephalometric parameters and the apnoea-hypopnoea index in OSA patients: a retrospective cohort study[J]. *Eur J Orthod*, 2020, 42(1): 101-106. doi: 10.1093/ejo/cjz038.
- [11] Gurgel M, Cevidanes L, Pereira R, et al. Three-dimensional craniofacial characteristics associated with obstructive sleep apnea severity and treatment outcomes[J]. *Clin Oral Investig*, 2022, 26 (1): 875-887. doi: 10.1007/s00784-021-04066-5.
- [12] Pirelli P, Fiaschetti V, Fanucci E, et al. Cone beam CT evaluation of skeletal and nasomaxillary complex volume changes after rapid maxillary expansion in OSA children[J]. *Sleep Med*, 2021, 86(10): 81-89. doi: 10.1016/j.sleep.2021.08.011.
- [13] Fehrm J, Nerfeldt P, Browaldh N, et al. Effectiveness of adenotonsillectomy vs watchful waiting in young children with mild to moderate obstructive sleep apnea: a randomized clinical trial[J]. *JAMA Otolaryngol Head Neck Surg*, 2020, 146(7): 647 - 654. doi: 10.1001/jamaoto.2020.0869.
- [14] Kim JE, Hwang KJ, Kim SW, et al. Correlation between craniofacial changes and respiratory improvement after nasomaxillary skeletal expansion in pediatric obstructive sleep apnea patients[J]. *Sleep Breath*, 2021. doi: 10.1007/s11325-021-02426-9.
- [15] 曾祥龙,高雪梅.儿童口呼吸的诊断与处理[J]. *中华口腔医学杂志*, 2020, 55(1): 3-8. doi: 10.3760/cma.j.issn.1002-0098.2020.01.002.
- Zeng XL, Gao XM. Diagnosis and treatment of oral breathing in children[J]. *Chin J Stomatol*, 2020, 55 (1): 3-8. doi: 10.3760/cma.j.issn.1002-0098.2020.01.002.
- [16] Hsu WC, Kang KT, Yao CJ, et al. Evaluation of upper airway in children with obstructive sleep apnea using cone-beam computed tomography[J]. *Laryngoscope*, 2021, 131(3): 680 - 685. doi: 10.1002/lary.28863.
- [17] 蔡晓红,梅红芳,曹红超,等.鼾症儿童的上气道结构CT形态学研究[J]. *温州医科大学学报*, 2015(9): 636-640. doi: 10.3969/j.issn.2095-9400.2015.09.003.
- Cai XH, Mei HF, Cao HC, et al. CT morphological study of upper airway structure in snoring children [J] *J Wenzhou Medi University*, 2015 (9): 636-640. doi:10.3969/j.issn.2095-9400.2015.09.003.
- [18] Li Y, Wu J, Guo J, et al. The efficacy of different treatment approaches for pediatric OSAHS patients with mandibular retrognathia: study protocol for a multicenter randomized controlled trial [J]. *Trials*, 2020, 21(1): 595. doi: 10.1186/s13063-020-04398-9.
- [19] Enciso R, Shigeta Y, Nguyen M, et al. Comparison of cone-beam computed tomography incidental findings between patients with moderate/severe obstructive sleep apnea and mild obstructive sleep apnea/healthy patients[J]. *Oral Surg Oral Med Oral Pathol Oral Radiol*, 2012, 114(3): 373-381. doi: 10.1016/j.oooo.2012.03.014.
- [20] Tikku T, Khanna R, Sachan K, et al. Dimensional and volumetric analysis of the oropharyngeal region in obstructive sleep apnea patients: a cone beam computed tomography study[J]. *Dent Res J (Isfahan)*, 2016, 13(5): 396-404. doi: 10.4103/1735-3327.192273.
- [21] Iwasaki T, Sugiyama T, Yanagisawa-Minami A, et al. Effect of adenoids and tonsil tissue on pediatric obstructive sleep apnea severity determined by computational fluid dynamics[J]. *J Clin Sleep Med*, 2020, 16(12): 2021-2028. doi: 10.5664/jcs.m.8736.
- [22] Masoud AI, Alwadei AH, Gowharji LF, et al. Relating three-dimensional airway measurements to the apnea-hypopnea index in pediatric sleep apnea patients[J]. *Orthodontics Craniofacial Res*, 2021, 24(1): 137-146. doi: 10.1111/ocr.12417.
- [23] Momany SM, AlJamal G, Shugaa-Addin B, et al. Cone beam computed tomography analysis of upper airway measurements in patients with obstructive sleep apnea[J]. *Am J Med Sci*, 2016, 352 (4): 376-384. doi: 10.1016/j.amjms.2016.07.014.

(编辑 罗燕鸿,何武林)



官网