

[DOI] 10.12016/j.issn.2096-1456.2022.10.005

· 临床研究 ·

成人颞下颌关节强直及其继发畸形的分类与治疗

王瑞宇, 姜楠, 曹品银, 刘尧, 祝颂松, 毕瑞野

口腔疾病研究国家重点实验室 国家口腔疾病临床医学研究中心 四川大学华西口腔医院正颌及关节外科, 四川成都(610041)

【摘要】 目的 建立成人颞下颌关节强直分类新体系,指导不同临床特点的成人颞下颌关节强直(temporomandibular joint ankylosis, TMJA)患者治疗方案的制定。**方法** 提出基于成人颞下颌关节功能重建的“CD”强直分类法,即髁突残留情况(C)、牙颌面畸形程度(D)分类法。选取2016年1月至2020年4月就诊于四川大学华西口腔医院正颌及关节外科的TMJA患者共56例(73侧强直关节),采用“CD”分类法将患者分为4个亚类,分别为内侧髁突头部分残留且无明显骨性错颌(C+D-)、内侧无髁突头残留且无明显骨性错颌(C-D-)、内侧髁突头部分残留且伴骨性错颌(C+D+)、内侧无髁突头残留且伴骨性错颌(C-D+)。对不同亚类患者采取不同的颞下颌关节重建治疗策略并进行随访。“C+”:采取关节外侧成形术(lateral arthroplasty, LAP),在解除强直的同时保留内侧残留髁突;“C-”:强直骨球较小,升支高度丧失不明显,行关节间隙成形解除强直;强直骨球较大,升支高度降低明显,解除强直后行关节重建;“D+”:同期或分期采用外科手段矫治继发牙颌面畸形;“D-”:术后进行正畸治疗改善咬合关系,口腔疾病对症治疗。**结果** 根据“CD”分类法采取不同颞下颌关节强直手术治疗策略后,56例患者共73侧关节强直全部解除,平均开口度由(3.6±3.2)mm提升至(32.8±5.4)mm($P < 0.001$)。术后随访12~48个月,未见关节强直复发。**结论** “CD”分类法对高效指导成人关节强直患者临床方案的制定有积极指导意义,也有利于将颞下颌关节功能重建的理念在更多单位进行推广。

【关键词】 成人颞下颌关节强直; 分类方法; 牙颌面畸形; 颞下颌关节重建; 关节外侧成形术; 正颌手术; 关节间隙成形术; 正畸治疗

【中图分类号】 R78 **【文献标志码】** A **【文章编号】** 2096-1456(2022)10-0712-06

【引用著录格式】 王瑞宇,姜楠,曹品银,等.成人颞下颌关节强直及其继发畸形的分类与治疗[J].口腔疾病防治,2022,30(10):712-717. doi:10.12016/j.issn.2096-1456.2022.10.005.



微信公众号

Classification for treatment of adult temporomandibular joint ankylosis and its secondary malformations

WANG Ruiyu, JIANG Nan, CAO Pinyin, LIU Yao, ZHU Songsong, BI Ruiye. State Key Laboratory of Oral Diseases & National Clinical Research Center for Oral Diseases & Department of Orthognathic and TMJ Surgery, West China Hospital of Stomatology, Sichuan University, Chengdu 610041, China

Corresponding author: BI Ruiye, Email: david-bry@foxmail.com, Tel: 86-28-85503530

【Abstract】 Objective To generate a new classification for adult temporomandibular joint ankylosis (TMJA), which could effectively guide treatment strategies for adult TMJA patients with various clinical features. **Methods** We developed a new "CD" classification system according to the preservation of the condyle (C) and the severity of dentofacial bone deformity (D). From January 2016 to April 2020, 56 TMJ patients (with 73 ankylosed joints) in our department were classified into 4 subgroups by 'CD' classification: condylar head preservation but no dentofacial deformities (C+D-), no condylar head preservation and no dentofacial deformities (C-D-), condylar head preservation and dentofacial deformities (C+D+), and no condylar head preservation but dentofacial deformities (C-D+). Different strategies were used according to the clinical features of each subgroup. The clinical outcomes of these patients were analyzed. Different treatment strategies of temporomandibular joint reconstruction were adopted for different subclasses of patients and

【收稿日期】 2022-03-05; **【修回日期】** 2022-04-07

【基金项目】 国家自然科学基金项目(81771097、81801003);四川大学创新研究项目(2022SCUH0022)

【作者简介】 王瑞宇, 硕士, Email: wry_kqyx@163.com

【通信作者】 毕瑞野, 副教授, 博士, Email: david-bry@foxmail.com, Tel: 86-28-85503530

were followed. "C+": lateral arthroplasty (LAP) was used to remove the rigidity and preserve the medial residual condyle. "C-": if the ankylosing bone ball is small and the loss of ascending branch height is not obvious, arthroplasty should be performed to relieve ankylosis; however, if the ankylosing bone ball is large and the ascending branch height decreases significantly, joint reconstruction should be carried out after the ankylosis is relieved. "D+": surgical treatment of secondary dental and maxillofacial malformations at the same time or over stages. "D-": orthodontic treatment after operation to improve occlusal relationship and symptomatic treatment of oral diseases. **Results** After treatment, all 73 ankylosed joints were completely released, and the average maximal interincisal opening increased from (3.6 ± 3.2) to (32.8 ± 5.4) mm ($P < 0.001$), with no recurrence of ankylosis found during the 12-48 month follow-up period.

Conclusion The generation and elaboration of a 'CD' classification system is intended to help as a TMJA reconstruction guide for adult TMJA treatment and be widely used in more hospitals.

【Key words】 adult temporomandibular joint ankylosis; classification method; dentofacial deformity; temporomandibular joint reconstruction; lateral arthroplasty; orthognathic surgery; gap arthroplasty; orthodontic treatment
J Prev Treat Stomatol Dis, 2022, 30(10): 712-717.

【Competing interests】 The authors declare no competing interests.

This study was supported by the grants from National Natural Science Foundation of China (No. 81771097, No. 81801003) and Innovation Research Project of Sichuan University (No. 2022SCUH0022).

颞下颌关节强直(temporomandibular joint ankylosis, TMJA)是指由于一侧或双侧颞下颌关节发生病变,造成关节纤维性或骨性粘连,从而导致关节活动度减小、张口受限的疾病^[1]。目前,国内外关于TMJA的分类方法大多是根据强直关节的局部解剖结构特点进行划分,但对成人患者TMJA的术式选择以及继发牙颌面畸形矫治方案缺乏系统的指导意义,因此临床上难以通过这些分类指导医生对成人颞下颌关节进行真正的功能重建,限制了其应用。为探讨标准统一的分类方法,四川大学华西口腔医院正颌及关节外科经过近20年的临床探索,建立了基于关节功能重建的新型成人关节强直分类方法,该方法不仅对强直关节区域的解剖特点进行分类,还依据强直患者继发牙颌面畸形的程度进行细分,从而实现精确指导成人TMJA临床诊疗方案的制定。

1 资料和方法

本研究为回顾性研究,研究已经过四川大学华西口腔医院医学伦理委员会审批(批准号:WCHSIRB-OT-2018-067),所有患者均签署知情同意书。

1.1 研究对象

从2016年1月至2020年4月就诊于四川大学华西口腔医院的成人颞下颌关节强直手术患者中选择病例,纳入标准为:①患者年龄 ≥ 18 岁;②具有术前以及术后7~28 d完整影像学资料(头颅螺旋

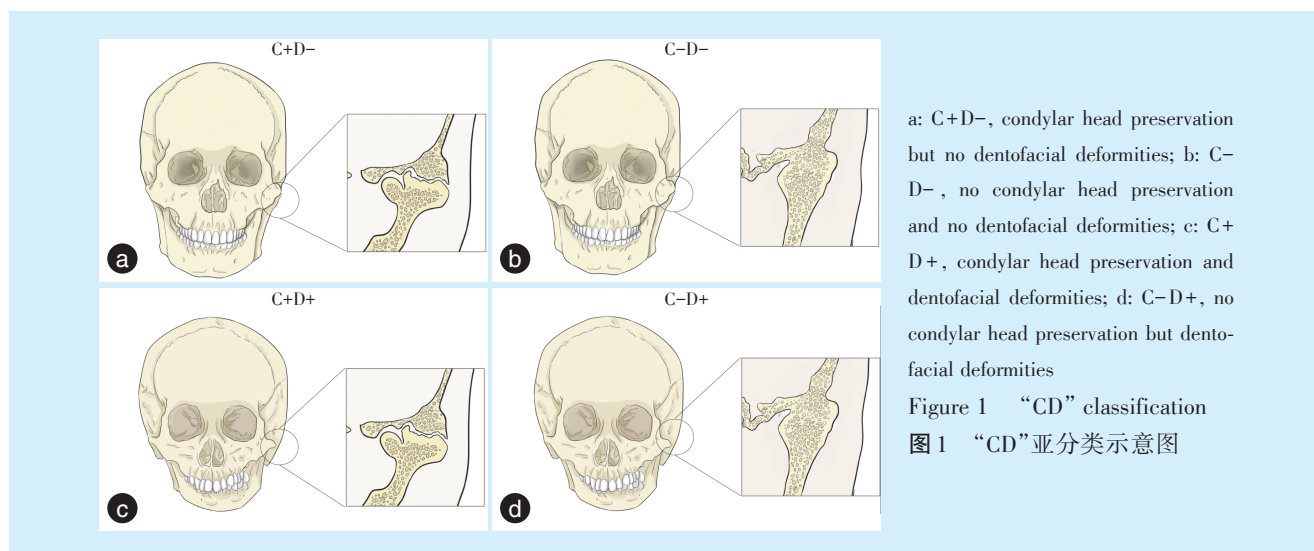
CT重建、全景片),以及至少一次术后12~48个月复查影像学资料(颅螺旋CT重建、全景片);③无影响关节强直预后的全身系统疾病。

1.2 分类原则

本研究在总结临床经验的基础上从两个维度对患者关节强直的类型进行划分:①强直内侧髁突残留情况(condylar head preservation, C):将影像学检查显示关节外侧强直,内侧髁突头部分残余的患者划分为"C+";将关节区域完全骨融合强直,内侧无可保留髁突头残留的患者划分为"C-";对于双侧关节强直患者,其中任意一侧关节有髁突残余,均划分为"C+",若双侧髁突无残余,划分为"C-";②牙颌面畸形情况(dentofacial deformities, D):经面诊、专科检查与头影测量,患者未诊断出明显骨性错颌,划分为"D-";经面诊、专科检查与头影测量,患者被诊断为骨性错颌,划分为"D+"。在以上分类原则下,入组患者根据其临床疾病表现和特点分为4个亚类(图1)。

1.3 治疗方法

在新的分类下,颞下颌关节强直的矫治目标由原有单纯解除关节强直拓展到整个口颌功能区,总体概括为以下2点:①解除强直,保留、重建关节结构和功能;②同期或分期矫治继发牙颌面畸形。不同"CD"分类的治疗方法如下:"C+":采取关节外侧成形术(lateral arthroplasty, LAP),在解除强直的同时保留内侧残留髁突;"C-":强直骨球较小,升支高度丧失不明显,行关节间隙成形解除



强直;强直骨球较大,升支高度降低明显,解除强直后行关节重建。“D+”:同期或分期采用外科手术矫治继发牙颌面畸形。“D-”:术后进行正畸治疗改善咬合关系,口腔疾病对症治疗。

1.4 临床效果评价

关节强直解除术后3~7 d,患者开始坚持张口锻炼,术后1个月、3个月、6个月随访,依据不同亚型的矫治原则持续随访12~48个月。术后关节改建与强直复发情况依据头颅螺旋CT断层和重建片与患者最大张口度(maximal mouth opening, MMO)评估。

1.5 统计学分析

采用Graphpad Prism8统计作图软件进行统计分析,测量数据采用均数标准差表示,采用配对 t 检验统计分析不同治疗策略前后MMO变化,双侧 $P < 0.05$ 为差异有统计学意义。

2 结果

2.1 一般资料与分类

研究共纳入39例单侧关节强直患者,17例双侧关节强直患者,共56例,73侧强直关节。其中男性31例,女性25例,患者年龄19~69岁,平均年龄为 (36 ± 13) 岁。依据“CD”分类法,“C+”:24例,“C-”:32例;“D+”:19例,“D-”:37例。因此,56例患者被分为4个亚分类:19.6%(11例)患者分为“C+D-”亚类;14.3%(8例)患者分为“C-D-”亚类;23.2%(13例)患者分为“C+D+”亚类;42.9%(24例)患者分为“C-D+”亚类。

2.2 治疗效果

56例患者按照不同“CD”亚分类进行治疗策略

制定和实施。术后73侧关节强直均顺利解除,在术后12~48个月随访期间进行口腔专科检查及影像学复查,未见强直复发。患者治疗后远期随访(12~48个月)平均最大张口度较术前显著增加,由 (3.6 ± 3.2) mm增加至 (32.8 ± 5.4) mm ($P < 0.001$)。治疗前后影像学头影测量结果显示37例“D+”亚类患者治疗后颌骨畸形严重程度均得到完全矫正或缓解。

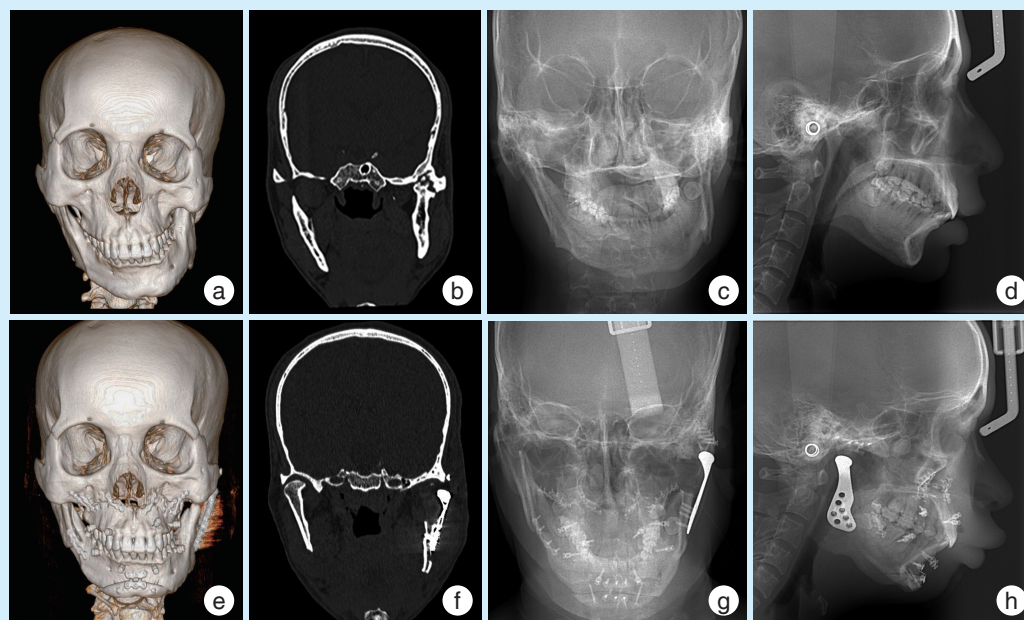
2.3 依据“CD”分类治疗颞下颌关节强直及其继发畸形典型病例

病例1,男,33岁,外伤史30年,诊断为左侧颞下颌关节强直继发颌骨不对称畸形。依据“CD”分类治疗原则分为“C-D+”亚类,对该患者行左侧颞下颌关节成形术解除强直,采用人工关节对左侧强直侧进行关节结构和功能重建,行上颌骨Lefort I型骨切开术旋转摆正上颌骨,行右侧下颌升支矢状劈开术旋转摆正下颌骨,行颏成形术前徙摆正颏部。术后CT与正侧位X片显示患者强直关节结构与功能均得以重建,继发颌骨不对称畸形也得以显著改善(图2)。

病例2,男,53岁,外伤史7年,诊断为双侧颞下颌关节强直,不伴有牙颌畸形。依据“CD”分类治疗原则分为“C+D-”亚类,对该患者行双侧颞下颌关节外侧成形术解除强直,保留内侧残余髁突。术后CT显示患者强直关节结构与功能均得以重建(图3)。

2.4 并发症

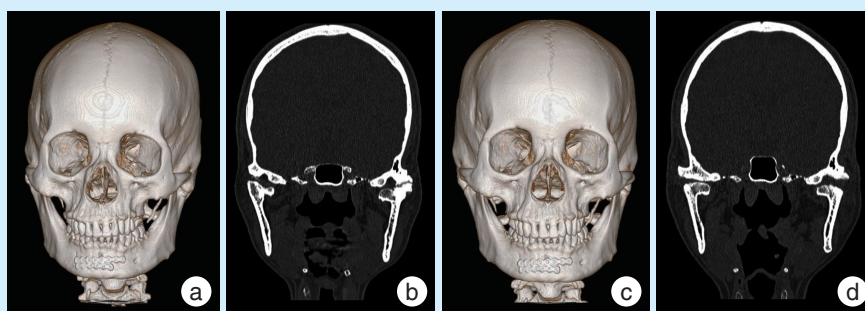
随访期间,6例患者共8侧关节(8/73, 11.0%)出现术后关节区骨擦音;5例患者共6侧关节(6/73, 8.2%)术后即刻出现面神经暂时损伤症状,



a-d: preoperative CT model, coronal slice, lateral and frontal cephalometric radiograph; e-h: postoperative CT model, coronal slice, lateral and frontal cephalometric radiograph. A 33-year-old male patient presented with left TMJA, combined with secondary maxillofacial asymmetry and was classified as "C-D+". Left arthroplasty was performed to release the ankylosis and a joint prosthesis was used to reconstruct the resected condyle. Orthognathic surgery was performed to correct maxillofacial asymmetry. Postoperative imaging showed the ankylosis and deformity were both well corrected

Figure 2 Typical case of "C-D+" temporomandibular joint ankylosis and its secondary deformity

图2 “C-D+”类颞下颌关节强直及其继发畸形典型病例



a & b: preoperative CT model and coronal slice; c & d: postoperative CT model and coronal slice. A 53-year-old male patient who presented with bilateral TMJA and no jaw deformity was classified as "C+D-". Lateral arthroplasty was performed to release the ankylosis. Postoperative CT showed the ankylosis was corrected

Figure 3 Typical cases of "C+D-" bilateral temporomandibular joint ankylosis without dental deformity

图3 “C+D-”类双侧颞下颌关节强直不伴有牙颌畸形典型病例

术后1~3个月神经功能均恢复;2例患者共1侧关节、1侧口内切骨术区出现感染症状(2/73,2.7%),经术区冲洗及抗菌输液治疗后伤口均如期愈合。

3 讨论

成人TMJA的治疗一直是颞下颌关节疾病治疗中的难点,主要是由于成人TMJA常伴发牙颌面畸形,需要综合运用多种术式才能达到理想的颞下颌关节功能重建目标,对临床医师手术方案的制订提出了巨大的挑战。目前国内外已有的颞下

颌关节强直分类方法各有优势,同时也都存在着一定的局限性。

Sawhney等^[2]在1986年对颞下颌关节强直进行解剖学分类,该分类依据强直骨球的大小范围将颞下颌关节强直分为4型。作为最被广泛引用的关节强直分类方式,其主要优点是对手术时强直骨球切除范围有一定的临床指导意义。但是由于当时影像技术的限制,该分类对强直范围分区依据的是二维X线断层片,因此难以客观反映关节强直在冠状位和水平断层的解剖特点。随着影

像学技术的更新和发展,El-Hakim等^[3]提出了基于CT扫描关节重建结果的强直分类,将强直范围和骨球大小的划分由二维拓展到三维,从而使医师能在各个层面更加准确判断强直关节的解剖特点,对医师术前评估手术风险与难度有更好的参考性。Xia等^[4]在以上分类的基础上进行改良,建立了基于CT冠状位骨球不同特征的强直分类,将强直骨球在CT上的影像学特点与其组织病理特点进行关联,并对不同分型的强直手术预后进行了相关性分析。以上分类的优点在于对强直骨球的病变特点描述更为精确,但其局限在于仍然只聚焦于TMJ局部解剖结构改变,缺乏对关节强直完善临床方案制定的有效指导。He等^[5]在强直分类中强调了关节手术解除强直时对骨球内侧残留髁突的保留,该分类充分考虑了残留髁突改建潜能对关节结构与功能重建的影响,在评估患者病情、制定手术计划与后续治疗方案中有更好的指导作用。然而该方法未能涵盖成人关节强直患者继发不同程度颌骨畸形的临床特点与区别。

笔者根据四川大学华西口腔医院正颌及关节外科近20年对颞下颌关节强直患者的治疗经验^[6-9],在国内外上述分类方法的基础上,提出了基于颞下颌关节功能重建的成人关节强直分类法——“CD”分类法。针对“C+”型的患者,为了充分利用强直内侧残余髁状突的改建潜能,对强直侧施以LAP。大量研究表明^[10-12],手术过程仅对外侧强直的骨球进行切除,保留内侧残余的髁突,具有以下优势:①保留的髁突与关节盘,将关节窝与强直去除后的骨创面进行有效间隔,可以一定程度上减小强直复发的几率;②残余髁突的保留可以维持患侧关节结构与下颌升支的原高度,避免异位取骨进行关节再造,显著减少了患者的手术创伤和医疗负担。随着张口锻炼与进食等活动,可最大化发挥残留髁突的生理功能,达到关节功能的良好恢复。对于“C-”分型的患者,如果强直骨球较小,去除骨球后升支高度丧失不明显,可行关节间隙成形术,解除强直,恢复张口^[13]。对于强直骨球较大的患者,去除骨球后常伴随患侧下颌骨升支高度丧失,造成咬合紊乱的加剧,此时则需考虑行颞下颌关节重建术^[14-15]。在以往不同学者报道中,颞下颌关节重建可有多种术式选择,包括:肋骨肋软骨移植^[16]、强直骨球原位移植^[17]、牵张成骨重建关节^[18]以及人工颞下颌关节置换^[19]。对于不同的患者,外科医师应该综合判断,评估最适合的关节

重建方式,评估因素应包括患者关节强直的范围、是否为复发患者以及是否伴发颌骨畸形等。另外,同一例患者往往具有不止一种方案可供选择,这时也应当将患者对开辟第二术区的接受度、对治疗周期的预期以及患者的经济情况等列入考量因素。

对于“D-”分型的成人患者,虽然未表现出严重的牙颌面畸形,但绝大部分患者往往因为长期张口受限而伴随咬合紊乱以及牙体、牙周等疾病。对于此分型的患者,在解除强直以后,需嘱患者术后进行正畸治疗改善咬合关系,同时对牙体、牙周疾病进行对症治疗,帮助患者在恢复张闭口的基础上获得良好的口颌功能,进而做到真正的“关节功能重建”。对于“D+”分型的患者,可在关节重建时同期或分期行正颌手术矫治继发畸形:①对于单侧关节强直患者,上颌骨常出现患侧发育不足,殆平面偏斜,而对于双侧关节强直患者则常出现双侧上颌骨后份发育不足。采用Le Fort I型骨切开术(Le Fort I osteotomy)可摆正上颌殆平面或下降上颌骨后份,从而改善上颌畸形。上颌骨下降或摆正后的间隙需进行植骨,增加术后上颌骨的稳定性;②强直患者常出现患侧下颌骨发育障碍,表现为下颌骨体部或/和下颌升支发育不足。对于下颌体部发育不足的患者,下颌升支矢状劈开术(sagittal split ramus osteotomy, SSRO)是最常用的手术方式之一。而对于下颌升支高度不足的患者,可采用下颌骨垂直骨切开(vertical ramus osteotomy)上移下颌骨后份,从而在恢复升支高度的同时重建关节。对于升支高度与下颌体部长度严重不足的患者,也可采用下颌骨倒“L”骨切开与间隙植骨结合的方式,做到同时延长患侧下颌升支高度与下颌体长度^[20];③对于强直伴发颞部后缩的患者,可同期行颞成形术大幅前徙颞部骨块,进一步改善强直患者的后缩面型与气道狭窄。

“CD”分类法将以往分类涵盖的疾病区域由关节局部拓展到整个口颌功能区,便于系统理解和记忆。临床医师依据此分类综合考虑患者强直区域特点与牙颌面畸形情况,可快速制定强直治疗方案,简化了整体诊疗流程,使关节强直临床诊疗更加规范化。然而,“CD”分类法仍存在一定局限性,目前仅限于指导成人强直患者的临床诊疗,儿童患者由于仍处于生长发育期,治疗方案更为复杂,该分类尚不足以应用于儿童患者。希望未来“CD”分类法经过不断地改进和完善,能够得到更

多临床医师的应用,在颞下颌关节强直关节功能重建过程中发挥重要作用。

【Author contributions】 Wang RY collected, measured, analyzed the data and wrote the article. Jiang N, Cao PY, Liu Y, Zhu SS, Bi RY revised the article. All authors read and approved the final manuscript as submitted.

参考文献

- [1] Mishra N, Sharma NK, Dhiman NK, et al. Temporomandibular joint ankylosis: a tertiary center-based epidemiological study[J]. *Natl J Maxillofac Surg*, 2021, 12(3): 392-396. doi: 10.4103/njms.NJMS_57_20.
- [2] Sawhney CP. Bony ankylosis of the temporomandibular joint: follow-up of 70 patients treated with arthroplasty and acrylic spacer interposition[J]. *Plast Reconstr Surg*, 1986, 77(1): 29-40.
- [3] El-Hakim IE, Metwalli SA. Imaging of temporomandibular joint ankylosis. A new radiographic classification[J]. *Dentomaxillofac Radiol*, 2002, 31(1): 19-23. doi: 10.1038/sj/dmfr/4600660.
- [4] Xia L, An J, He Y, et al. Association between the clinical features of and types of temporomandibular joint ankylosis based on a modified classification system[J]. *Sci Rep*, 2019, 9(1): 10493. doi: 10.1038/s41598-019-46519-8.
- [5] He D, Yang C, Chen M, et al. Traumatic temporomandibular joint ankylosis: our classification and treatment experience[J]. *J Oral Maxillofac Surg*, 2011, 69(6): 1600 - 1607. doi: 10.1016/j.joms.2010.07.070.
- [6] 祝颂松, 胡静. 牵张成骨在颞下颌关节强直及其继发畸形矫治中的应用[J]. *口腔疾病防治*, 2016, 24(1): 6-10. doi: 10.12016/j.issn.2096-1456.2016.01.001.
Zhu SS, Hu J. The application of distraction osteogenesis in the temporomandibular joint ankylosis and secondary dentofacial deformities[J]. *J Prev Treat Stomatol Dis*, 2016, 24(1): 6 - 10. doi: 10.12016/j.issn.2096-1456.2016.01.001.
- [7] Ma Y, Huang Y, Zhu S, et al. Simultaneous arthroplasty and distraction osteogenesis for the treatment of ankylosis of the temporomandibular joint and secondary mandibular deformities in children [J]. *Br J Oral Maxillofac Surg*, 2019, 57(2): 135-139. doi: 10.1016/j.bjoms.2018.11.016.
- [8] Jiang Y, Huang Y, Ye B, et al. Management of temporomandibular joint ankylosis with dentofacial deformities in children[J]. *J Craniofac Surg*, 2018, 29(2): e150-e155. doi: 10.1097/SCS.00000000000004253.
- [9] Yang YT, Yf L, Jiang N, et al. Grafts of autogenous coronoid process to reconstruct the mandibular condyle in children with unilateral ankylosis of the temporomandibular joint: long-term effects on mandibular growth[J]. *Br J Oral Maxillofac Surg*, 2018, 56(2): 107-112. doi: 10.1016/j.bjoms.2017.12.001.
- [10] Lin X, Li HY, Xie QT, et al. Surgical treatment of type III temporomandibular joint ankylosis with a lateral arthroplasty while retaining the medially displaced condyle[J]. *Ann R Coll Surg Engl*, 2019, 101(6): 415-421. doi: 10.1308/rcsann.2019.0041.
- [11] Sadakah AA, Essa EF, Elshall MA. Lateral arthroplasty as an optimal treatment for surgical management of unilateral temporomandibular joint ankylosis type III in children[J]. 2018, 64: 129-138. doi: 10.21608/edj.2017.77065.
- [12] Xia L, He Y, An J, et al. Condyle-preserved arthroplasty versus costochondral grafting in paediatric temporomandibular joint ankylosis: a retrospective investigation[J]. *Int J Oral Maxillofac Surg*, 2019, 48(4): 526-533. doi: 10.1016/j.ijom.2018.07.018.
- [13] Zhu F, Zhi Y, Xu X, et al. Interpositional arthroplasty of post-traumatic temporomandibular joint ankylosis: a modified method[J]. *J Craniomaxillofac Surg*, 2021, 49(5): 373 - 380. doi: 10.1016/j.jcms.2021.01.032.
- [14] Lakshmanan S, Roychoudhury A, Bhutia O, et al. Can costochondral grafts fulfil ramus-condyle unit reconstruction goals in children with temporomandibular joint ankylosis?[J]. *Br J Oral Maxillofac Surg*, 2021, 59(2): 184-190. doi: 10.1016/j.bjoms.2020.08.021.
- [15] Awal DH, Jaffer M, Charan G, et al. Costochondral grafting for paediatric temporomandibular joint reconstruction: 10-year outcomes in 55 cases[J]. *Int J Oral Maxillofac Surg*, 2018, 47(11): 1433-1438. doi: 10.1016/j.ijom.2018.06.004.
- [16] 阚召俊, 苏成利, 李运峰. 自体喙突移植重建髁突对儿童颞下颌关节强直患者下颌骨生长的远期影响[J]. *华西口腔医学杂志*, 2020, 38(1): 23-29. doi: 10.7518/hxkq.2020.01.005.
Kan ZJ, Su CL, Li YF. Long-term effects of autogenous coronoid grafts on the facial growth of children with unilateral temporomandibular joint ankylosis and reconstructed mandibular condyle[J]. *West Chin J Stomatol*, 2020, 38(1): 23 - 29. doi: 10.7518/hxkq.2020.01.005.
- [17] Bansal V, Mowar A, Dubey P, et al. Coronoid process and residual ankylotic mass as an autograft in the management of ankylosis of the temporomandibular joint in young adolescent patients: a retrospective clinical investigation[J]. *Br J Oral Maxillofac Surg*, 2016, 54(3): 280-285. doi: 10.1016/j.bjoms.2016.01.012.
- [18] Singh AK, Jose A, Khanal N, et al. Transport distraction osteogenesis compared with autogenous grafts for ramus-condyle unit reconstruction in temporomandibular joint ankylosis: a systematic review and meta-analysis[J]. *Br J Oral Maxillofac Surg*, 2021: S0266-4356(21)00483. doi: 10.1016/j.bjoms.2021.12.051.
- [19] Yadav P, Roychoudhury A, Kumar RD, et al. Total alloplastic temporomandibular joint replacement[J]. *J Maxillofac Oral Surg*, 2021, 20(4): 515-526. doi: 10.1007/s12663-021-01628-8.
- [20] Boss H, Park J H, Carlotti A, et al. Mandibular micrognathia and vertical maxillary excess correction with combination LeFort I and inverted L osteotomies [J]. *Am J Orthod Dentofacial Orthop*, 2020, 157(5): 704-718. doi: 10.1016/j.ajodo.2019.02.021.

(编辑 周春华, 张晟)



官网