

[DOI]10.12016/j.issn.2096-1456.2023.03.003

· 基础研究 ·

富血小板纤维蛋白联合MTA用于兔牙直接盖髓术的组织学研究

杨雪¹, 颜志豪¹, 刘锦², 胡玉萍², 黎淑芳²

1. 柳州市人民医院, 广西壮族自治区 柳州(545006); 2. 右江民族医学院, 广西壮族自治区 百色(533000)

【摘要】 目的 探讨富血小板纤维蛋白(platelet-rich fibrin, PRF)联合三氧化矿物凝聚体(mineral trioxide aggregate, MTA)作为直接盖髓剂的可行性和疗效。方法 将32只新西兰兔随机分为4组,即PRF+MTA组(P+M组)、PRF组(P组)、MTA组(M组)、空白对照组(BC组),每组8只,对每只实验兔的2颗下颌中切牙进行开髓,分别用上述材料进行直接盖髓术,完成冠方封闭。分别在术后7 d、28 d从每组中随机选择4只实验兔并处死,实验牙进行HE染色,分析评价炎症细胞浸润程度、钙化桥形成程度及牙髓组织变性程度。结果 炎症细胞浸润程度:术后7 d和术后28 d, P+M组、M组均较BC组炎症细胞浸润程度轻,差异具有统计学意义($P < 0.05$);术后28 d, P+M组较P组轻($P < 0.05$);P+M组与M组比较差异无统计学意义($P > 0.05$)。钙化桥形成程度:术后7 d和术后28 d, P+M组钙化桥形成程度较P组、M组、BC组高,差异具有统计学意义($P < 0.05$);术后28 d, M组较BC组钙化桥形成程度高,差异具有统计学意义($P < 0.05$);显微镜下观察,钙化桥内部含细胞成分,未出现牙本质小管样结构,周围牙本质样细胞包绕,其结构似骨样牙本质。牙髓组织变性程度:术后7 d, P+M组、M组均较BC组牙髓变性程度轻,差异具有统计学意义($P < 0.05$);术后28 d, P+M组较P组、BC组轻($P < 0.05$);P+M组与M组比较差异无统计学意义($P > 0.05$)。结论 PRF+MTA作为盖髓剂用于直接盖髓术时,牙髓炎症反应程度较轻,牙髓状态较稳定且具有较强的钙化桥形成能力,钙化桥结构似骨样牙本质。

【关键词】 富血小板纤维蛋白; 三氧化矿物凝聚体; 直接盖髓术; 盖髓剂; 炎症反应; 钙化桥; 牙髓变性; 兔下颌中切牙; 组织学分级

【中图分类号】 R78 **【文献标志码】** A **【文章编号】** 2096-1456(2023)03-0171-08

【引用著录格式】 杨雪, 颜志豪, 刘锦, 等. 富血小板纤维蛋白联合MTA用于兔牙直接盖髓术的组织学研究[J]. 口腔疾病防治, 2023, 31(3): 171-178. doi:10.12016/j.issn.2096-1456.2023.03.003.

Histological study of platelet-rich fibrin combined with MTA for direct pulp capping of rabbit teeth YANG Xue¹, YAN Zhihao¹, LIU Jin², HU Yuping², LI Shufang². 1. Liuzhou People's Hospital, Liuzhou 545006, China; 2. Youjiang Medical University for Nationalities, Baise 533000, China

Corresponding author: LI Shufang, Email:303121175@qq.com, Tel: 86-13977686710

【Abstract】 Objective To investigate the outcomes of a novel direct pulp capping agent containing platelet-rich fibrin (PRF) and mineral trioxide aggregate (MTA). **Methods** A total of 32 New Zealand rabbits were randomly divided into 4 groups, namely, the PRF+MTA group (P+M group), PRF group (P group), MTA group (M group) and blank control group (BC group), with 8 rabbits per group. Dental pulp exposure and direct pulp capping were performed, and complete crown square sealing was performed on 2 mandibular central incisor teeth of each rabbit. Four rabbits from each group were euthanized after each observation period (7 and 28 days). The experimental teeth were subjected to HE staining. Inflammatory cell infiltration, calcified bridge formation and pulp tissue disorganization were observed and graded. **Results** Inflammatory cell infiltration: on the 7th day, group P+M and group M were lighter than group BC ($P < 0.05$);

【收稿日期】 2022-05-23; **【修回日期】** 2022-07-12

【基金项目】 广西壮族自治区自然科学基金项目(2020JJA140030); 广西壮族自治区研究生教育创新计划项目(YCSW2018217); 百色市科学研究与技术开发计划项目(20171113)

【作者简介】 杨雪, 医师, 硕士研究生, Email: 3440204864@qq.com

【通信作者】 黎淑芳, 主任医师, 硕士, Email: 303121175@qq.com, Tel: 86-13977686710



微信公众号

on the 28th day, group P+M was lighter than group P and group BC ($P < 0.05$); group P+M and group M did not significantly differ ($P > 0.05$). Calcified bridge formation: on the 7th and 28th days, group P+M was lighter than group P, group M and group BC ($P < 0.05$); on the 28th day, group M was higher than group BC ($P < 0.05$). Under microscope, the calcified bridge contained cellular components and was surrounded by odontoblast-like cells, sharing a structure resembled osteodentin; dentin tubule-like structure could not be observed in calcified bridge, and the calcified bridge resembled certain points of osteodentin. Pulp tissue disorganization: on the 7th day, group P+M and group M were lighter than group BC ($P < 0.05$); on the 28th day, group P+M was lighter than group P and group BC ($P < 0.05$). group P+M and group M did not significantly differ ($P > 0.05$). **Conclusion** The combination of PRF and MTA for direct pulp capping provided light inflammatory cell infiltration, stable pulp status and a strong ability of pulp tissue to form calcified bridge, and the calcified bridge resembled certain points of osteodentin.

【Key words】 platelet-rich fibrin; mineral trioxide aggregate; direct pulp capping; capping agent; inflammatory response; calcified bridge formation; pulp tissue disorganization; mandibular central incisor teeth of rabbit; histological grade

J Prev Treat Stomatol Dis, 2023, 31(3): 171-178.

【Competing interests】 The authors declare no competing interests.

This study was supported by the grants from Natural Science Foundation of Guangxi Zhuang Autonomous Region (No.2020JJA140030); Innovation Project of Guangxi Zhuang Autonomous Region Graduate Education (No.YC-SW2018217); Science and Technology Project of Baise City (No.20171113).

直接盖髓术的目的是利用盖髓材料物理性封闭露髓点,直接与牙髓组织接触的盖髓材料同时起到消除牙髓感染和炎症的作用,保持牙髓内稳态,同时诱导露髓处钙化桥形成,最终形成钙化屏障以达到生物性封闭露髓孔的作用。富血小板纤维蛋白(platelet-rich fibrin, PRF)作为第二代血小板凝聚物,具有抑制牙髓炎症反应,刺激成牙本质细胞分化的作用^[1]。而相较于单独使用PRF或三氧化矿物凝聚体(mineral trioxide aggregate, MTA)来培养人牙髓细胞,PRF与MTA联合培养的细胞具备更高的形成牙本质的能力^[2]。课题组前期研究发现,应用锥形束CT从影像学角度观察PRF联合MTA促进矿化组织形成的水平与MTA无差异,都处于较高水平^[3],但牙髓组织状态、生成的钙化桥结构仍需进一步深入研究。本研究拟从组织学角度,观察炎症细胞浸润程度、钙化桥形成程度及牙髓组织变性程度,比较各组实验牙的牙髓损伤修复效果。

1 材料和方法

1.1 主要材料

低速冷冻离心机(miVac DUO, Genevac, 英国); 硬组织切片机(RM2016, Leica, 德国); MTA(登士柏, 德国); 常规手术器械。3%戊巴比妥钠溶液(迈瑞达, 中国); 玻璃离子水门汀(而至, 日本); 14% EDTA溶液(贝康, 中国)。

1.2 实验方法

1.2.1 实验动物及分组 2019年4月22日于实验动物中心购买32只健康雄性新西兰兔(动物合格证号:000103292),体重2.5~3.0 kg,兔龄5个月,随机分为4组,即PRF+MTA组(P+M组)、PRF组(P组)、MTA组(M组)、空白对照组(BC组),每组8只,同一只兔的2颗下颌中切牙纳入同一实验组,整个实验由两组操作人员完成,即PRF膜制备组、直接盖髓术操作组。已通过实验动物伦理委员会的审查(审批号:20190215016)。

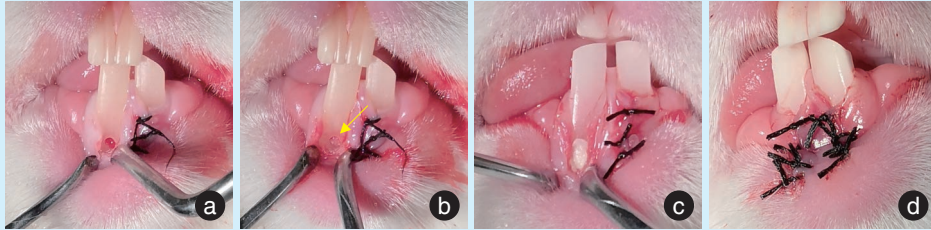
1.2.2 PRF膜的制备 为排除麻醉药物对PRF制备的影响,在麻醉前进行采血,采血完毕后立即进行动物麻醉,麻醉药物为3%戊巴比妥钠溶液,剂量为30 mg/kg。自兔耳缘静脉采血,采血量为4~5 mL,在3 000 r/min下离心10 min,静置5 min,用无菌镊钳取凝胶状复合物,剪掉下层红细胞,剩余中间凝聚物为凝胶状PRF,将凝胶状PRF置于2个无菌板间轻压,制成厚度约为0.5 mm的PRF膜。此过程由PRF膜制备组操作人员完成。

1.2.3 直接盖髓术操作过程 碘伏消毒牙龈,切开下颌中切牙颊侧牙龈,翻瓣,去除颊侧部分骨壁,充分暴露下颌中切牙,用006号球钻在下颌中切牙唇面备洞至洞底透红但无渗血时,用自制直径为0.5 mm的探针轻轻加压穿髓,生理盐水冲洗,10% NaClO溶液棉球止血3~5 min(图1a)。

根据不同分组放置相应的盖髓剂,P+M组:将

合适大小的PRF膜覆盖于暴露牙髓组织表面,再在PRF膜表面及周围大部分牙本质覆盖一层MTA。P组:PRF膜覆盖于暴露牙髓组织表面。M组:MTA覆盖于暴露牙髓组织及周围大部分的牙

本质。BC组:穿髓孔处不放盖髓剂。放置盖髓剂后,所有样本均用玻璃离子水门汀严密充填窝洞,严密缝合牙龈(图1b~1d)。此过程由直接盖髓术组操作人员完成。



a: the gingiva was disinfected with iodophor; the buccal gingiva of the mandibular central incisor was incised, the flap was turned over, and part of the buccal alveolar bone wall was removed; exposure hole was prepared; b: direct pulp capping agents were placed above the perforation hole (yellow arrow); c: after placing the pulp capping agents, all samples were tightly filled with glass ionomer cement; d: gingival flap was sutured tightly

Figure 1 Direct capping procedure of mandibular central incisors in rabbit

图1 兔下颌中切牙直接盖髓术操作过程

1.3 样本 HE 染色及观察

1.3.1 取材及染色 术后7 d、术后28 d从每个实验组中随机选择4只实验兔并处死,立即用福尔马林溶液对下颌骨进行固定,48 h后弃固定液,分离实验牙,用14%EDTA溶液对实验牙进行脱钙2个月。纵向包埋,切片,厚度为4 μm,选择经过穿髓孔中心的切片进行HE染色,光镜下进行读片,综合参考El-Din、Soliman等^[4-5]的评价标准进行分级。读片由1名牙体牙髓病专科医师、1名病理科医师完成,如遇意见不统一的情况,另外请1名病理科医师给予评价,最终确认分级。

1.3.2 直接盖髓术的组织学疗效评价指标 ①炎症细胞浸润,即穿髓孔周围炎症细胞浸润程度,分为3等级,1为轻度炎症(无或炎症细胞散在分布),2为中度炎症(密集或带状炎症细胞浸润),3为重度炎症(大量炎症浸润,局灶性或大面积组织坏死)。②钙化桥形成程度,即钙化屏障覆盖范围,分为3等级,1为覆盖大部分牙髓暴露面(≥50%露髓区域);2为覆盖小部分牙髓暴露面(<50%露髓区域);3为没有钙化桥形成。③牙髓变性程度,包括牙髓结构及细胞形态,分为3等级,1为牙髓组织结构、细胞形态正常或基本正常;2为成牙本质细胞层破坏,但深部牙髓组织结构基本正常;3为牙髓失去正常组织结构,出现坏死灶。

1.4 统计学分析

采用SPSS 20.0软件进行数据分析,多样本比

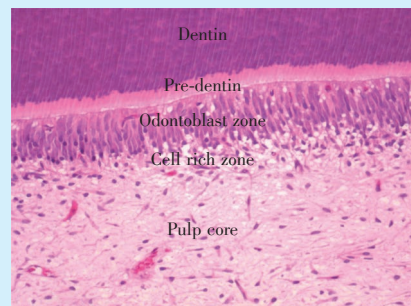
较选择Kruskal-wallis单因素ANOVA分析法,同时进行多重比较。 $P < 0.05$ 为差异有统计学意义。

2 结果

7 d时,P+M组有1颗实验牙暂封物脱落,排除1颗实验牙。28 d时,P组有1只实验兔死亡,排除2颗实验牙。最终实验样本数为61。

兔下颌中切牙正常牙髓的基本组织学的表现(图2):可见明显的成牙本质细胞层、多细胞层及髓核结构,但未见乏细胞层。

2.1 各组实验牙 HE 染色结果



The odontoblast zone, cell-rich zone and pulp core were observed, but a Weil zone was absent

Figure 2 Basic histologic image of the normal pulp of the mandibular central incisors in rabbits (HE ×100)

图2 兔下颌中切牙正常牙髓的基本组织学的表现 (HE×100)

2.1.1 P+M组 术后7 d,穿髓孔处出现少量炎症细胞,穿髓孔稍下方见钙化桥形成,钙化桥与刺激性牙本质几乎完全相连,几乎覆盖整个穿髓孔;牙髓组织结构、细胞形态基本正常,髓腔内见炎症细胞散在分布,血管稍充血。术后28 d,穿髓孔处坏死崩解物形成,稍下方见钙化桥与刺激性牙本质完全相连,钙化桥形成覆盖整个穿髓孔;牙髓组织结构、细胞形态基本正常,髓腔内见大量钙化组织形成(图3a1、3a2)。

2.1.2 P组 术后7 d,穿髓孔处较多炎症细胞浸润,稍下方见不规则钙化桥形成,覆盖小部分穿髓孔;牙髓失去正常组织结构,出现坏死灶,大量血管扩张,髓腔内见少量钙化组织。术后28 d,穿髓孔处见部分坏死组织、牙本质碎屑,稍向下方见较多炎症细胞浸润,几乎未见钙化桥封闭穿髓孔;但髓腔内见大量不规则钙化组织形成,牙髓组织结构不清(图3b1、3b2)。

2.1.3 M组 术后7 d,穿髓孔处出现少量炎症细胞,钙化桥覆盖小部分穿髓孔;牙髓结构紊乱,髓腔内见大量钙化组织形成。术后28 d,穿髓孔处见部分坏死组织,稍下方见钙化桥形成,覆盖大部分穿髓孔区域;牙髓组织结构、细胞形态基本正常(图3c1、3c2)。

2.1.4 BC组 术后7 d,穿髓孔处及髓腔内大量炎症细胞聚集分布,穿髓孔处无钙化桥形成,深部牙髓见大量钙化组织填满髓腔,细胞成分减少,血管充血明显。术后28 d,穿髓孔周围及髓腔内见大量无定形结构的坏死组织(图3d1、3d2)。

本研究各组实验牙形成的钙化桥具有相似的组织学特征,在其中选取清晰且视野较好的2张图片以比较骨小梁、骨样牙本质、钙化桥的结构,图4a来源于术后7 d的BC组,图4b来源于术后7 d的P+M组。骨样牙本质具有骨小梁的特征,即骨小梁内部包埋着为卵圆形骨细胞(图4a)。本实验中,实验牙髓腔可见修复性牙本质形成,因形成的修复性牙本质内部含细胞,髓腔侧为成牙本质样细胞层,也可称为骨样牙本质(图4b);本研究中各组实验牙形成的钙化桥内部含细胞成分,周围牙本质样细胞包绕,其结构似骨样牙本质(图4b)。

2.2 各组牙髓组织学分级情况及统计学分析结果

对各组实验牙牙髓组织学分级情况进行统计学分析,术后7 d、术后28 d各组间的差异均具有统计学意义($P < 0.05$)(表1),组间多重比较结果如下。

2.2.1 炎症细胞浸润程度 术后7 d和28 d,P+M组、M组均较BC组炎症细胞浸润程度轻,差异具有统计学意义($P < 0.05$);P+M组与M组炎症细胞浸润程度差异无统计学意义($P > 0.05$);术后28 d,P+M组较P组炎症细胞浸润程度轻,差异有统计学意义($P < 0.05$)(图5a)。


2.2.2 钙化桥形成程度 术后7 d和28 d,P+M组钙化桥形成程度较P组、M组、BC组高,差异有统计学意义($P < 0.05$);术后28 d,M组钙化桥形成程度较BC组高,差异具有统计学意义($P < 0.05$);P组与M组间钙化桥形成程度差异无统计学意义($P > 0.05$)(图5b)。

2.2.3 牙髓变性程度 术后7 d,P+M组、M组均较BC组牙髓变性程度轻,差异具有统计学意义($P < 0.05$);术后28 d,P+M组较P组、BC组牙髓变性程度轻,差异具有统计学意义($P < 0.05$);P+M组与M组间牙髓变性程度差异无统计学意义($P > 0.05$);P组与M组间牙髓变性程度差异无统计学意义($P > 0.05$)(图5c)。

3 讨论

3.1 直接盖髓术的疗效分析

PRF由自体血制成,以自身结构为支架,能够释放多种直接参与细胞生长、增殖、调节炎症活动和血管生成过程的生长因子,自身可降解从而被新生的组织替代^[6],已逐渐被应用于牙髓再生^[7]、活髓保存^[8]和根尖手术^[9]等牙体牙髓临床治疗措施中。Dou等^[10]通过体外细胞学实验研究发现PRF具有良好的生物相容性、低细胞毒性和促进人牙髓细胞增殖和分化功能,同时能提高碱性磷酸酶活性,促进矿化,具备直接盖髓材料的优良特性。但因PRF膜湿润、易溶解吸收^[11]的理化性质,PRF作为直接盖髓材料并未广泛应用于临床,国内外的相关研究主要集中在PRF诱导牙髓细胞/牙髓干细胞向成牙本质细胞分化的能力和机制研究^[12-14],PRF用于直接盖髓术的动物实验研究却较为少见。有动物实验研究发现PRF用于直接盖髓术时,几乎无修复性牙本质形成,且髓腔内呈现程度较重的炎症反应^[15]。本研究中,P组开髓孔稍下方可见少量钙化桥形成,炎症细胞浸润程度较BC组轻,但较M组和P+M组重。分析其原因,PRF膜的降解时间最短为4 d,最长为8 d^[16],其降解的同时自身释放抗炎因子转化生长因子- $\beta 1$ (transforming growth factor- $\beta 1$,TGF- $\beta 1$),当PRF膜降解后,具



On the 7th day, in group P+M (a1): inflammatory cells around the exposure were almost entirely absent, CB formed just below the perforation and almost covered the entire pulpal exposure; the structure and morphology of the pulp were normal, and scattered inflammatory cells and congested blood vessels appeared in the pulp chamber. In group P (b1): dense inflammatory cells infiltrated around the exposure, which was defined as moderate inflammation; CB formed below the perforation and covered only a small part of pulpal exposure; the pulp lost its normal tissue structure, and necrosis appeared with a large number of blood vessels and calcified masses in the deep part of the pulp. In group M (c1): a few scattered inflammatory cells appeared around the exposure; CB covered a small portion of the exposed surface; the pulp structure was disorganized, and a large amount of calcified masses were found in the pulp. In group BC (d1): severe inflammatory infiltration appeared around the exposure, no CB formed, the pulp structure was disorganized, and a large number of calcifications filled the deep part of pulp, with decreased cell composition and marked vascular congestion (as shown in the black box)

On the 28th day, in group P+M (a2): necrosis was evident around the exposure, slightly below, CB connected to the ID and completely covered the entire pulpal exposure; the structure and morphology of the pulp were normal, and a large number of calcified masses were observed in the deep part of the pulp. In group P (b2): some necrotic tissue, dentin fragments and dense inflammatory cells were observed around the exposure, which was defined as severe inflammation; no CB formed below perforation; the pulp lost its normal tissue structure, and a large number of calcified masses were observed in the deep part of the pulp. In group M (c2): some necrosis was observed at the perforation of the pulp, and CB was formed below, covering most of the perforation area; the structure and morphology of the pulp were normal. In group BC (d2): a large amount of amorphous necrotic tissue was observed around the perforation and pulp cavity. Asterisk: perforation; CB: calcified bridge; ID: irritation dentin. group P+M: PRF+MTA. group P: PRF. group M: MTA. group BC: blank control. PRF: platelet-rich fibrin. MTA: mineral trioxide aggregate

Figure 3 Histological images of pulp in each group 7 days and 28 days after direct pulp capping of rabbit teeth

图3 兔牙直接盖髓术后7 d、28 d各组牙髓组织学表现

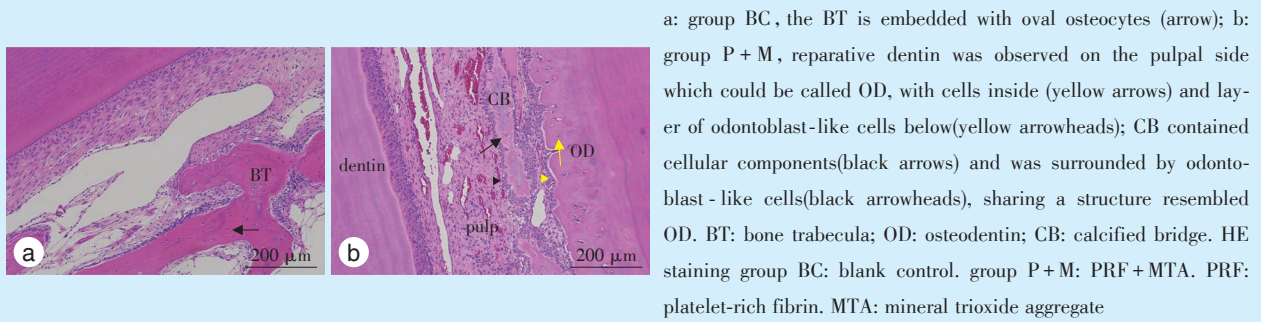


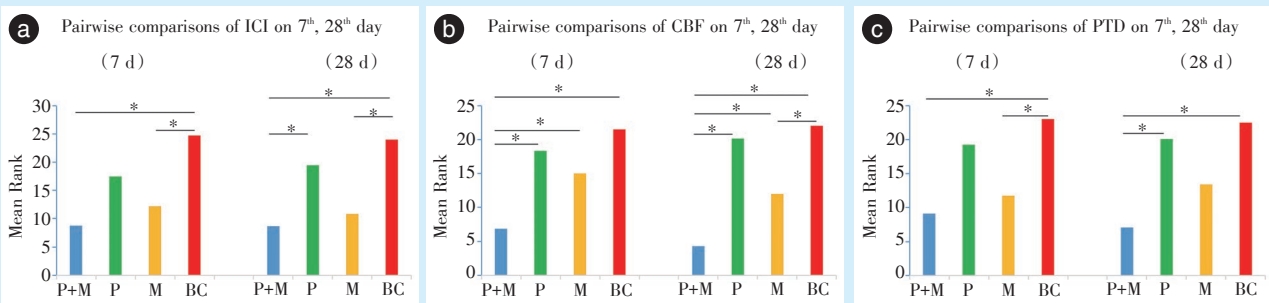
Figure 4 Histological features of bone trabecula, osteodentin and calcified bridge 7 days after direct pulp capping of rabbit teeth
图4 兔牙直接盖髓术后7d骨小梁、骨样牙本质及钙化桥组织学表现

表1 各组牙髓组织学分级情况及统计结果

Table 1 Overview and statistical results of histological grading of dental pulp in each group

Groups		P+M (n = 15)		P (n = 14)		M (n = 16)		BC (n = 16)		P	
Evaluations		7 d	28 d	7 d	28 d	7 d	28 d	7 d	28 d	7 d	28 d
ICI	1	6	7	2	1	5	6	0	0	0.001*	< 0.001*
	2	1	1	4	1	2	1	2	1		
	3	0	0	2	4	1	1	6	7		
CBF	1	5	7	0	0	1	1	0	0	0.002*	< 0.001*
	2	1	1	2	1	2	2	0	0		
	3	1	0	6	5	5	5	8	8		
PTD	1	1	1	0	0	0	0	0	0	0.002*	< 0.001*
	2	5	7	2	1	6	5	0	0		
	3	1	0	6	5	2	3	8	8		

ICI: inflammatory cell infiltration; CBF: calcified bridge formation; PTD: pulp tissue disorganization; test analysis: Kruskal-wallis 1-way ANOVA. * represented $P < 0.05$. Group P+M: PRF+MTA. Group P: PRF. Group M: MTA. Group BC: blank control. PRF: platelet-rich fibrin. MTA: mineral trioxide aggregate



a: the pairwise comparisons of ICI; b: the pairwise comparisons of CBF; c: the pairwise comparisons of PTD. ICI: inflammatory cell infiltration. CBF: calcified bridge formation. PTD: pulp tissue disorganization. *: $P < 0.05$. Group P+M: PRF+MTA. Group P: PRF. Group M: MTA. Group BC: blank control. PRF: platelet-rich fibrin. MTA: mineral trioxide aggregate

Figure 5 Pairwise comparisons of histological grading of dental pulp between groups

图5 各组牙髓组织分级组间两两比较

有一定细胞毒性的玻璃离子水门汀^[17]直接与牙髓组织接触,但抗炎因子的作用与玻璃离子水门汀产生的细胞毒性起到一定中和作用,从而使得P组的炎症细胞浸润程度较BC组低;PRF单独应用时,

边缘封闭性较差,因此炎症细胞浸润程度比M组和P+M组更重。

MTA是一种具有高密封性能、优良抗菌性能和良好生物相容性的生物活性材料,研究表明,与

氢氧化钙相比,MTA用于直接盖髓后形成的牙本质桥质量更高,即孔隙少,钙化桥厚,且牙髓炎症较轻^[18-20]。MTA已应用于龋源性露髓成熟恒牙的直接盖髓术,实现恒牙的活髓保存,取得较好临床效果^[21-22]。本研究中,对比P+M组与M组,发现P+M组炎症反应与M组相当,但形成钙化桥的程度较MTA组高,说明PRF联合MTA作为盖髓剂应用于直接盖髓术具有较高可行性。

3.2 钙化桥组织学结构特征

当修复性牙本质以较快速度形成时,成牙本质细胞常还未移行至髓腔侧就被自身分泌的牙本质基质包裹,进而被包埋在间质中,以后这些细胞变性,在该处遗留一空,很像骨组织,具备这样结构的修复性牙本质称之为骨样牙本质^[23]。本研究实验牙穿髓孔下方形成的钙化桥的结构类似于骨样牙本质,具有类似于牙本质和骨小梁的组织学特征,钙化桥内部未出现牙本质小管样结构。本课题组发现,在构建直接盖髓术实验模型时,对牙髓组织形成一定刺激,导致实验牙深部牙髓形成大量修复性牙本质,内部多含有细胞,髓腔侧为成牙本质细胞层,组织学表现为骨样牙本质,但此修复性牙本质同样未见明显牙本质小管。而Tran等^[24]发现将硅酸钙材料用于大鼠磨牙直接盖髓术时,穿髓孔处可形成结构类似于初期牙本质的修复性牙本质,可见排列紊乱的牙本质小管。这可能是由于实验动物不同造成的,兔属于啮齿动物,牙齿生长速度快,因此本研究观察到兔正常牙髓组织中未见明显乏细胞层,在外界刺激下,缺乏细胞突起的成牙本质样细胞被包埋在快速形成的间质中,最终在深部牙髓中的原发性牙本质的髓腔侧形成缺乏小管样结构的骨样牙本质,在穿髓孔下方形成了类似骨样牙本质的钙化桥。但也有研究发现,骨样牙本质或纤维样牙本质的形成先于管状牙本质的形成,当成牙本质样细胞层形成后,管状牙本质相继形成,这一序列与实验模型的物种、年龄和干预措施无关^[25]。

3.3 直接盖髓术后牙髓损伤修复过程

本实验中,盖髓剂下方以钙化灶不断融合形成钙化桥的方式封闭穿髓孔,这与Suzuki等^[26]的研究有所差别,其研究发现低粘度粘结剂用于大鼠直接盖髓术时,盖髓剂下方以层层包裹式形成的牙本质桥封闭穿髓孔。光镜下观察发现,术后7d,散在钙化灶并非出现在穿髓孔处,而是在穿髓孔稍下方生成,弥散的钙化灶逐渐融合形成钙化

桥。备洞及穿髓、盖髓剂的覆盖都对实验牙牙髓造成刺激,从而激发穿髓孔周围原有的成牙本质细胞的生物活性,形成刺激性牙本质,最终钙化桥与刺激性牙本质相连以封闭穿髓孔。

在实验初期,盖髓剂与新生的钙化桥之间存在少量混合着细胞、纤维、钙化灶的组织,这三层组织类似于三明治结构,此后,钙化桥与盖髓剂之间出现少量坏死组织。可能是因为盖髓材料不断释放离子,导致夹在盖髓剂和钙化桥之间的组织处于酸碱平衡失调状态,微环境改变,同时由于缺少营养供给进一步发生变性坏死,但穿髓孔及下方区域的牙髓损伤修复的细胞来源和过程较为复杂,此推论仍需大量研究进行验证。

3.4 实验设计不足与展望

本实验尚存在一定不足,术后观察时间设置不够合理,本实验只设置了2个时间点,在术后7d,穿髓孔下方已观察到钙化桥形成,可设置更早期并延长后期观察时间,如将观察时间设置为术后3、7、14、28、54d,这样的设置可能更利于观察牙髓损伤修复的动态过程。

综上所述,PRF联合MTA应用于直接盖髓术时,牙髓炎症反应程度较轻且与MTA相当,但形成钙化桥的能力较MTA强,钙化桥的结构类似于骨样牙本质。但其促进钙化桥形成的动态过程不明,且盖髓材料是否会影响钙化桥形成的方式,形成方式不同是否会影响钙化桥的组织结构和直接盖髓的疗效,仍需大量研究进行探讨。

【Author contributions】 Yang X performed the experiments, analyzed the data, and wrote the article. Yan ZH, Liu J, Hu YP revised the article. Li SF designed the study. All authors read and approved the final manuscript as submitted.

参考文献

- [1] Jin R, Song G, Chai J, et al. Effects of concentrated growth factor on proliferation, migration, and differentiation of human dental pulp stem cells *in vitro*[J]. *J Tissue Eng*, 2018, 9: 2041731418817505. doi: 10.1177/2041731418817505.
- [2] Woo SM, Kim WJ, Lim HS, et al. Combination of mineral trioxide aggregate and platelet-rich fibrin promotes the odontoblastic differentiation and mineralization of human dental pulp cells *via* BMP/Smad signaling pathway[J]. *J Endod*, 2016, 42(1): 82 - 88. doi: 10.1016/j.joen.2015.06.019.
- [3] 胡玉萍, 杨雪, 颜志豪, 等. PRF联合MTA用于兔牙直接盖髓术的影像学研究[J]. *口腔医学研究*, 2021, 37(7): 656-660. doi: 10.13701/j.cnki.kqyxj.2021.07.017.
Hu YP, Yang X, Yan ZH, et al. Radiographic study of PRF combined with MTA for direct pulp capping of rabbit teeth[J]. *J Oral*

- Sci Res, 2021, 37(7) : 656-660. doi: 10.13701/j.cnki.kqxyj.2021.07.017.
- [4] El-Din EA, Hamama HH, Abo EE, et al. The effect of four materials on direct pulp capping: an animal study[J]. Aust Endod J, 2020, 46: 249-256. doi: 10.1111/aej.12400.
- [5] Soliman HA, El-Toukhy RI, Ebrahim MM, et al. Influence of selective immunosuppressive drug regimens on the healing of exposed dogs' dental pulp capped with a recent calcium silicate-based cement[J]. Clin Oral Investig, 2022, 26(2): 1417-1425. doi: 10.1007/s00784-021-04116-y.
- [6] Qiao J, An N, Ouyang XY. Quantification of growth factors in different platelet concentrates[J]. Platelets, 2017, 28(8): 774 - 778. doi: 10.1080/09537104.2016.1267338.
- [7] Nosrat A, Bolhari B, Saber TS, et al. Revitalizing previously treated teeth with open apices: a case report and a literature review[J]. Int Endod J, 2021, 54(10): 1782-1793. doi: 10.1111/iej.13570.
- [8] Chen Y, Chen XL, Zhang YL, et al. Materials for pulpotomy in immature permanent teeth: a systematic review and meta-analysis[J]. BMC Oral Health, 2019, 19(1): 227. doi: 10.1186/s12903-019-0917-z.
- [9] Kulkarni MR, Mohan J, Bakshi PV. Platelet-rich fibrin as a grafting material in periapical surgery: a case series[J]. Int J Periodontics Restorative Dent, 2019, 39(4): 123 - 127. doi: 10.11607/prd.3510.
- [10] Dou L, Yan QF, Yang DQ. Effect of five dental pulp capping agents on cell proliferation, viability, apoptosis and mineralization of human dental pulp cells[J]. Exp Ther Med, 2020, 19(3): 2377-2383. doi: 10.3892/etm.2020.8444.
- [11] Isobe K, Watanebe T, Kawabata H, et al. Mechanical and degradation properties of advanced platelet-rich fibrin (A-PRF), concentrated growth factors (CGF), and platelet-poor plasma-derived fibrin (PPTF)[J]. Int J Implant Dent, 2017, 3(1): 17. doi: 10.1186/s40729-017-0081-7.
- [12] Girija K, Kavitha M. Comparative evaluation of platelet-rich fibrin, platelet-rich fibrin + 50 wt% nanohydroxyapatite, platelet-rich fibrin + 50 wt% dentin chips on odontoblastic differentiation--an *in vitro* study-part 2[J]. J Conserv Dent, 2020, 23(4): 354-358. doi: 10.4103/JCD.JCD_3_20.
- [13] Saeed M, El-Rahman MA, Helal ME, et al. Efficacy of human platelet rich fibrin exudate *vs* fetal bovine serum on proliferation and differentiation of dental pulp stem cells[J]. Int J Stem Cells, 2017, 10(1): 38-47. doi: 10.15283/ijsc16067.
- [14] Yaemkleebua K, Osathanon T, Nowwarote N, et al. Analysis of hard tissue regeneration and Wnt signalling in dental pulp tissues after direct pulp capping with different materials[J]. Int Endod J, 2019, 52(11): 1605-1616. doi: 10.1111/iej.13162.
- [15] Murat M, Ekim OO, Burcu S, et al. The inflammatory response of the pulp after direct capping with platelet-rich plasma and enamel matrix derivative: a controlled animal study[J]. Open J Stomatol, 2014, 4(1) : 14-21. doi: 10.4236/ojst.2014.41004.
- [16] 李永斌, 孙迎春, 韦荣智, 等. 浓缩生长因子纤维蛋白与富血小板纤维蛋白体外降解的对比[J]. 中国组织工程研究, 2017, 21(14): 2234-2240. doi: 10.3969/j.issn.2095-4344.2017.14.017.
- Li YB, Sun YC, Wei RZ, et al. *In vitro* degradation of concentrated growth factor fibrin *versus* platelet-rich fibrin[J]. Chin J Tissue Eng Res, 2017, 21(14): 2234 - 2240. doi: 10.3969/j.issn.2095 - 4344.2017.14.017.
- [17] Ersahan S, Oktay EA, Sabuncuoglu FA, et al. Evaluation of the cytotoxicity of contemporary glass-ionomer cements on mouse fibroblasts and human dental pulp cells[J]. Eur Arch Paediatr Dent, 2020, 21(3): 321-328. doi: 10.1007/s40368-019-00481-1.
- [18] Nangia U, Mala K, Shetty N, et al. Histological analysis of human pulp following direct pulp capping with different materials: an *ex vivo* study[J]. J Conserv Dent, 2021, 24(6): 585-588. doi: 10.4103/jcd.jcd_486_21.
- [19] Didilescu AC, Cristache CM, Andrei M, et al. The effect of dental pulp-capping materials on hard-tissue barrier formation: a systematic review and meta-analysis[J]. J Am Dent Assoc, 2018, 149(10): 903-917. doi: 10.1016/j.adaj.2018.06.003.
- [20] El-Din EA, Hamama HH, Abo EE, et al. The effect of four materials on direct pulp capping: an animal study[J]. Aust Endod J, 2020, 3(4): 345-349. doi: 10.1111/aej.12400.
- [21] 谭学莲, 甯佳丽, 徐玮哲, 等. 上颌磨牙远颊根行显微根尖外科手术保存活髓病例报告及文献复习[J]. 口腔疾病防治, 2020, 28(11): 723-727. doi: 10.12016/j.issn.2096-1456.2020.11.008.
- Tan XL, Ning JL, Xu WZ, et al. Case report and literature review of vital pulp preservation by endodontic microsurgery at the distal buccal root of maxillary molar[J]. J Prev Treat Stomatol, 2020, 28(11): 723-727. doi: 10.12016/j.issn.2096-1456.2020.11.008.
- [22] Alsoubait S, Aljarbou F. Biodentine or mineral trioxide aggregate as direct pulp capping material in mature permanent teeth with carious exposure? A systematic review and meta-analysis[J]. Oper Dent, 2021, 46(6): 631-640. doi: 10.2341/20-277-LIT.
- [23] 于世凤. 口腔组织病理学[M]. 7版. 北京: 人民卫生出版社, 2012: 70.
- Yu SF. Oral Histopathology[M]. 7th ed. Beijing: People's Medical Publishing House, 2012: 70.
- [24] Tran X, Vinh SH, Truong MT, et al. Reparative mineralized tissue characterization after direct pulp capping with calcium-silicate-based cements[J]. Materials(Basel), 2019, 12(13): 2102. doi: 10.3390/ma12132102.
- [25] Tziafas D. Characterization of odontoblast-like cell phenotype and reparative dentin formation *in vivo*: a comprehensive literature review[J]. J Endod, 2019, 45(3): 241-249. doi: 10.1016/j.joen.2018.12.002.
- [26] Suzuki M, Taira Y, Kato C, et al. Histological evaluation of direct pulp capping of rat pulp with experimentally developed low-viscosity adhesives containing reparative dentin-promoting agents[J]. J Dent, 2016, 44: 27-36. doi: 10.1016/j.jdent.2015.11.005.

(编辑 张琳, 麻丹丹)



官网