

[DOI]10.12016/j.issn.2096-1456.2023.03.006

· 防治实践 ·

儿童难治性腮腺气肿1例报道及文献回顾

葛良玉¹, 季莉², 陈霖³, 李志萍¹, 顾倩平¹, 孟箭¹, 张静¹

1. 徐州市中心医院口腔科, 江苏 徐州(221000); 2. 徐州市中医院, 江苏 徐州(221000); 3. 徐州医科大学, 江苏 徐州(221000)

【摘要】 目的 探讨腮腺气肿的治疗方法,为临床提供参考。方法 报道1例儿童难治性腮腺气肿,结合文献对腮腺气肿的诊疗进行回顾分析。结果 该例患儿无明显诱因腮腺肿大1个月余,经抗炎治疗、心理干预治疗、物理加压治疗等保守治疗后无效,患儿既往有脑瘫伴癫痫病史,存在非自主性鼓颊行为,考虑为难治性病例。经腮腺导管结扎及腮腺浅叶部分切除术后得到根治。文献回顾表明,腮腺气肿是一种罕见的腮腺肿大,多为口腔内压力增加引起空气经腮腺导管返流入腮腺内所致,其诊断主要依靠间歇性的腮腺肿胀等临床表现及超声、CT、MRI、造影等影像学检查手段。现阶段治疗措施主要包括保守抗炎治疗、物理治疗、心理干预,手术治疗是难治性腮腺气肿的最终治疗手段。结论 腮腺气肿有进一步发展为腮腺炎症的可能,一般采取保守治疗,对于一些重症、复发性以及依从性差的病例,需要进行手术治疗。

【关键词】 腮腺; 腮腺气肿; 腮腺导管; 腮腺肿大; 压力; 返流; 难治性; 手术治疗

【中图分类号】 R78 **【文献标志码】** A **【文章编号】** 2096-1456(2023)03-0192-05

【引用著录格式】 葛良玉,季莉,陈霖,等. 儿童难治性腮腺气肿1例报道及文献回顾[J]. 口腔疾病防治, 2023, 31(3): 192-196. doi:10.12016/j.issn.2096-1456.2023.03.006.



微信公众号

Refractory pneumoparotid in children: a case report and literature review GE Liangyu¹, JI Li², CHEN Lin³, LI Zhiping¹, GU Qianping¹, MENG Jian¹, ZHANG Jing¹. 1. Department of Stomatology, Xuzhou Central Hospital, Xuzhou 221000, China; 2. Xuzhou Hospital of Traditional Chinese Medicine, Xuzhou 221000, China; 3. Xuzhou Medical University, Xuzhou 221000, China

Corresponding author: MENG Jian, Email: mrocket@126.com, Tel: 86-18952170986

【Abstract】 Objective To discuss the treatment of pneumoparotid and to provide a reference for clinical practice. **Methods** A case of refractory pneumoparotid was reported, and the diagnosis and treatment of parotid emphysema were reviewed and analyzed in combination with the literature. **Results** This child had parotid gland enlargement without any obvious cause for more than 1 month. Conservative treatment, such as anti-inflammatory agents, psychological interventions and physical compression were ineffective. The patient had a history of cerebral palsy with epilepsy and involuntary cheek bulging behavior. Therefore, we considered it a refractory case. It was cured after parotid duct ligation and partial parotidectomy of the superficial lobe. A literature review showed that a pneumoparotid is a rare parotid enlargement. Most of the clinical cases were considered to be caused by the return of air into the parotid gland through the parotid duct due to an increase in oral pressure. The diagnosis of pneumoparotid mainly depends on intermittent parotid gland swelling and other clinical manifestations and imaging examination methods, such as ultrasound, CT, MRI and angiography. Its treatment mainly includes conservative anti-inflammatory treatment, physical therapy and psychological intervention. Surgical treatment is indicated for refractory parotid emphysema. **Conclusion** Pneumoparotid cases may further develop into parotid inflammation, which is generally treated conservatively. For some severe, recurrent and poor compliance cases, surgical treatment is sometimes needed.

【Key words】 parotid gland; pneumoparotid; parotid duct; parotid enlargement; pressure; backflow; refrac-

【收稿日期】 2022-04-29; **【修回日期】** 2022-08-31

【基金项目】 国家自然科学基金项目(31700814);江苏省卫生计生委科研资助项目(H2017080);徐州市医学创新(技术攻关)团队项目(XWCX201604);徐州市科技局重点研发项目(ZYSB20210230)

【作者简介】 葛良玉,主治医师,硕士,Email:547962197@qq.com

【通信作者】 孟箭,主任医师,硕士,Email:mrocket@126.com, Tel:86-18952170986

tory; surgical treatment

J Prev Treat Stomatol Dis, 2023, 31(3): 192-196.

【Competing interests】 The authors declare no competing interests.

This study was supported by the grants from National Natural Science Foundation of China (No. 31700814); Scientific Research Support Project of Jiangsu Provincial Health and Family Planning Commission (No. H2017080); Xuzhou Medical Innovation and Technological Breakthrough Team Project (No. XWCX201604); Key Project of Xuzhou Science and Technology Bureau (No. ZYSB20210230).

腮腺气肿由 Hyrtl 于 1865 年首次报道,并定义为腮腺系统包括腺体和腮腺导管内异常存在的气腔^[1]。腮腺气肿在临床上较为罕见,存在误诊、误判以及治疗不当的可能。笔者报告 1 例难治性腮腺气肿经手术达到根治的病例,并就腮腺气肿的病因、临床表现、诊断和治疗进行相关文献回顾。

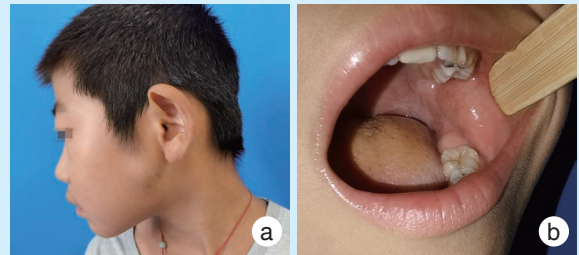
1 临床资料

1.1 病史及检查

患儿,男,10岁2个月,因“左面部肿胀1月余”入院,患儿1个月前无明显诱因情况下出现左面部肿胀,外院予以穿刺及压迫处理,合并抗炎治疗2周,左颊肿胀未见消退,遂来我院就诊。门诊拟“左面部肿物”收入院,入院时神志清,查体合作,无感冒发热畏寒等不适症状,睡眠、饮食及二便正常,一般健康状况良好。否认高血压、冠心病及糖尿病史,否认有肝炎结核病史,否认有青霉素等药物过敏史,否认手术外伤史,无输血史。患儿既往有脑瘫伴癫痫病史10年余,自服奥卡西平片0.3 g, bid, 诉控制良好。患儿生长发育及营养状况一般,体质量25.5 kg。入院时专科检查:面部表情正常,左耳屏前区广泛肿胀(图1a),范围约3.0 cm × 2.5 cm,界不清,质软,无触压痛。口内检查示:混合牙列,咬合关系正常,54、65乳磨牙深龋,无牙列缺损。三对大涎腺导管口无红肿,挤压左侧腮腺,导管口未见明显分泌物(图1b),右侧腮腺分泌液清亮。双侧颞下颌关节区无红肿,无凹陷,双侧活动对称,未及弹响,开口型正常,无绞锁。

患者入院后完善腮腺 MRI 平扫:左侧咬肌肿胀,外侧低信号,积气(图2a),可见腮腺导管由气腔内穿行(图2b、2c),气腔周围腺体组织炎性表现(图2d),左侧腮腺导管扩张(图2e、2f)。

行左腮腺唾液腺造影:左侧腮腺主导管充盈良好,未见明显狭窄及充盈缺损,分支导管粗细不均,腺泡不同程度扩张,左侧腮腺肿胀(图3a),左侧腮腺下方示囊样低密度影,边缘光滑,未见造影



a: swelling of the left cheek, b: no obvious secretion at the duct orifice of the left parotid gland

Figure 1 Preoperative images of a patient with pneumoparotid

图1 腮腺气肿患者术前照

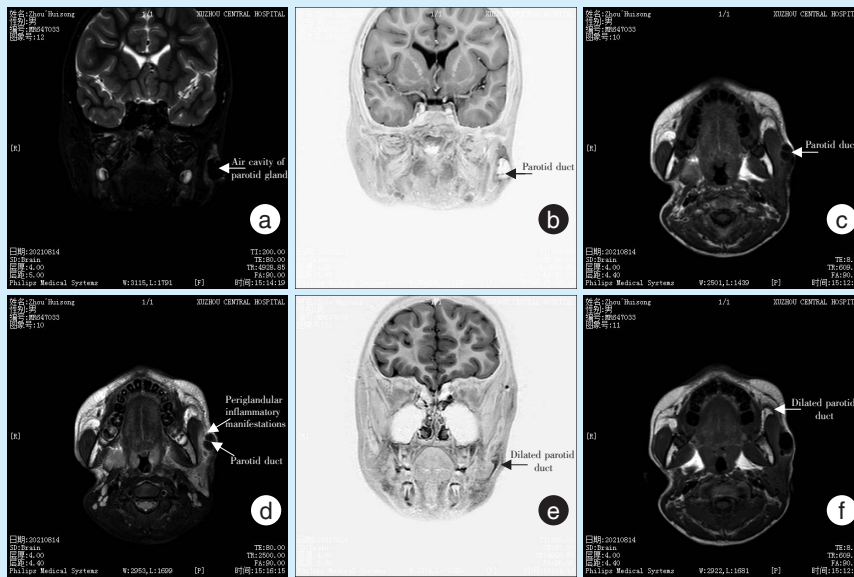
剂充盈(图3b),腮腺导管由气腔内穿行(图3c),20 min后再次摄片腮腺导管内未见造影剂残留(图3d)。行细针穿刺检查,注射器仅能抽吸出气体,约5 mL,穿刺抽吸后左面部肿物塌陷。口腔鼓气时,左腮腺区再次隆起。结合穿刺及影像学检查,考虑为腮腺气肿。

1.2 治疗

与患儿家属沟通治疗方案,包括:①保守抗炎治疗;②局部穿刺后继续行加压包扎,结合抗炎治疗;③手术行腮腺浅叶部分切除术及腮腺导管结扎术。

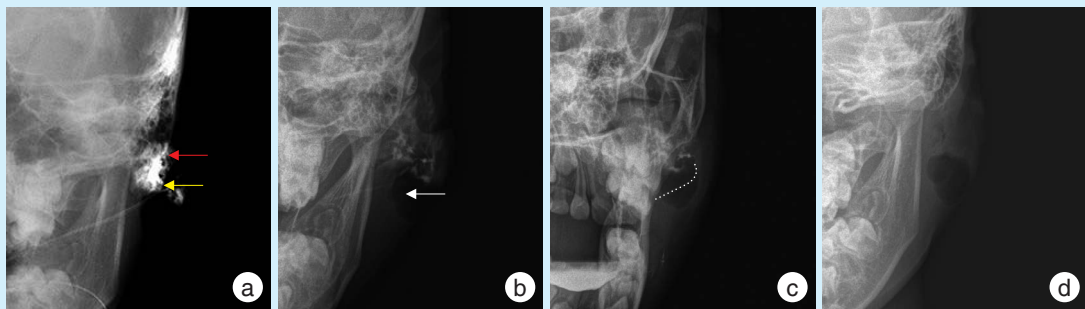
经沟通后行左腮腺气肿穿刺抽吸后立即使用弹性绷带加压包扎左腮腺区,持续加压2 d后见左腮腺区肿胀变化不显,遂再次穿刺抽吸并行加压包扎,术程中予患儿对症抗炎治疗,持续加压包扎3 d后患儿左腮腺肿胀未缓解。

考虑保守治疗无效,与患儿家属再次沟通后决定行手术治疗。排除麻醉及手术禁忌,于入院第6天静吸复合全麻下行“腮腺浅叶部分切除术+腮腺导管结扎术+面神经解剖术”。手术顺利,术中见左腮腺导管粗大,气腔无明显囊壁样结构。术后病理示:(左腮腺)气肿伴周围慢性化脓性炎(图4)。术后绷带加压,术后第2天拔除左腮腺负



a: MRI showed the gas image in the left parotid gland (arrow); b&c: STIR and T1W images showed the parotid duct (arrow) passing through the air cavity; d: T2W images showed the inflammatory manifestations of the glands around the air cavity (arrows); e&f: STIR and T1W images showed the dilation of the left parotid duct (arrow)

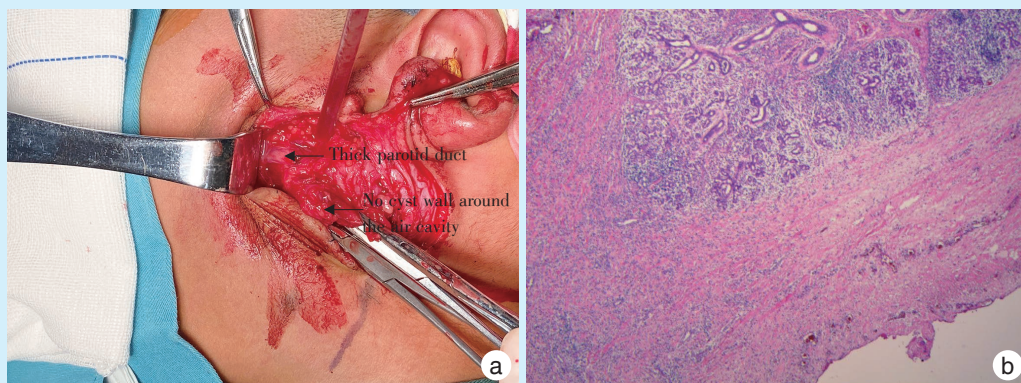
Figure 2 Preoperative MRI imaging of a patient with pneumoparotid
图2 腮腺气肿患者术前MRI影像资料



a: the main duct of the left parotid gland was well filled, no obvious stenosis or filling defect was found, the thickness of the branch duct was uneven (red arrow), and the acini expanded to varying degrees (yellow arrow); b: radiography showed cystic low-density shadow (arrow) in the left parotid gland; c: parotid duct (dotted lines) passing through the air cavity; d: no contrast agent remained in the parotid duct after 20 min

Figure 3 Preoperative salivary gland angiography of a patient with pneumoparotid

图3 腮腺气肿患者术前唾液腺造影影像资料



a: the duct of the left parotid gland was thick, and there was no obvious cyst wall like structure in the air cavity (arrows); b: pathological section showed chronic inflammatory infiltration of glandular tissue (HE ×100)

Figure 4 Intraoperative air cavity image and postoperative pathological image of a patient with pneumoparotid

图4 腮腺气肿患者术中气腔图像和术后病理图片

压引流管,术后第8天,患儿一般情况可,左腮腺区术创愈合良好,拆除加压绷带后左腮腺无肿胀,触诊无肿块及积气,腮腺气肿得到根治,患儿顺利出院。

2 讨论

腮腺气肿是一种罕见的腮腺肿大,常合并皮下气肿,并延伸到周围的颈面部皮下组织^[2],导致腮腺区肿胀。腮腺气肿的发生通常由空气和唾液通过腮腺导管逆行注入次级导管和腺泡所致^[3]。颊肌张力减退、咬肌肥大或黏液暂时阻塞腮腺导管被认为是可能的危险因素^[1]。Gazia等^[4]在总结既往的腮腺气肿文献报告后发现,腮腺气肿的病因构成为:非自主鼓颊动作引起的肿胀(53.7%)、特发性病例(24.1%)、医源性原因(16.6%)、慢性支气管炎患者(5.5%)。

口腔固有的一些解剖学因素通常可预防空气和唾液通过腮腺导管逆行进入腮腺,这些因素包括:①导管口邻近上颌第二磨牙,呈狭缝状,周围存在黏膜皱襞环绕,当口腔内压力增加时,黏膜皱襞可覆盖管口;②导管口直径小于导管本身直径;③口腔压力增加时,颊肌收缩进一步压缩导管^[5]。这些解剖结构的异常,如腮腺导管扩张、颊肌无力或咬肌肥大,可能会诱发腮腺气肿^[6]。正常口腔内呼气压力为2~3 mmHg,吹玻璃和吹小号时口腔内压力可增140~150 mmHg^[7]。由压缩空气驱动的牙科器械可能会使口腔内压力增加60~65 mmHg^[8]。口腔内压力急剧增加时可能会突破腮腺的正常保护机制而致空气和唾液逆行进入导管系统。此外,医源性因素除牙科因素(55.5%)外,还包括持续气道正压通气(continuous positive airway pressure, CPAP)的使用(33.4%)和肺活量测定(11.1%)^[4,9-10]。

轻症腮腺气肿患者经常不能自主发现,临床上常表现为慢性病程,出现间歇性腮腺肿胀,或不伴疼痛。文献报道,临床检查可以发现腮腺导管乳头肿胀,按压腮腺可见腮腺导管冒出泡沫状唾液^[6,11]。但该例患儿以不明原因的腮腺肿胀为主要临床表现,无明显触压痛,患侧腮腺导管口未见明显红肿,挤压患侧腮腺,导管口未见明显分泌物,因此笔者认为腮腺导管乳头肿胀及按压腮腺见腮腺导管泡沫状唾液为腮腺气肿非特异性临床表现。

腮腺气肿的诊断主要依靠临床表现及影像学检查。影像学检查可对腮腺气肿及其并发症明确

诊断。超声检查是头颈部浅表肿胀首选检查手段,可以在腮腺区标记出在腺实质、导管和软组织中的空气为高回声信号。超声对腮腺气肿的早期诊断有效^[12],超声检查简单、可靠、无创、经济高效,并可提供实时动态成像^[13]。然而,超声检查对气体的范围、分布和来源以及深部腔室并发症显像可能并不明显,在这种情况下,CT检查可以显示腮腺内的空气和相关并发症,同时也可以排除潜在的涎石症^[14]。因此,CT检查被认为是腮腺气肿的首选检查方法^[15]。腮腺充气CT与简单CT相比,可以显示导管和腺体内空气的轻微变化^[16]。磁共振成像可能显示与并发症相关的腮腺信号变化,但空气可能不容易识别^[13]。唾液腺造影通常显示腮腺导管明显扩张,但造影检查存在潜在的并发症^[6]。近年来,涎腺镜检查已成为一种良好的常规技术和腮腺微创诊断技术,对评估唾液导管系统效果良好^[3]。本例患儿因术前经过穿刺加压等诊治,对于腮腺气肿的诊断是明确的,因此入院后未行CT检查,而是进行磁共振检查以明确气腔周围炎性浸润状况,行唾液腺造影以观察腮腺各级导管及腺泡影像学表现,以为后续治疗方案制定起到关键的辅助作用。

腮腺气肿急性期治疗包括应用抗生素,如果肿胀严重,可添加类固醇激素。一般辅助治疗手段包括腺体按摩、多饮水、漱口和热敷等。对于自我诱发的腮腺气肿病例,必要时需进行心理治疗,以纠正潜在的适应性精神障碍。在严重病例或复发时,有时需要进行手术治疗,手术方式包括:腮腺导管结扎术、部分腮腺切除术和腮腺导管改道术等^[6,17]。腮腺导管结扎术被认为是治疗复发性或慢性严重腮腺感染的金标准。在极少数情况下需要进行腮腺切除术,通常是在患者依从性不佳、治疗失败或慢性感染的情况下,腮腺切除术是最后的治疗手段^[18-20]。腮腺切除术是一种有创治疗,可能会导致面神经损伤、Frey综合征、涎痿、耳大神经损伤和瘢痕等并发症^[21-22]。手术作为难治性腮腺气肿的最终治疗手段,应严格把握适应证。

此例患者病史时间长达1个月余,且经抗炎治疗、心理干预治疗、物理加压治疗等保守治疗方案后无效,患者既往脑瘫伴癫痫病史,存在非自主性的鼓颊行为,考虑为难治性病例,遂最终采取腮腺导管结扎术及部分腮腺切除术的手术治疗方式,达到良好治疗效果。

腮腺气肿是一种非真性病理状态,其特征是

腮腺导管和腺体中存在空气。腮腺气肿最常见的病因是非自主鼓颊,其主要原因是精神障碍。涎腺造影和CT有助于评估腺体受累程度和结构损伤。腮腺气肿应根据每个患者的具体病情选择合理的治疗方案,如果伴有腮腺炎性表现,先行抗生素治疗。如果出现皮下气肿,必须评估患者临床表现、气肿大小和复发率,以避免演变为纵膈气肿。对重症病例,针吸或手术治疗是适合的。对于复发病例,应考虑更积极的手术治疗。同时,应注意行为矫正和心理治疗,优先解决病因,根据患者情况全面管理,以减少并发症的发生。

【Author contributions】 Ge LY participated in the data collation and wrote the article. Ji L, Chen L collected the data and search the literature. Li ZP, Gu QP, Meng J, Zhang J determined the framework of the article and revised the article. All authors read and approved the final manuscript as submitted.

参考文献

- [1] Zuchi DF, da Silveira PC, de Oliveira Cardoso C, et al. Pneumoparotitis[J]. Braz J Otorhinolaryngol, 2011, 77(6): 806.
- [2] Balasubramanian S, Srinivas S, Aparna KR. Pneumoparotitis with subcutaneous emphysema[J]. Indian Pediatr, 2008, 45(1): 58-60.
- [3] Konstantinidis I, Chatziavramidis A, Constantinidis J. Conservative management of bilateral pneumoparotitis with sialendoscopy and steroid irrigation[J]. BMJ Case Rep, 2014: bcr2013201429. doi: 10.1136/bcr-2013-201429.
- [4] Gazia F, Freni F, Galletti C, et al. Pneumoparotid and pneumoparotitis: a literary review[J]. Int J Environ Res Public Health, 2020, 17(11): 3936. doi: 10.3390/ijerph17113936.
- [5] Calcaterra TC, Pneumoparotiditis LJ. Pneumoparotiditis. An unusual case of parotid gland swelling[J]. Arch Otolaryngol, 1973, 97(6): 468-469. doi: 10.1001/archotol.1973.00780010482008.
- [6] Lagunas J, Fuertes A. Self-induced parapharyngeal and parotid emphysema: a case of pneumoparotitis[J]. Oral Maxillofac Surg Cases, 2017, 3(4): 81-88. doi: 10.1016/j.oms.2017.06.002.
- [7] Banks P. Nonneoplastic parotid swellings: a review[J]. Oral Surg Oral Med Oral Pathol, 1968, 25(5): 732-745. doi: 10.1016/0030-4220(68)90043-1.
- [8] Brown FH, Ogletree RC, Houston GD. Pneumoparotitis associated with the use of an air-powder prophylaxis unit[J]. J Periodontol, 1992, 63(7): 642-644. doi: 10.1902/jop.1992.63.7.642.
- [9] Abdullayev R, Saral FC, Kucukebe OB, et al. Bilateral parotitis in a patient under continuous positive airway pressure treatment[J]. Braz J Anesthesiol, 2016, 66(6): 661-663. doi: 10.1016/j.bjane.2014.05.008.
- [10] Goates AJ, Lee DJ, Maley JE, et al. Pneumoparotitis as a complication of long-term oronasal positive airway pressure for sleep apnea[J]. Head Neck, 2018, 40(1): e5-e8. doi: 10.1002/hed.25003.
- [11] Yoshida K. Pneumoparotid related to obstructive sleep apnea syndrome treated by oral appliance with anterior opening to reduce intraoral pressure[J]. Clin Case Rep, 2022, 10(5): e05816. doi: 10.1002/ccr3.5816.
- [12] Yamazaki H, Kojima R, Nakanishi Y, et al. A case of early pneumoparotid presenting with oral noises[J]. J Oral Maxillofac Surg, 2018, 76(1): 67-69. doi: 10.1016/j.joms.2017.05.039.
- [13] Potet J, Arnaud FX, Valbousquet L, et al. Pneumoparotid, a rare diagnosis to consider when faced with unexplained parotid swelling[J]. Diagn Interv Imaging, 2013, 94(1): 95-97. doi: 10.1016/j.diii.2012.04.015.
- [14] McGreevy AE, O'Kane AM, McCaul D, et al. Pneumoparotitis: a case report[J]. Head Neck, 2013, 35(2): e55-e59. doi: 10.1002/hed.21873.
- [15] Gray SC, Pienaar JA, Sofianos Z, et al. Complicated spontaneous pneumoparotid mimicking a neck mass in a child with Down's syndrome[J]. SA J Radiol, 2020, 24(1): 1883. doi: 10.4102/sajr.v24i1.1883.
- [16] Aghaei LA, Nemeth AJ, Russell EJ, et al. The use of the "puffed-cheek" computed tomography technique to confirm the diagnosis of pneumoparotitis[J]. Laryngoscope, 2010, 120(5): 967-969. doi: 10.1002/lary.20879.
- [17] House LK, Lewis AF. Pneumoparotitis[J]. Clin Exp Emerg Med, 2018, 5(4): 282-285. doi: 10.15441/ceem.17.291.
- [18] Nassimbeni G, Ventura A, Boehm P, et al. Self-induced pneumoparotitis[J]. Clin Pediatr (Phila), 1995, 34(3): 160-162. doi: 10.1177/000992289503400309.
- [19] Han S, Isaacson G. Recurrent pneumoparotid: cause and treatment[J]. Otolaryngol Head Neck Surg, 2004, 131(5): 758-761. doi: 10.1016/j.otohns.2004.04.035.
- [20] Apaydin M, Sarsilmaz A, Calli C, et al. Giant pneumoparotitis[J]. Eur J Radiol Extra, 2004, 52: 17-20. doi: 10.1016/j.ejrex.2004.07.005.
- [21] Freni F, Gazia F, Stagno d'Alcontres F, et al. Use of botulinum toxin in Frey's syndrome[J]. Clin Case Rep, 2019, 7(3): 482-485. doi: 10.1002/ccr3.2019.
- [22] Moltrecht M, Michel O. The woman behind Frey's syndrome: the tragic life of Lucja Frey[J]. Laryngoscope, 2004, 114(12): 2205-2209. doi: 10.1097/01.mlg.0000149459.98629.cf.

(编辑 张琳, 栾修文)



官网