

[DOI]10.12016/j.issn.2096-1456.2023.04.005

· 临床研究 ·

# 以硬膜外导管为支架行腮腺导管吻合术及术后腺体功能评价

葛良玉<sup>1</sup>, 季莉<sup>2</sup>, 陈霖<sup>3</sup>, 李志萍<sup>1</sup>, 顾倩平<sup>1</sup>, 孟箭<sup>1</sup>, 张静<sup>1</sup>

1. 徐州市中心医院口腔科, 江苏 徐州(221000); 2. 徐州市中医院, 江苏 徐州(221000); 3. 徐州医科大学, 江苏 徐州(221000)

**【摘要】** 目的 探讨硬膜外导管在腮腺导管吻合术中应用的可行性及对腺体功能的影响。方法 选择2019年1月至2021年6月就诊于徐州市中心医院口腔颌面外科并采用硬膜外导管为支架进行腮腺导管吻合的13例患者,评价术后2周腮腺区有无肿胀、涎瘘及导管通畅情况,采用<sup>99m</sup>TcO<sub>4</sub><sup>-</sup>单光子发射计算机断层扫描(single photon emission computed tomography, SPECT)进行唾液腺分泌功能定量检测。结果 术后2周拔除硬膜外导管,13例患者患侧腮腺区均无肿胀及涎瘘,导管分泌通畅;术后3个月患侧腮腺与健侧腮腺摄取率无显著差异( $t = -0.859, P = 0.399$ ),患侧腮腺与健侧腮腺排泄率无显著差异( $t = 0.693, P = 0.495$ ),患侧腮腺分泌功能良好。结论 以硬膜外导管做支架的腮腺导管吻合术具有良好的可行性,术后腮腺分泌功能恢复良好,值得临床推广应用。

**【关键词】** 唾液腺损伤; 腮腺导管瘘; 硬膜外导管; 腮腺导管吻合术; 支架; 涎瘘; 肿胀; 分泌功能; 单光子发射计算机断层扫描

**【中图分类号】** R78 **【文献标志码】** A **【文章编号】** 2096-1456(2023)04-0257-04

**【引用著录格式】** 葛良玉, 季莉, 陈霖, 等. 以硬膜外导管为支架行腮腺导管吻合术及术后腺体功能评价[J]. 口腔疾病防治, 2023, 31(4): 257-260. doi:10.12016/j.issn.2096-1456.2023.04.005.

## Parotid duct anastomosis with an epidural catheter as a stent and evaluation of postoperative gland function

GE Liangyu<sup>1</sup>, JI Li<sup>2</sup>, CHEN Lin<sup>3</sup>, LI Zhiping<sup>1</sup>, GU Qianping<sup>1</sup>, MENG Jian<sup>1</sup>, ZHANG Jing<sup>1</sup>. 1. Department of Stomatology, Xuzhou Central Hospital, Xuzhou 221000, China; 2. Xuzhou Hospital of Traditional Chinese Medicine, Xuzhou 221000, China; 3. Xuzhou Medical University, Xuzhou 221000, China

Corresponding author: MENG Jian, Email: mrocket@126.com, Tel: 86-18952170986

**【Abstract】** **Objective** To investigate the feasibility of epidural catheters in parotid gland duct anastomosis and the function of the affected side gland after parotid gland duct anastomosis. **Methods** Thirteen patients who were treated in the Department of Oral and Maxillofacial Surgery of Xuzhou Central Hospital using an epidural catheter as the scaffold for parotid gland catheter anastomosis were enrolled from Jan. 2019 to June 2021. The swelling, salivary fistula and catheter patency in the parotid gland area were evaluated two weeks after the operation. <sup>99m</sup>TcO<sub>4</sub><sup>-</sup> single photon emission computed tomography (SPECT) was used for quantitative detection of salivary gland secretion function. **Results** Thirteen patients had no swelling or salivary fistula in the parotid gland area of the affected side two weeks after the operation, and the catheter secretion was unobstructed. There was no significant difference in the uptake rate between the parotid gland on the affected side and the parotid gland on the healthy side ( $t = -0.859, P = 0.399$ ), and there was no significant difference in the excretion rate between the parotid gland on the affected side and the parotid gland on the healthy side ( $t = 0.693, P = 0.495$ ). The parotid gland excretion function of the affected side was excellent three months

**【收稿日期】** 2022-08-12; **【修回日期】** 2022-10-14

**【基金项目】** 国家自然科学基金项目(31700814); 国家口腔疾病临床医学研究中心临床研究项目(NRCO-202101); 江苏省卫生计生委科研资助项目(H2017080); 徐州市医学创新(技术攻关)团队(XWCX201604); 徐州市科技局重点研发项目(ZYSB20210230)

**【作者简介】** 葛良玉, 主治医师, 硕士, Email: 547962197@qq.com

**【通信作者】** 孟箭, 主任医师, 硕士, Email: mrocket@126.com, Tel: 86-18952170986



微信公众号

after the operation. **Conclusion** Parotid duct anastomosis with an epidural catheter as the stent has good feasibility, and parotid gland secretion function recovers well after the operation, which is worthy of clinical application.

**【Key words】** salivary gland injury; parotid duct fistula; epidural catheter; parotid duct anastomosis; scaffold; salivary fistula; swelling; excretion function; single photon emission computed tomography

**J Prev Treat Stomatol Dis, 2023, 31(4): 257-260.**

**【Competing interests】** The authors declare no competing interests.

This study was supported by the grants from National Natural Science Foundation of China (No. 31700814), Clinical Research Project of National Clinical Research Center for Oral Diseases (No. NCRCO-202101), Scientific Research Support Project of Jiangsu Provincial Health and Family Planning Commission (No. H2017080), Xuzhou Medical Innovation and Technological Breakthrough Team Project (No. XWCX201604), Key Project of Xuzhou Science and Technology Bureau (No. ZYSB20210230).

有关腮腺导管损伤的诊疗的文献报道较少,口腔急诊外科中腮腺区损伤较常见,腮腺导管因其位置浅表,易被损伤,且腮腺导管损伤在治疗上具有特殊性,损伤后如处理不当,则形成腮腺瘘、腮腺导管瘘,极大地影响患者的生活质量<sup>[1]</sup>,术后出现并发症,患者需行二次手术<sup>[2]</sup>。因此,对腮腺导管急性损伤,必须仔细探查,对腮腺导管进行及时处理,是防止术后腮腺导管瘘的重要措施。本研究报道利用硬膜外导管作为支架的腮腺导管吻合术,取得良好疗效,现总结报道如下。

## 1 资料和方法

### 1.1 一般资料

选择2019年1月至2021年6月就诊于徐州市中心医院口腔颌面外科并采用硬膜外导管为支架进行腮腺导管吻合的13例患者,男10例,女3例,年龄23~65岁,其中交通事故伤7例,电锯刀砍伤6例。损伤部位:咬肌表面导管损伤9例,咬肌前缘导管损伤4例。9例合并面神经分支损伤,5例合并颧弓骨折,3例合并眶外壁骨折,7例合并上、下颌骨骨折。纳入标准:①年龄在18岁以上(含18岁),75岁以下(含75岁),性别不限;②口腔颌面部软组织外伤累及腮腺导管致腮腺导管断裂;③ECOG评分0~2分;④试验前签署知情同意书;⑤依从性良好。排除标准:①未能获得已签署的知情同意书;②妊娠、哺乳期妇女;③重要脏器功能受损,存在生命危险者;④一个月内接受过放射治疗的患者;⑤腮腺导管缺损范围较大,不适合直接腮腺导管端端吻合者;⑥患有精神疾病,不能配合治疗者;⑦有发热性疾病,无法控制症状者;⑧凝血功能异常,有出血性倾向者;⑨既往30 d内参加过其它临床试验;⑩其它研究者认为不适宜治疗的情

况。纳入研究的患者均签署知情同意书,本研究已经过徐州市中心医院伦理审查(批号:XZXY-LJ-20180514-075)。

### 1.2 手术方法

按患者全身状况及局部损伤情况决定麻醉方法,合并开放性面骨骨折患者同期手术治疗,面部及口腔内常规消毒铺巾,自口内腮腺导管口置硬膜外麻醉导管,可见腮腺导管前断端,解剖探查腮腺导管后断端,游离损伤的腮腺导管两侧断端,将硬膜外导管置入腮腺导管后断端,并按刻度保持置入后断端深度大于2 cm,此时口腔内,将硬膜外导管缝合固定在颊黏膜上。用7-0线于两断端作4~6针端端吻合。

### 1.3 术后2周腮腺功能评价

术后2周,对患者进行常规临床检查,检查患者腮腺区有无肿胀、涎瘘及导管通畅情况,患者唾液腺功能受损后口干程度主观评价方法分级<sup>[3]</sup>:0级为无明显变化,1级为进食时需进水,2级为不进食时需进水,3级为睡眠时需进水。

### 1.4 术后3个月腮腺分泌功能评价

全部患者采用<sup>99m</sup>TcO<sub>4</sub><sup>-</sup>单光子发射计算机断层扫描(single photon emission computed tomography, SPECT)进行唾液腺分泌功能定量检测,注射显像剂<sup>99m</sup>TcO<sub>4</sub><sup>-</sup> 5 m Ci后立即使用SPECT采集数据,注药后13 min时口服维生素C 200 mg,再次采集数据,进行图像处理和计算。主要指标为双侧腮腺的13 min摄取率、内含维生素C片(含酸刺激后)5 min后排泄率、摄取排泄功能曲线。

### 1.5 统计学分析

采用SPSS 22.0软件对健侧及患侧腮腺分泌功能变化进行 $t$ 检验,计量资料以均数 $\pm$ 标准差表示,当 $P < 0.05$ ,认为差异具有统计学意义。

## 2 结果

### 2.1 术后临床检查及腮腺功能评价

术后2周复诊并拔除硬膜外导管,依据口干主观程度分级,13例患者均为0级。术后3个月复诊,13例患者腮腺局部无肿胀,无涎痿,腮腺导管通畅,腮腺分泌功能正常。双侧腮腺及颌下腺显影清晰,位置、形态及大小大致正常,双侧腮腺、颌下腺放射性摄取随时间延长逐渐增加,于13 min时含服维生素C片并继续显像(含酸刺激后显像),双侧腮腺及颌下腺放射性分布迅速降低,口腔内放射性增高。患侧腮腺与健侧腮腺摄取率无显著差异( $t = -0.859, P = 0.399$ ),患侧腮腺与健侧腮腺排泄率无显著差异( $t = 0.693, P = 0.495$ )(表1)。

### 2.2 硬膜外导管腮腺导管吻合术典型病例

患者,男性,35岁,因面部电锯伤急诊入院,体检:生命体征平稳,左侧面颊部见不规则创口,长约10 cm,创口深至咬肌层面,创缘渗血明显。入

表1 硬膜外导管行腮腺导管吻合术后3个月患者唾液腺功能测定结果

Table 1 Results of parotid duct anastomosis with epidural catheter and salivary gland function measurement

|                | 3 months after operation |                           | $\bar{x} \pm s$ |       |
|----------------|--------------------------|---------------------------|-----------------|-------|
|                | Healthy side<br>(n = 13) | Affected side<br>(n = 13) | t               | P     |
| Uptake rate    | 0.36% ± 0.08%            | 0.38% ± 0.07%             | -0.859          | 0.399 |
| Excretion rate | 44.36% ± 6.67%           | 42.33% ± 8.19%            | 0.693           | 0.495 |

院后急诊予以充分清创,探查见腮腺导管断裂,遂置硬膜外导管,用7-0线于两断端做端端吻合,挤压腺体见唾液腺分泌沿硬膜外导管排泄通畅,精细缝合创口,留置引流皮片。术后患者腮腺局部无肿胀,无涎痿,无口干症状,腮腺导管通畅,腮腺分泌功能正常(图1)。术后3个月复查唾液腺SPECT显示患侧腮腺显影及分泌功能正常。

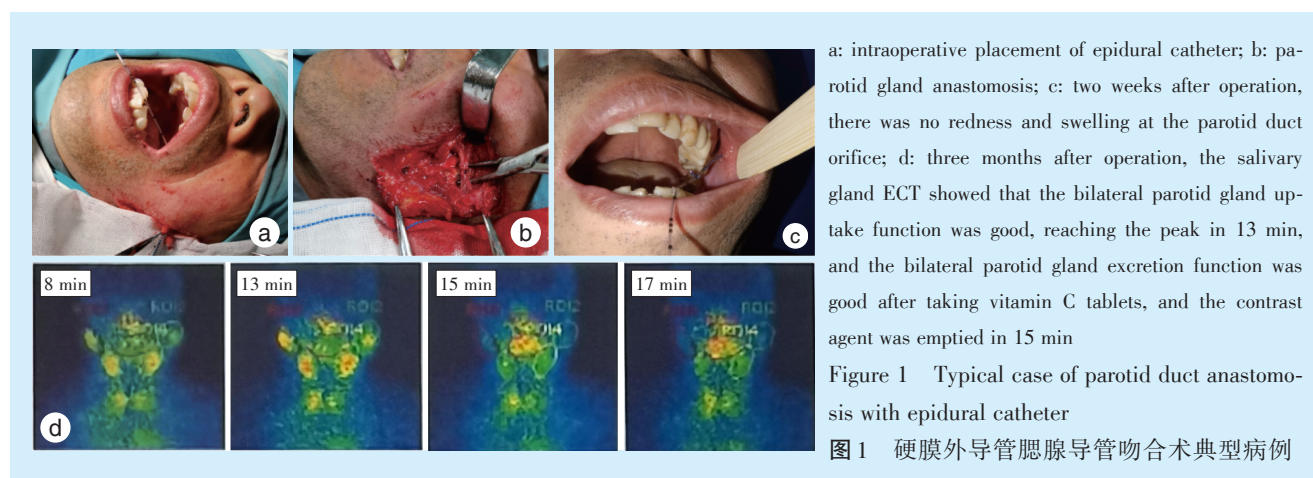


图1 硬膜外导管腮腺导管吻合术典型病例

## 3 讨论

Van Sickels将腮腺导管损伤分为3类:咬肌后缘腮腺腺体组织内导管损伤、咬肌表面导管损伤和咬肌前缘导管损伤<sup>[4]</sup>。有学者对Van Sickels腮腺导管损伤的分类法进行了改良,将腮腺及导管损伤分为4类,A类:腮腺腺体及分支导管损伤;B类:咬肌表面腮腺主导管损伤;C类:咬肌前缘至导管口段导管损伤;D类:腺体及主导管均累及的广泛损伤<sup>[5]</sup>。腮腺内导管损伤的处理方法包括导管结扎、包膜严密缝合后加压、腮腺区域性切除术、局部注射肉毒杆菌毒素等<sup>[6-7]</sup>;咬肌表面导管损伤可直接吻合;嚼肌前缘导管损伤可将导管吻合或口内造瘘<sup>[8-9]</sup>;对于腮腺导管缺损患者,可采用自体动静脉移植重建术<sup>[10]</sup>。

近年来,随着显微外科技术的发展,主张腮腺导管损伤尽可能进行I期修复<sup>[11]</sup>,以管状装置作为支架作用应用于腮腺导管裂伤的导管的端端吻合也有报道<sup>[12-14]</sup>。硬膜外导管的管径接近腮腺导管,且韧性较强,不仅起到支架作用,其管腔还起到引流的作用。有利于吻合处腮腺导管的愈合,并防止腮腺导管狭窄、闭锁造成涎痿或唾液滞留<sup>[15-16]</sup>。

唾液腺SPECT检查可全面、客观地评价唾液腺形态和分泌功能,是简便、无创、灵敏度高的检查方法<sup>[17-18]</sup>。有研究表明对腮腺分泌功能评价唾液腺SPECT检查的敏感性高于腮腺造影组<sup>[19]</sup>。本研究探讨以硬膜外导管作为支架的腮腺导管吻合术后腮腺功能评价,结果显示所有13例患者术后

腮腺区愈合良好,未出现腮腺局部肿胀、涎瘘等并发症,术后腮腺导管通畅,术后3个月患侧腮腺与健侧腮腺摄取率间的差异无统计学意义,术后3个月患侧腮腺与健侧腮腺排泄率间的差异无统计学意义,表明以硬膜外导管作为支架的腮腺导管吻合术在腮腺导管损伤的应用上具有良好的可行性。同时,笔者认为腮腺导管吻合术的成功不仅仅是硬膜外导管的支架作用,同样涉及的包括严格的无菌操作、显微外科技术的应用、导管缺损情况等都会影响预后。但对于何种程度的导管缺损可以直接端端缝合或行自体动静脉移植术尚无定论,以期后续跟进研究。

综上,对腮腺导管损伤患者行腮腺导管端端吻合术时配合应用硬膜外导管具有较好的效果。以硬膜外导管作为支架的腮腺导管吻合术后患侧腮腺分泌功能恢复良好。

**【Author contributions】** Ge LY participated in the data collation and wrote the article. Ji L, Chen L collect the data and search the literature. Li ZP, Gu QP, Meng J and Zhang J designed the study and revised the article. All authors read and approved the final manuscript as submitted.

#### 参考文献

- [1] Hu CY, Shang ZJ, Qin X, et al. Application of delayed surgical managements in patients with Stensen's duct injury[J]. *Curr Med Sci*, 2018, 38(3): 519-523. doi: 10.1007/s11596-018-1909-y.
- [2] McElwee TJ, Poche JN, Sowder JC, et al. Management of acute facial nerve and parotid injuries[J]. *Facial Plast Surg*, 2021, 37(4): 490-499. doi:10.1055/s-0041-1725129.
- [3] Eisbruch A, Rhodus N, Rosenthal D, et al. How should we measure and report radiotherapy-induced xerostomia?[J]. *Semin Radiat Oncol*, 2003, 13(3): 226-234. doi: 10.1016/S1053-4296(03)00033-X.
- [4] Van Sickels JE. Parotid duct injuries[J]. *Oral Surg Oral Med Oral Pathol*, 1981, 52(4): 364-367. doi: 10.1016/0030-4220(81)90330-3.
- [5] 李志进, 郭家平, 董青山, 等. 腮腺及导管开放性损伤的临床分类和治疗[J]. *口腔颌面外科杂志*, 2013, 23(3): 206-208. doi: 10.3969/j.issn.1005-4979.2013.03.011.  
Li ZJ, Guo JP, Dong QS, et al. Classification and treatment of open injuries of parotid gland and stensen's duct[J]. *J Oral Maxil Surg*, 2013, 23(3): 206-208. doi: 10.3969/j.issn.1005-4979.2013.03.011.
- [6] Chowdhury R, Roy D, Roy A. Management of parotid fistula and Frey's syndrome with *Botulinum* neurotoxin type A[J]. *Natl J Maxillofac Surg*, 2021, 12(1): 106-108. doi: 10.4103/njms.NJMS\_72\_20.
- [7] Mohan A, Velu D, Seshadri P, et al. Indigenous management of parotid sialocele using Foley's catheter: a report of two cases[J]. *J Maxillofac Oral Surg*, 2020, 19(2): 225-229. doi: 10.1007/s12663-019-01192-2.
- [8] Louvrier A, Bertin E, Boulahdour Z, et al. Wound of the parotid duct following a subcondylar fracture[J]. *J Oral Maxillofac Surg*, 2022, 80(1): 137.e1-137.e6. doi: 10.1016/j.joms.2021.08.269.
- [9] Hu CY, Shang ZJ, Qin X, et al. Application of delayed surgical managements in patients with Stensen's duct injury[J]. *Curr Med Sci*, 2018, 38(3): 519-523. doi: 10.1007/s11596-018-1909-y.
- [10] Shupak RP, Williams FC, Kim RY. Management of salivary gland injury[J]. *Oral Maxillofac Surg Clin North Am*, 2021, 33(3): 343-350. doi:10.1016/j.coms.2021.04.008.
- [11] Cho DY, Willborg BE, Lu GN. Management of traumatic soft tissue injuries of the face[J]. *Semin Plast Surg*, 2021, 35(4): 229-237. doi:10.1055/s-0041-1735814.
- [12] Mardani M, Arabion H. Surgical management of parotid duct injury using a feeding tube[J]. *Ann Maxillofac Surg*, 2020, 10(2): 472-474. doi:10.4103/ams.ams\_238\_19.
- [13] Medeiros PA, Caetano RDS, Borges AH, et al. Reconstruction of the parotid duct[J]. *Ann Maxillofac Surg*, 2018, 8(1): 140-142. doi: 10.4103/ams.ams\_24\_18.
- [14] Hills AJ, Kannan RY, Williams M. Seldinger technique in repair of the parotid duct[J]. *Br J Oral Maxillofac Surg*, 2019, 57(1): 85-87. doi:10.1016/j.bjoms.2018.07.024.
- [15] Wu CB, Sun HJ, Li FL, et al. Sialendoscopy-assisted treatment of stensen's duct injury: a case series[J]. *J Oral Maxillofac Surg*, 2020, 78(9): 1595.e1-1595.e5. doi: 10.1016/j.joms.2020.04.008.
- [16] Tandon P, Saluja H, Shah S, et al. Catheterization of post infection parotid duct sialocele with paediatric ryles tube: a case report[J]. *J Oral Biol Craniofac Res*, 2018, 8(3): 217-220. doi:10.1016/j.job-cr.2017.09.001.
- [17] Chen YC, Chen HY, Hsu CH. Recent advances in salivary scintigraphic evaluation of salivary gland function[J]. *Diagnostics (Basel)*, 2021, 11(7): 1173. doi: 10.3390/diagnostics11071173.
- [18] Itonaga T, Tokuyue K, Mikami R, et al. Mathematical evaluation of post-radiotherapy salivary gland function using salivary gland scintigraphy[J]. *Br J Radiol*, 2022, 95(1130): 20210718. doi: 10.1259/bjr.20210718.
- [19] Govoni M, Bajocchi G, Rizzo N, et al. Neurological involvement in primary Sjogren's syndrome: clinical and instrumental evaluation in a cohort of Ita patients[J]. *Clin Rheumatol*, 1999, 18(4): 299-303.

(编辑 周春华, 刘曙光)



官网